IMAGING PERFORMED BY

IntraPet.com

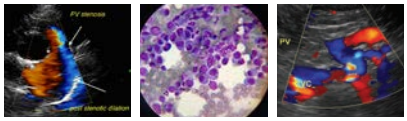

SonoPath
Clinical Sonography & Telecytology
EDUCATIONAL TELECONSULTATION SERVICES™
1-800-838-4268 info@sonopath.com SonoPath.com

DATE

11/4/22

PATIENT

Mouse Lefstein

SPECIES

Feline

BREED

DSH

SEX

Spayed Female

AGE

9/13/14

WEIGHT

7.9 Pounds

INTERPRETED BY

Kathleen Sennello DVM, MS, Diplomate ACVIM (Small Animal Internal Medicine)

IMAGING PERFORMED BY

Stephanie Warga RDCS, RVT

HOSPITAL NAME

Parkville AH

REFERRING VET

Dr. Martin

INVOICE

42537

PRESENTING CLINICAL SIGNS

10/20/22 losing weight, vomiting occasionally eating 1/3 of her normal amount. Happened over a few weeks (was 9.8 lbs in Aug now 7.9 lbs)

Current Medications: cerenia 4 mg PRN.
Lab Results: Cbc/Chem10/Lytes/Sdma/FPL. DM: 10-20-22 at 2:27p: al tests normal except very slight abnormal on the FPL (machine read it out as normal but when I looked at it, sample spot was a little darker than control. Pet ate Hill's canned ID stew readily in cage here.
Date of Previous IntraPet Ultrasound: No previous.
Sedation: Not required to complete full diagnostic ultrasound.
Stat Report: Requested/Approved.

ULTRASONOGRAPHIC EXAMINATION OF THE ABDOMEN

Urinary System

The urinary bladder is mildly to moderately distended with mildly echogenic urine. The apical wall appears slightly thickened, measuring at 0.55 cm. The remainder of the bladder wall appears largely normal, but there is a small area of protruding tissue near the trigone measuring approximately 0.36 cm x 0.31 cm. This could represent a non-distended cystourethral junction or could be a small early mass lesion (polyp, tumor, etc). Recommend a urinalysis and culture and reevaluation of the urinary bladder when it is fully distended.

The left kidney has a normal shape and size (3.37 cm). Overall echogenicity is normal with adequate corticomedullary distinction and a typical 1:3 cortex:medulla ratio. There is no evidence of focal perinephric inflammation or effusion. There is no evidence of pyelectasia, nephroliths, infarcts or hydroureter. Renal vasculature is normal.

The right kidney has a normal shape and size (3.51 cm). Overall echogenicity is normal with adequate corticomedullary distinction and a typical 1:3 cortex:medulla ratio. There is no evidence of focal perinephric inflammation or effusion. There is no evidence of pyelectasia, nephroliths, infarcts or hydroureter. Renal vasculature is normal.

Adrenal Glands

The left adrenal gland is normal in size measuring 0.35 cm at the caudal pole. It is observed in its normal position cranial to the left renal artery. It is normal in appearance (uniformly hypoechoic) and shape with no evidence of a mass effect.

The right adrenal gland is normal in size measuring 0.41 cm at the caudal pole. It is observed in its normal position between the cranial aspect of the right kidney and the caudal vena cava. It is normal in appearance (uniformly hypoechoic) and shape with no evidence of a mass effect.

Spleen

The spleen is subjectively normal in size (0.65 cm in width at the level of the hilus), echotexture is homogenous, and the splenic capsule is smooth with no irregularities. The blood flow through the hilus and splenic parenchyma appears normal. No focal parenchymal abnormalities are visualized.

Liver

The liver is subjectively normal in size, and echogenicity with smooth peripheral margins. The parenchyma is homogenous echotexture. The visible portions of the vasculature and biliary tract appear normal. No focal nodules or cystic lesions are observed.

The gallbladder lumen is moderately distended. The wall of the gall bladder is not thickened and has a smooth mucosal surface. Luminal contents are mild and primarily anechoic. The cystic and common bile ducts are normal/not visible.

Gastrointestinal

The stomach contains minimal luminal contents. It measures at a normal thickness of <0.36cm with some variability due to the presence of rugal folds. The distinction of the gastric wall layers is adequate and there is no impression of reduced peristaltic activity. No masses or focal lesions were observed.

The visualized areas of duodenum, jejunum and ileum have a relatively uniform diameter with minimal fluid distension. Wall thickness is normal. Bowel loops follow a curvilinear path with distinct wall layering maintaining the typical 1:3 muscularis:mucosa layer ratio. Jejunum wall measures 0.16 cm. Visualized peristalsis appears appropriate. There were no focal lesions consistent with obstruction or a mass effect observed.

The ileocecal junction was visualized and exhibited normal intact wall layering and is subjectively of normal thickness. Sections of colon are visualized with formed fecal material and gas shadowing distally. There is no observed focal or generalized colon wall thickening or loss of layering.

Pancreas

The pancreas is large and hypoechoic to surrounding mesentery. There is no evidence of nodules or cystic lesions. There is evidence of regional mesenteric inflammation. Consistent with mild pancreatitis.

Free Abdomen

Evaluation of the peritoneal cavity did not reveal any evidence of effusion. There are prominent mesenteric lymph nodes, particularly at the root of the mesentery and around the ileocecal junction, measuring 0.29, 0.27, 0.28 cm and surrounded by hyperechoic mesentery.

ULTRASONOGRAPHIC FINDINGS

- Mildly to moderately distended urinary bladder with a thick wall at the apex and an irregularity at the cystourethral junction. Recommend reevaluation of the urinary bladder with a distended bladder. If persistent, these could represent true lesions.

- Hypoechoic, prominent pancreas surrounded by hyperechoic mesentery – The pancreatic changes are most consistent with mild pancreatitis/pancreatic inflammation. Recommend fPLI testing and continued monitoring for improvement or possible development of a pancreatic abscess. Consider fine needle aspirate if not improving.

- Prominent mesenteric lymph nodes surrounded by hyperechoic mesentery – The prominent abdominal lymph nodes are most consistent with reactive lymphadenitis or lymphoid hyperplasia. Neoplastic infiltration is considered less likely.

INTERPRETATION OF THE FINDINGS & FURTHER RECOMMENDATIONS

The changes in the urinary bladder are questionable, as there is not significant distention of the urinary bladder to better evaluate these “lesions”. If they are persistent, then consider a urinalysis, culture, and a traumatic catheterization with cytology to look for any atypical cells.

The pancreas appears prominent with some hyperechoic mesentery surrounding. This could be consistent with current pancreatitis or a previous episode of pancreatitis. Correlate with your fPLI level over time and recommend treatment for pancreatitis.

I do not see evidence of significant bowel wall thickening, but there are enlarged, prominent lymph nodes and hyperechoic mesentery around the bowel. If vomiting persists, consider further evaluation.

Consider such differentials as food allergy/dietary intolerance, GI parasitism, chronic pancreatitis, IBD and less likely neoplasia, etc.. .

- Consider a novel protein/hydrolyzed protein diet (exclusively at least 4-6 weeks)
- Consider a GI panel to Texas A&M for evaluation of B12 levels, folate, PLI/TLI etc.. to further evaluate for pancreatic/small intestinal disease.
- Recommend chronic probiotic therapy.
- Recommend three view thoracic radiographs to evaluate for possible concurrent thoracic disease/involvement.
- If symptoms persist, consider obtaining GI biopsies.

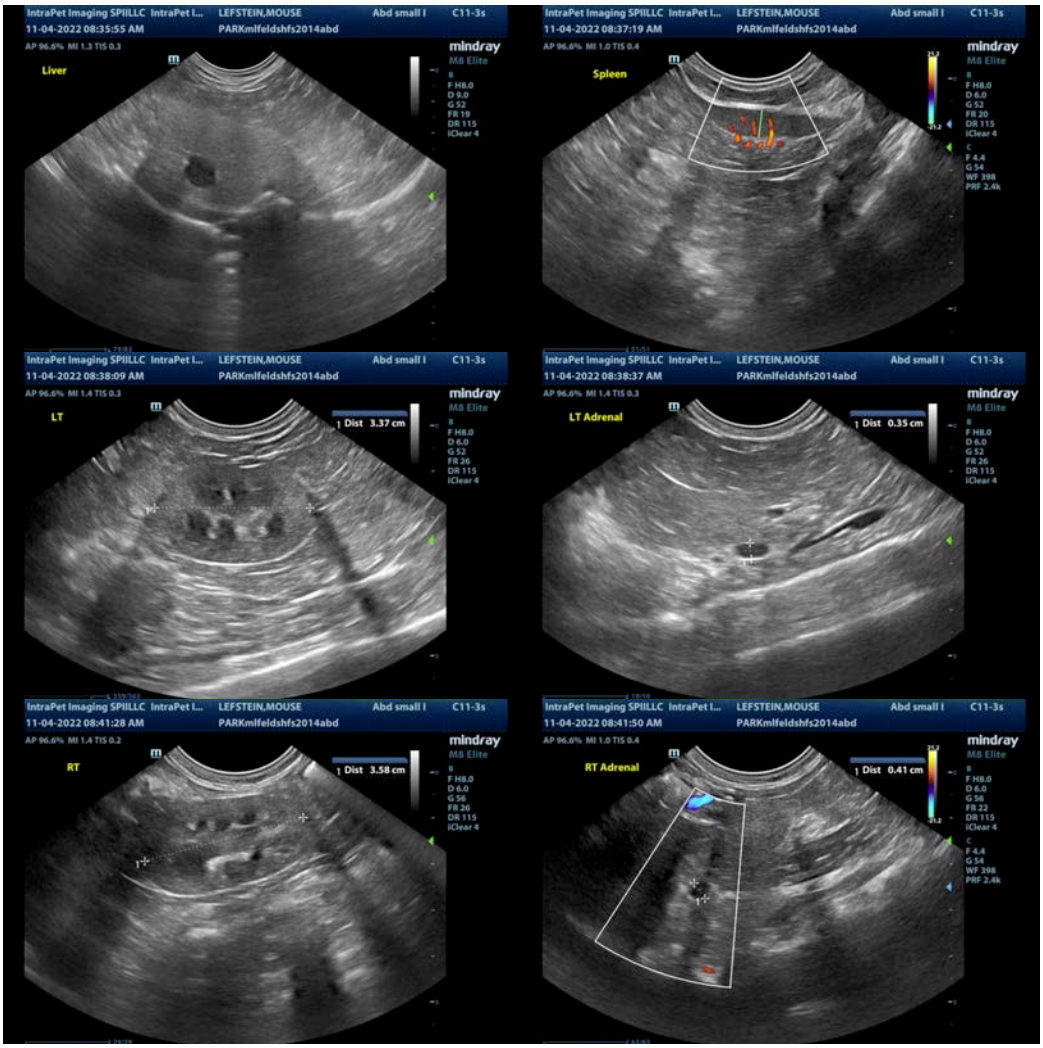

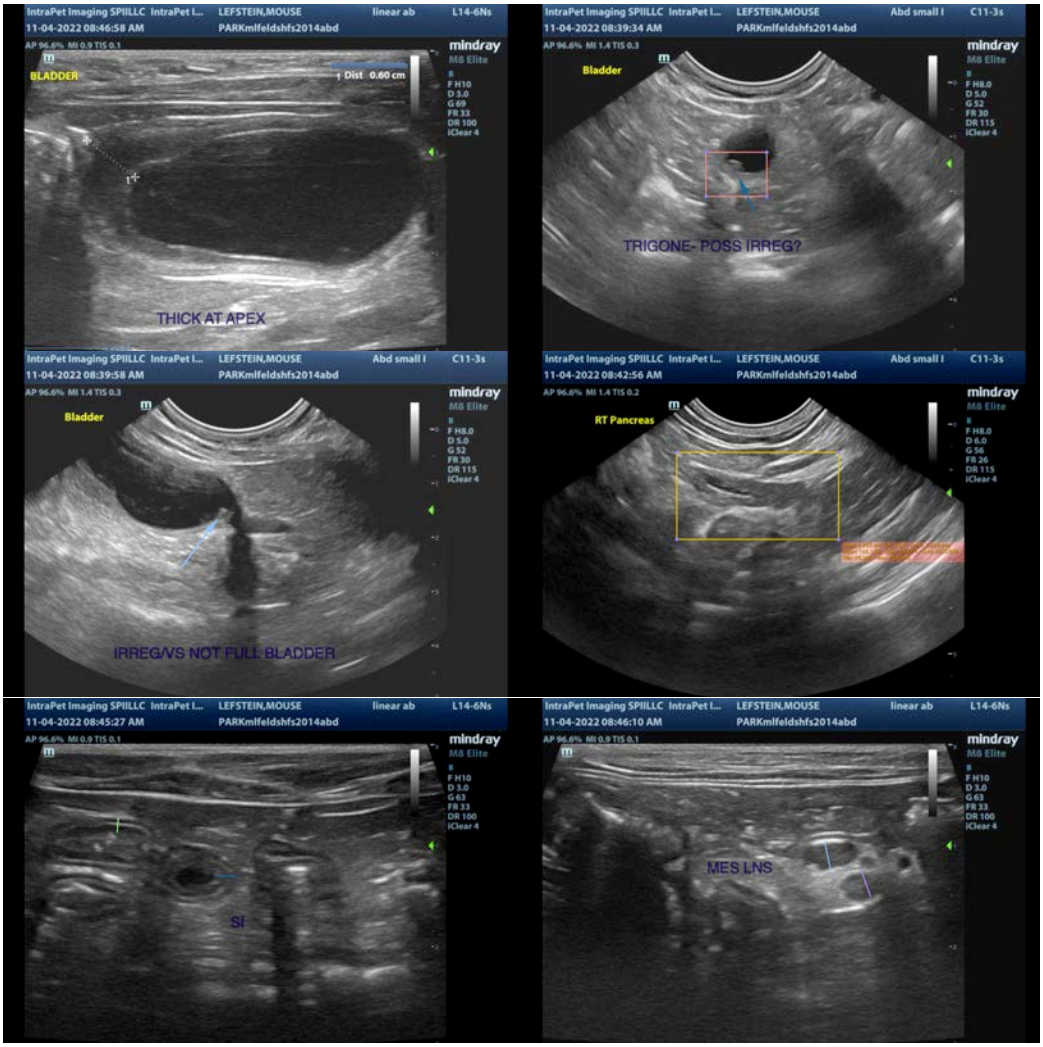

The information and recommendations provided are based on the images presented by the referring veterinarian/sonographer. No evaluation can be communicated regarding pathology that was not visible in the image/video clips provided.

Thank you for this referral. If the clinical or image interpretation does not parallel your findings or if I can be of any further assistance please contact me.

Kathleen Sennello DVM,MS, Diplomate ACVIM (Small animal Internal Medicine)
kathleen.sennello@sonopath.com