

PATIENT

Dudley Cotter

PRESENTING CLINICAL SIGNS

SPECIES

Canine

Drop off for AUS and UA for recheck of Calcium Oxalate Monohydrate calculus that was removed via cystotomy in 1/2022. No recent PU/PD or dysuria. Patient has a new mass that the owner would like to have examined. Good appetite/energy. No C/S/V/D. Patient had an anaphylactic reaction after bee stings in 5/2022. Hx pancreatitis and on i/d low fat. No other historical problems/current medications reported, flea/tick/HW prevention. NPO overnight. Up to date on vaccines per owner.

BREED

Schnauzer

ULTRASONOGRAPHIC EXAMINATION OF THE ABDOMEN

Urinary System

SEX

Neutered Male

The urinary bladder is moderately distended with anechoic urine. The Bladder wall appears mildly diffusely thickened and irregular, measuring 0.30 cm. In the dependent portion of the urinary bladder, there is a pile of small stones/sandy debris. The area of the trigone, ureteral papillae and proximal urethra appear free of any mass lesions or large stones.

AGE

9 Years

The prostate is normal in size (1.0 cm) and shape for this neutered male dog. The parenchyma is homogenous, and the external margins are smooth. The prostatic urethra appears normal with no evidence of irregularity, invasion, or mass effect, but there is a small stone in the prostatic urethra measuring 0.17 cm.

WEIGHT

19 Pounds

The left kidney has a normal shape and size (4.65 cm) with numerous non-obstructive nephroliths, one of which measures 0.35 cm. Overall echogenicity is normal with adequate corticomedullary distinction and a typical 1:3 cortex:medulla ratio. There is no evidence of focal perinephric inflammation or effusion. There is no evidence of pyelectasia, infarcts or hydroureter. Renal vasculature is normal.

INTERPRETED BY

Kathleen Sennello DVM,
MS, Diplomate ACVIM
(Small Animal Internal
Medicine)

The right kidney has a normal shape and size (4.6 cm) with numerous non-obstructive nephroliths. Overall echogenicity is normal with adequate corticomedullary distinction and a typical 1:3 cortex:medulla ratio. There is no evidence of focal perinephric inflammation or effusion. There is no evidence of pyelectasia, infarcts or hydroureter. Renal vasculature is normal.

IMAGING BY

Loetitia Saint-Jacques,
LVT

Adrenal Glands

The left adrenal gland is normal in size measuring 0.55 cm at the caudal pole. It is observed in its normal position cranial to the left renal artery. It is normal in appearance (uniformly hypoechoic) and shape with no evidence of a mass effect.

HOSPITAL NAME

Donner Truckee VH

The right adrenal gland is normal in size measuring 0.59 cm at the caudal pole. It is observed in its normal position between the cranial aspect of the right kidney and the caudal vena cava. It is normal in appearance (uniformly hypoechoic) and shape with no evidence of a mass effect.

REFERRING VET

Dr. Vannini

Spleen

The spleen is normal/borderline large, echotexture is homogenous, and the splenic capsule is smooth with no irregularities. The blood flow through the hilus and splenic parenchyma appears normal. No focal parenchymal abnormalities are visualized.

INVOICE

42557

DATE

11/4/22



PATIENT

Dudley Cotter **Liver**

The liver is large in size, and normal in echogenicity with smooth peripheral margins. The parenchyma is heterogenous in echotexture with subtle, indistinct focal mottling. The visible portions of the vasculature and biliary tract appear normal. No focal nodules or cystic lesions are observed.

SPECIES

Canine

BREED

Schnauzer

The gall bladder lumen is moderately distended. The wall of the gall bladder is not thickened and has a smooth mucosal surface. There is a moderate/large amount of non-organized echogenic debris. The cystic and common bile ducts are normal/not visible.

SEX

Neutered Male

Gastrointestinal

The stomach contains minimal luminal contents. It measures at a normal thickness of <0.7cm with some variability due to the presence of rugal folds. The distinction of the gastric wall layers is adequate and there is no impression of reduced peristaltic activity. No masses or focal lesions were observed.

AGE

9 Years

The visualized areas of duodenum, jejunum and ileum have a relatively uniform diameter with minimal fluid distension. Wall thickness is normal. Bowel loops follow a curvilinear path with distinct wall layering maintaining the typical 1:3 muscularis:mucosa layer ratio. Duodenum wall measures 0.39 cm. Jejunum wall measures 0.35 cm. Visualized peristalsis appears appropriate. There is a small area of bowel observed with mild corrugation, most consistent with a focal area of mild enteritis.

WEIGHT

19 Pounds

The ileocecal junction was visualized and exhibited normal intact wall layering and is subjectively of normal thickness. Sections of colon are visualized with formed fecal material and gas shadowing distally. There is no observed focal or generalized colon wall thickening or loss of layering.

INTERPRETED BY

Kathleen Sennello DVM,
MS, Diplomate ACVIM
(Small Animal Internal
Medicine)

Pancreas

The pancreas is normal and isoechoic to surrounding mesentery. There is no evidence of nodules or cystic lesions. There is no evidence of regional mesenteric inflammation or fluid.

IMAGING BY

Loetitia Saint-Jacques,
LVT

Free Abdomen

There is scant free abdominal fluid. A prominent mesenteric lymph node is visualized measuring 0.50 cm. The omentum is of normal echogenicity.

Other

A brief view of the heart was submitted. No significant pericardial effusion was seen.

HOSPITAL NAME

Donner Truckee VH

ULTRASONOGRAPHIC FINDINGS

- Mildly thickened irregular urinary bladder wall with dependent calculi and sandy debris – Recommend a urinalysis and culture. Correlate findings with abdominal radiographs.

REFERRING VET

Dr. Vannini

- Small calculus within the prostatic urethra – This could be embedded or free. Options include continued monitoring or trying to retropulse back into the bladder with a urethral catheter.

INVOICE

42557

- Non-obstructive nephroliths visualized in both kidneys – The hyperechoic mineralized foci observed at the corticomedullary junction of the left/right kidney are consistent with small, non-obstructive nephroliths.

DATE

11/4/22



PATIENT

Dudley Cotter

SPECIES

Canine

BREED

Schnauzer

SEX

Neutered Male

- Borderline large spleen – The significance of this is currently unclear. Correlate with abdominal radiographs. If the spleen appears significantly enlarged, you could consider a fine needle aspirate.
- Large, heterogeneous liver – The diffuse hepatic changes are non-specific and could be consistent with vacuolar hepatopathy, nodular hyperplasia, inflammatory/immune-mediated disease, fibrosis, extramedullary hematopoiesis, toxic hepatopathy (e.g., copper), infiltrative neoplasia (less likely) or other hepatopathy.
- Moderate gallbladder debris – The significance of the aggregated gallbladder debris is unclear. This could represent an early mucocele, cholestasis, or may be secondary to fasting but seems unlikely to be causing a current issue. Recommend continued monitoring.

INTERPRETATION OF THE FINDINGS & FURTHER RECOMMENDATIONS

AGE

9 Years

There appears to be sandy debris/small stones in the urinary bladder, prostatic urethra, and there are small stones in the kidneys. None of these appear to be causing an active obstruction. Correlate these findings with abdominal radiographs. I suspect some of the pieces of debris are too large to pass through a urinary catheter, but you might be able to retropulse the prostatic urethral stone back into the urinary bladder.

WEIGHT

19 Pounds

The spleen appears ample in size, but the parenchyma appears relatively normal. Correlate with abdominal radiographs. If the spleen appears significantly enlarged, you could consider a fine needle aspirate.

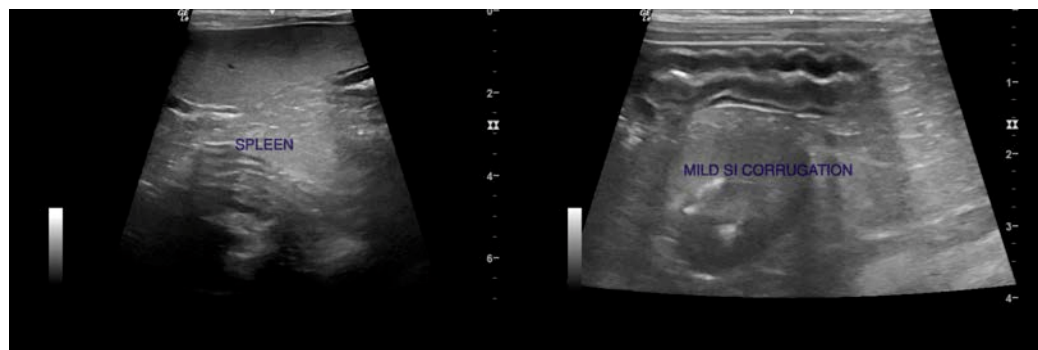
INTERPRETED BY

Kathleen Sennello DVM,
MS, Diplomate ACVIM
(Small Animal Internal
Medicine)

The liver is large and somewhat heterogeneous. Correlate with lab work results. If liver enzymes are elevated, you could consider a liver function test and a fine needle aspirate of the liver.

IMAGING BY

Loetitia Saint-Jacques,
LVT



HOSPITAL NAME

Donner Truckee VH

REFERRING VET

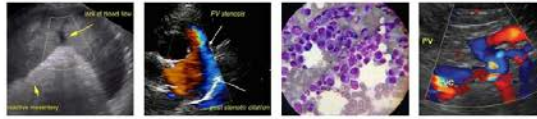
Dr. Vannini

INVOICE

42557

DATE

11/4/22



PATIENT

Dudley Cotter

SPECIES

Canine

BREED

Schnauzer

SEX

Neutered Male

AGE

9 Years

WEIGHT

19 Pounds

INTERPRETED BY

Kathleen Sennello DVM,
MS, Diplomate ACVIM
(Small Animal Internal
Medicine)

IMAGING BY

Loetitia Saint-Jacques,
LVT

HOSPITAL NAME

Donner Truckee VH

REFERRING VET

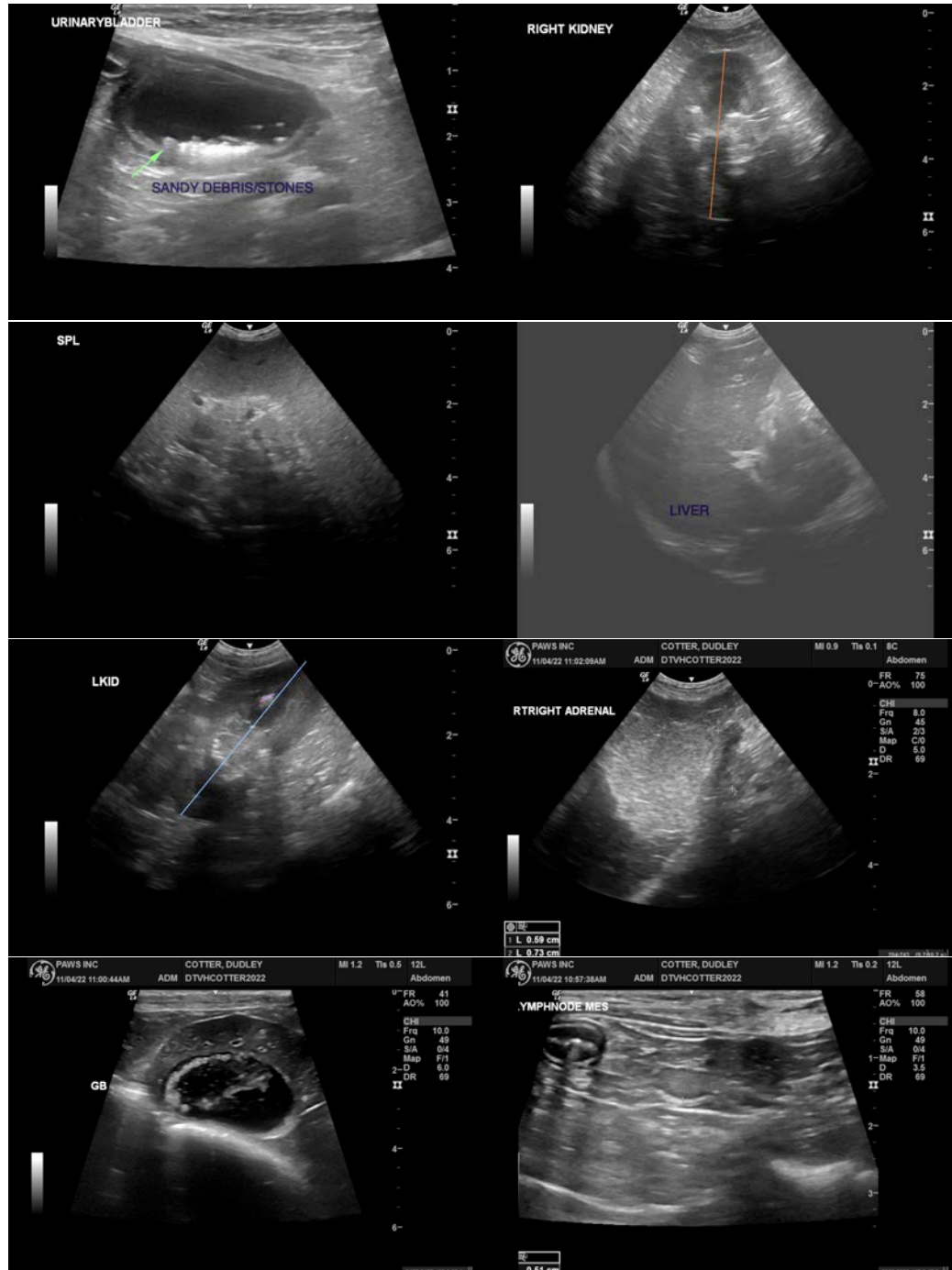
Dr. Vannini

INVOICE

42557

DATE

11/4/22





PATIENT

Dudley Cotter

SPECIES

Canine

BREED

Schnauzer

SEX

Neutered Male

AGE

9 Years

WEIGHT

19 Pounds

INTERPRETED BY

Kathleen Sennello DVM,
MS, Diplomate ACVIM
(Small Animal Internal
Medicine)

IMAGING BY

Loetitia Saint-Jacques,
LVT

HOSPITAL NAME

Donner Truckee VH

REFERRING VET

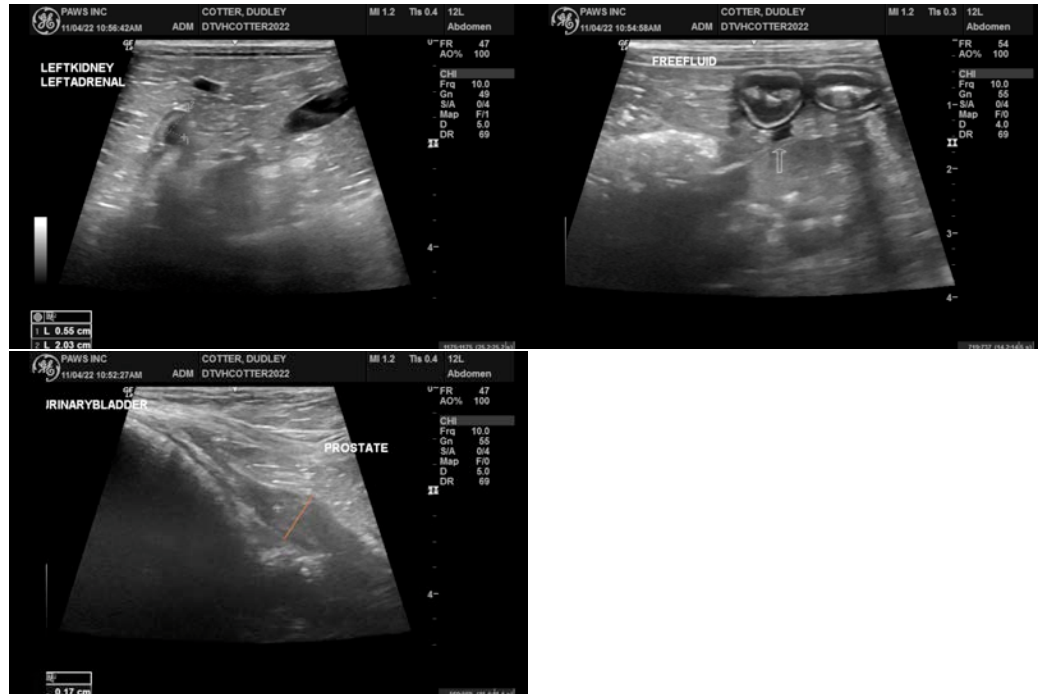
Dr. Vannini

INVOICE

42557

DATE

11/4/22



The information and recommendations provided are based on the images presented by the referring veterinarian/sonographer. No evaluation can be communicated regarding pathology that was not visible in the image/video clips provided.

Thank you for this referral. If the clinical or image interpretation does not parallel your findings or if I can be of any further assistance please contact me.

Kathleen Sennello DVM,MS, Diplomate ACVIM (Small animal Internal Medicine)
kathleen.sennello@sonopath.com