



PATIENT

Danny Harkey

PRESENTING CLINICAL SIGNS

Chief Concern / Provisional Diagnosis: ~ Persistent bacteriuria. Currently asymptomatic but has been symptomatic (hematuria, pollakiuria) in past. Hypoalbuminemia of unknown origin Relevant Medical History and Physical Exam findings: ~ Persistent bacteriuria BPH - resolved following neuter surgery performed on 10/22/20 Back pain Recent Diagnostics: Relevant Laboratory Results / Abnormalities: ~ Performed on 10/14/21 - cbc wnl, chem abnormal include albumin 2.4 (2.7-3.9) Urinalysis results: usg 1.047, pH 6.0, 1+ protein, 2-5 wbc/hpf, Marked rods >40/hpf, urine protein: creatinine ratio not ran due to presence of bacteria Current medications (include full name, dosage and frequency): ~ Cosequin daily Welactin omega 3 fatty acid supplement daily Uses carprofen PRN when painful

SPECIES

Canine

BREED

Corgi

SEX

Neutered Male

AGE

13 Years

WEIGHT

31 Pounds

ULTRASONOGRAPHIC EXAMINATION OF THE ABDOMEN

Urinary System

The urinary bladder is moderately distended with anechoic urine. There is a hyperechoic shadowing ring along the wall of the urinary bladder, most consistent with a gas interface, suspicious for possible emphysematous cystitis. The Bladder wall, trigone, ureteral papillae and visible urethra (to a depth of 2cm) appear relatively normal with no evidence of wall thickening, mucosal irregularities, masses or cystic calculi. The shadowing gas in the bladder impairs visualization of some of these structures. Recommendation correlation with abdominal radiographs, urinalysis and culture results.

The prostate appears borderline enlarged at 1.39 cm. It is slightly irregular in shape and mottled for this neutered male dog. The parenchyma is heterogeneous, but has relatively smooth margins. The prostatic urethra appears normal with no evidence of irregularity, invasion, mass effect, or calculi. I suspect the findings are consistent with an involuted prostate post prostatic disease with scarring, some cystic areas, etc., although persistent infection or neoplastic change cannot be excluded as a possibility.

The left kidney is normal in size (6.08 cm) and irregular in shape. Overall echogenicity is slightly hyperechoic with poor corticomedullary distinction and a typical 1:3 cortex:medulla ratio. There is no evidence of perinephric inflammation or effusion. There is no evidence of pyelectasia, nephroliths, infarcts or hydroureter. Renal vasculature is normal.

The right kidney is normal in size (7.51 cm) and irregular in shape. Overall echogenicity is slightly hyperechoic with poor corticomedullary distinction and a typical 1:3 cortex:medulla ratio. There is no evidence of perinephric inflammation or effusion. There is no evidence of pyelectasia, nephroliths, infarcts or hydroureter. Renal vasculature is normal.

INTERPRETED BY

Kathleen Sennello DVM,
MS, Diplomate ACVIM
(Small Animal Internal
Medicine)

IMAGING PERFORMED BY

Loetitia Saint-Jacques, RVT

HOSPITAL NAME

MountainView AH

REFERRING VET

Dr. Grace Dahlgren

Adrenal Glands

The left adrenal gland is normal in size measuring 0.62 cm at the caudal pole. It is observed in its normal position cranial to the left renal artery. It is normal in appearance (uniformly hypoechoic) and shape with no evidence of a mass effect.

The right adrenal gland is normal in size measuring 0.75 cm at the caudal pole. It is observed in its normal position between the cranial aspect of the right kidney and the caudal vena cava. It is normal in appearance (uniformly hypoechoic) and shape with no evidence of a mass effect.

INVOICE

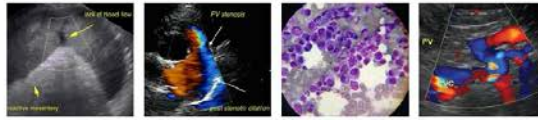
26882

DATE

11/4/21

Spleen

The spleen is subjectively normal in size, echotexture is mildly heterogeneous and mottled. The splenic capsule is largely smooth, but there is an isoechoic bulge in the capsule visualized mid spleen, creating a mass effect, but there is no change in echogenicity, so the significance of this is uncertain. This lesion measures 1.8 cm x 2.58 cm. Additionally, there is a small, hypoechoic nodule visualized at 0.56 cm, and a



PATIENT

Danny Harkey hyperechoic nodule at 0.31 cm. The blood flow through the hilus and splenic parenchyma appears normal. No focal parenchymal abnormalities are visualized.

SPECIES *Liver*

Canine The liver is subjectively normal in size, and echogenicity with smooth peripheral margins. The parenchyma is heterogenous in echotexture with subtle, indistinct focal mottling. The visible portions of the vasculature and biliary tract appear normal. No focal nodules or cystic lesions are observed.

BREED

Corgi The gallbladder lumen is moderately distended. The wall of the gall bladder is not thickened and has a smooth mucosal surface. Luminal contents are primarily anechoic. The cystic and common bile ducts are normal/not visible.

SEX *Gastrointestinal*

Neutered Male The stomach contains minimal luminal contents. It measures at a normal thickness of <0.7cm with some variability due to the presence of rugal folds. The distinction of the gastric wall layers is adequate and there is no impression of reduced peristaltic activity. No masses or focal lesions were observed.

AGE

13 Years The visualized areas of duodenum, jejunum and ileum have a relatively uniform diameter with minimal fluid distension. Wall thickness is normal. Bowel loops follow a curvilinear path with distinct wall layering maintaining the typical 1:3 muscularis:mucosa layer ratio. Jejunum wall measured 0.37 cm. Visualized peristalsis appears appropriate. There were no focal lesions consistent with obstruction or a mass effect observed.

WEIGHT

31 Pounds The ileocecal junction was visualized and exhibited normal intact wall layering and is subjectively of normal thickness. Sections of colon are visualized with formed fecal material and gas shadowing distally. There is no observed focal or generalized colon wall thickening or loss of layering.

INTERPRETED BY

Kathleen Sennello DVM,
MS, Diplomate ACVIM
(Small Animal Internal
Medicine)

Pancreas

The pancreas is normal and isoechoic to surrounding mesentery. There is no evidence of nodules or cystic lesions. There is no evidence of regional mesenteric inflammation or fluid.

IMAGING PERFORMED BY

Loetitia Saint-Jacques, RVT

Free Abdomen

Evaluation of the peritoneal cavity did not reveal any evidence of effusion, or subjective lymphadenomegaly. The Medial iliac nodes appear normal and there was no evidence of a caudal aortic thrombus at the bifurcation. The omentum is of normal uniform echogenicity.

HOSPITAL NAME

MountainView AH

Other

A brief view of the heart was submitted. No significant pericardial effusion was seen. Ring down artifact is visualized at the level of the diaphragm. This can indicate pulmonary parenchymal disease. Recommend 3-view thoracic radiographs.

REFERRING VET

Dr. Grace Dahlgren

PRIMARY FINDINGS

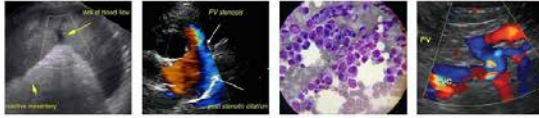
INVOICE

26882

- Suspect emphysematous cystitis - Hyperechoic shadowing areas around the margins of the bladder are concerning for intraluminal air secondary to gas producing bacteria. Correlate these findings with radiographs, as artifact can sometimes resemble this appearance.
- Decreased corticomedullary distinction in both kidneys with significant irregularity – Mild loss of corticomedullary distinction in both kidneys could be consistent with chronic degenerative disease or interstitial nephrosis.

DATE

11/4/21



PATIENT

Danny Harkey

SPECIES

Canine

BREED

Corgi

SEX

Neutered Male

- Isoechoic splenic bulge with unknown significance and two small nodules (one hyperechoic and one hypoechoic) – The diffuse splenic changes are non-specific and could be consistent with lymphoid hyperplasia, extramedullary hematopoiesis, infiltrative neoplasia, inflammation, other. Cytology or histopathology would be necessary to get a definitive diagnosis. The isoechoic appearance of the bulging area has the appearance of a benign lesion, but histopathology would be necessary to confirm.
- Heterogeneous liver – The diffuse hepatic changes are non-specific and could be consistent with vacuolar hepatopathy, nodular hyperplasia, inflammatory/immune-mediated disease, fibrosis, extramedullary hematopoiesis, toxic hepatopathy (e.g., copper), infiltrative neoplasia (less likely) or other hepatopathy.
- Mottled prostate – The significance of this is unclear. It could be consistent with previous prostatic disease or with current prostatic disease.

INTERPRETATION OF THE FINDINGS & FURTHER RECOMMENDATIONS

AGE

13 Years

I am concerned based on the appearance of the urinary bladder that there may be gas within the lumen. Recommend abdominal radiographs to confirm this, as other artifacts can have a similar appearance. Recommend urinalysis and culture. Also recommend evaluation of the lumbar vertebrae on your radiographs to look for evidence of discospondylitis if there is back pain present.

WEIGHT

31 Pounds

Despite neutering, there is a small chance that the prostate serves as a nidus for infection as recurrent infections are still an issue. I did not see any obvious abscesses or cysts associated with the prostate, but it can be difficult to visualize with the gas in the bladder and its intrapelvic location.

INTERPRETED BY

Kathleen Sennello DVM,
MS, Diplomate ACVIM
(Small Animal Internal
Medicine)

The splenic lesions are likely incidental at this time, but could develop into something more concerning. Recommend either fine needle aspirates of these areas or close monitoring with ultrasound. Recommend 3-view thoracic radiographs.

IMAGING PERFORMED BY

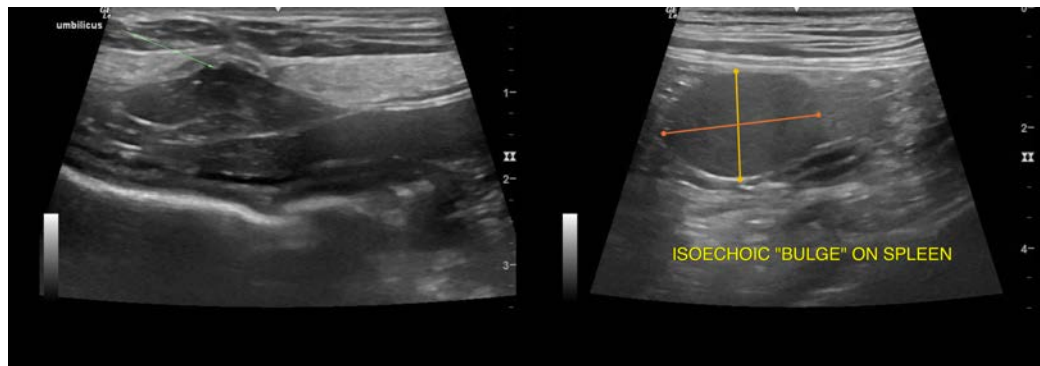
Loetitia Saint-Jacques, RVT

HOSPITAL NAME

MountainView AH

REFERRING VET

Dr. Grace Dahlgren



INVOICE

26882

DATE

11/4/21



PATIENT

Danny Harkey

SPECIES

Canine

BREED

Corgi

SEX

Neutered Male

AGE

13 Years

WEIGHT

31 Pounds

INTERPRETED BY

Kathleen Sennello DVM,
MS, Diplomate ACVIM
(Small Animal Internal
Medicine)

IMAGING PERFORMED BY

Loetitia Saint-Jacques, RVT

HOSPITAL NAME

MountainView AH

REFERRING VET

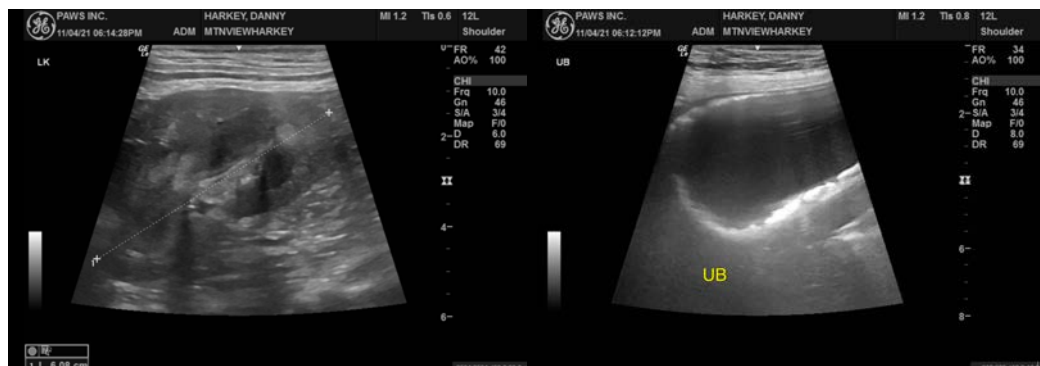
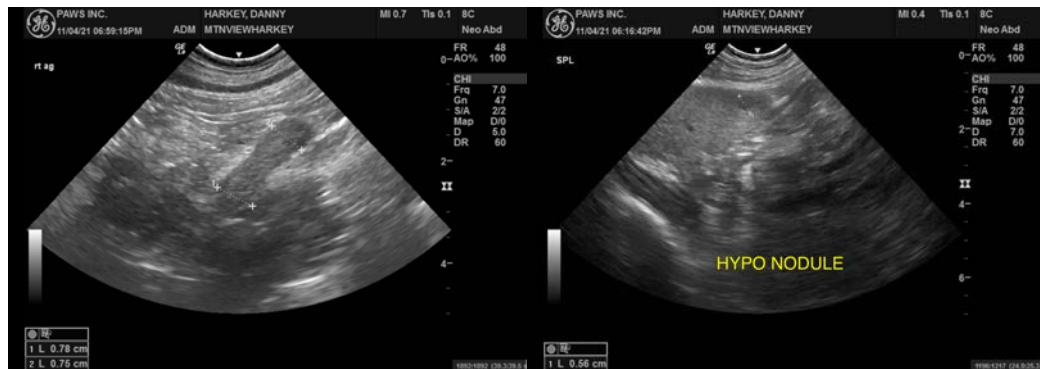
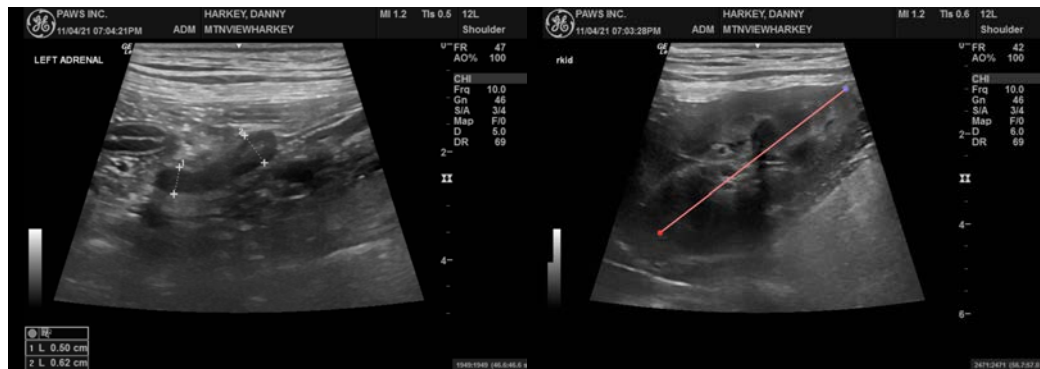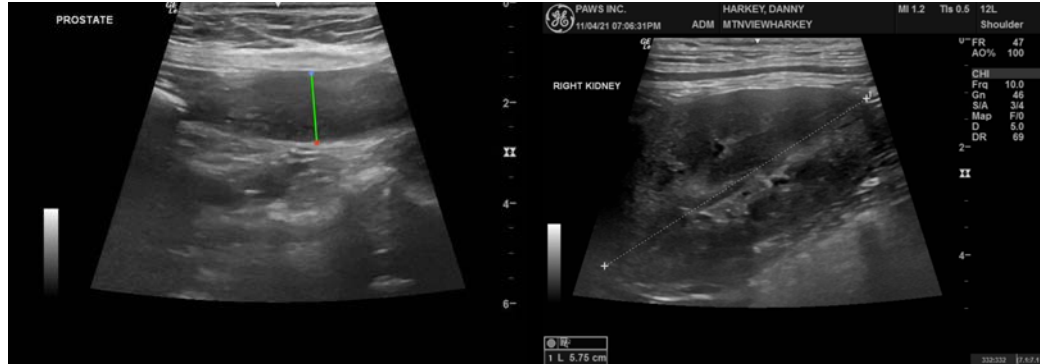
Dr. Grace Dahlgren

INVOICE

26882

DATE

11/4/21





PATIENT

Danny Harkey

The information and recommendations provided are based on the images presented by the referring veterinarian. No evaluation can be communicated regarding pathology that was not visible in the image/video clips provided.

SPECIES

Canine

Thank you for this referral. If the clinical or image interpretation does not parallel your findings or if I can be of any further assistance please contact me.

BREED

Corgi

Kathleen Sennello DVM,MS, Diplomate ACVIM (Small animal Internal Medicine)

kathleen.sennello@sonopath.com

SEX

Neutered Male

AGE

13 Years

WEIGHT

31 Pounds

INTERPRETED BY

Kathleen Sennello DVM,
MS, Diplomate ACVIM
(Small Animal Internal
Medicine)

**IMAGING PERFORMED
BY**

Loetitia Saint-Jacques, RVT

HOSPITAL NAME

MountainView AH

REFERRING VET

Dr. Grace Dahlgren

INVOICE

26882

DATE

11/4/21