

IMAGING PERFORMED BY

IntraPet.com



SonoPath

Clinical Sonography & Telecytology

EDUCATIONAL TELECONSULTATION SERVICES™

1-800-838-4268 info@sonopath.com SonoPath.com

DATE PRESENTING CLINICAL SIGNS

11/30/22 Follow up from last year's ultrasound. PE: feels like abdominal mass effect in cranial abdomen has increased compared to last year.

PATIENT

Mint Julep Walker
Current Medications: Denamarin ? Need to check with owner
Date of Previous IntraPet Ultrasound: 10/27/2021. See attached.
Sedation: Declined.
Stat Report: Not requested.

SPECIES

Feline

ULTRASONOGRAPHIC EXAMINATION OF THE ABDOMEN

BREED

Maine Coon X

Urinary System

The urinary bladder is moderately distended with anechoic urine. The Bladder wall, trigone, ureteral papillae and visible urethra (to a depth of 2cm) appear normal with no evidence of wall thickening, mucosal irregularities, masses or cystic calculi.

SEX

Spayed Female

The left kidney has a normal shape and size (3.07 cm). Overall echogenicity is slightly hyperechoic with mildly reduced corticomedullary distinction and a typical 1:3 cortex:medulla ratio. There is no evidence of focal perinephric inflammation or effusion. There is no evidence of pyelectasia, nephroliths, infarcts or hydroureter. Renal vasculature is normal.

AGE

4/26/12

The right kidney has a normal shape and size (3.22 cm). Overall echogenicity is slightly hyperechoic with poor corticomedullary distinction and a typical 1:3 cortex:medulla ratio. There is no evidence of focal perinephric inflammation or effusion. There is no evidence of pyelectasia, nephroliths, infarcts or hydroureter. Renal vasculature is normal.

WEIGHT

12 Pounds

INTERPRETED BY

Kathleen Sennello DVM,
MS, Diplomate ACVIM
(Small Animal Internal
Medicine)

Adrenal Glands

The region of left adrenal (Cranial to left renal artery) is unremarkable but the adrenal is not distinctly visualized. No evidence of a mass effect.

The region of the right adrenal (between right cranial kidney and vena cava) is unremarkable, but the adrenal is not distinctly visualized. No evidence of a mass effect.

IMAGING PERFORMED BY

Andi Parkinson RDMS

Spleen

The spleen is subjectively normal in size (0.7 cm in width at the level of the hilus), echotexture is homogenous, and the splenic capsule is smooth with no irregularities. The blood flow through the hilus and splenic parenchyma appears normal. No focal parenchymal abnormalities are visualized.

HOSPITAL NAME

Harborside Mobile VC

Liver

The liver is large and irregular. The parenchyma is heterogenous in echotexture with subtle, indistinct focal mottling. The visible portions of the vasculature and biliary tract appear normal. There are numerous large mixed echogenic cystic masses visualized throughout the liver. The largest cystic area is visualized on the right side measuring 3.5 cm x 4.4 cm. There is a hyperechoic nodule in the parenchyma measuring 1.69 cm. There is a very large, pedunculated, hyperechoic mass effect with a slightly cystic center measuring 5.95 cm x 6.87 cm. All of these lesions appear to have progressed since the last scan on 10/27/21.

REFERRING VET

Dr. Hawkins

INVOICE

43058

The gallbladder lumen is moderately distended. The wall of the gall bladder is not thickened and has a smooth mucosal surface. Luminal contents are mild and primarily anechoic. The cystic and common bile ducts are normal/not visible.

Gastrointestinal

The stomach is moderately dilated with fluid and irregular shadowing material most consistent with normal ingesta and gas. It measures at a normal thickness of <0.36cm with some variability due to the presence of rugal folds. The distinction of the gastric wall layering is adequate and there is no impression of reduced peristaltic activity. No masses or focal lesions were observed.

The visualized areas of duodenum, jejunum and ileum have a relatively uniform diameter with mild to moderate fluid distension. Wall thickness is normal. Bowel loops follow a curvilinear path with distinct wall layering maintaining the typical 1:3 muscularis:mucosa layer ratio. The duodenum measured as normal (between 0.13-0.38cm in wall thickness) and the jejunum measured as normal (between 0.15-0.36cm.) Visualized peristalsis appears appropriate. There were no focal lesions consistent with obstruction or a mass effect observed.

The ileocecal junction was visualized and exhibited normal intact wall layering and is subjectively of normal thickness. Sections of colon are visualized with formed fecal material and gas shadowing distally. There is no observed focal or generalized colon wall thickening or loss of layering.

Pancreas

The pancreas is normal and isoechoic to surrounding mesentery. There is no evidence of nodules or cystic lesions. There is no evidence of regional mesenteric inflammation or fluid.

Free Abdomen

There is scant free abdominal fluid. There are visible mesenteric lymph nodes, one such caudal lymph node measures 0.43 cm. The omentum is generally of normal echogenicity.

PRIMARY FINDINGS

- Multiple large mixed echogenic cystic masses with a large pedunculated hyperechoic caudal cystic mass – These lesions are most consistent with benign cystadenomas, but they appear to be progressing.
- Scant free abdominal fluid

SECONDARY FINDINGS

- Mildly decreased corticomedullary distinction in both kidneys – The bilateral renal findings are consistent with age-related change.
- Moderate gastric ingesta and ingesta visualized within the small bowel – Findings are most consistent with a non-fasted patient. If the patient was fasted, consider the possibility of delayed gastric emptying/ileus.
- Occasional prominent mesenteric lymph nodes – The prominent abdominal lymph nodes are most consistent with reactive lymphadenitis or lymphoid hyperplasia. Neoplastic infiltration is considered less likely.

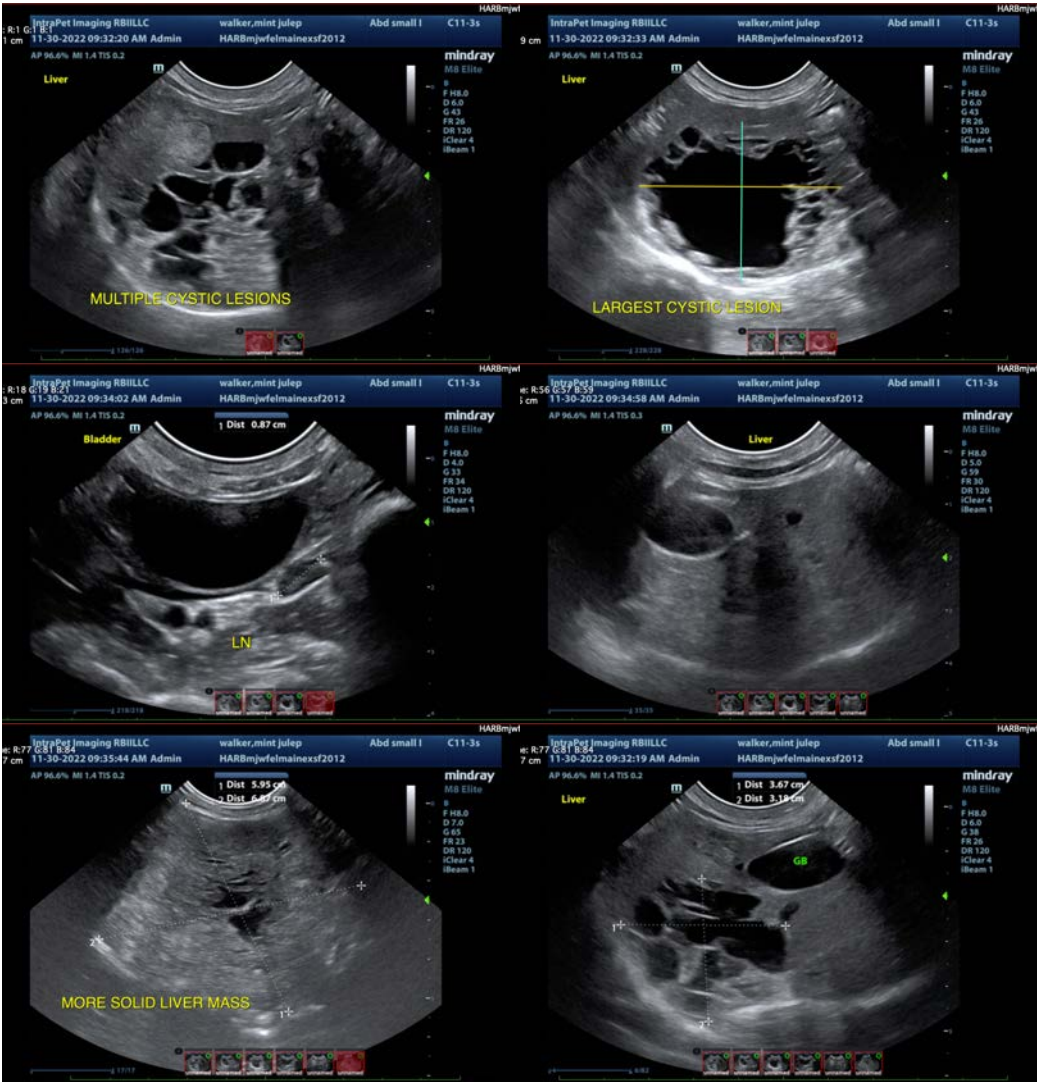
INTERPRETATION OF THE FINDINGS & FURTHER RECOMMENDATIONS

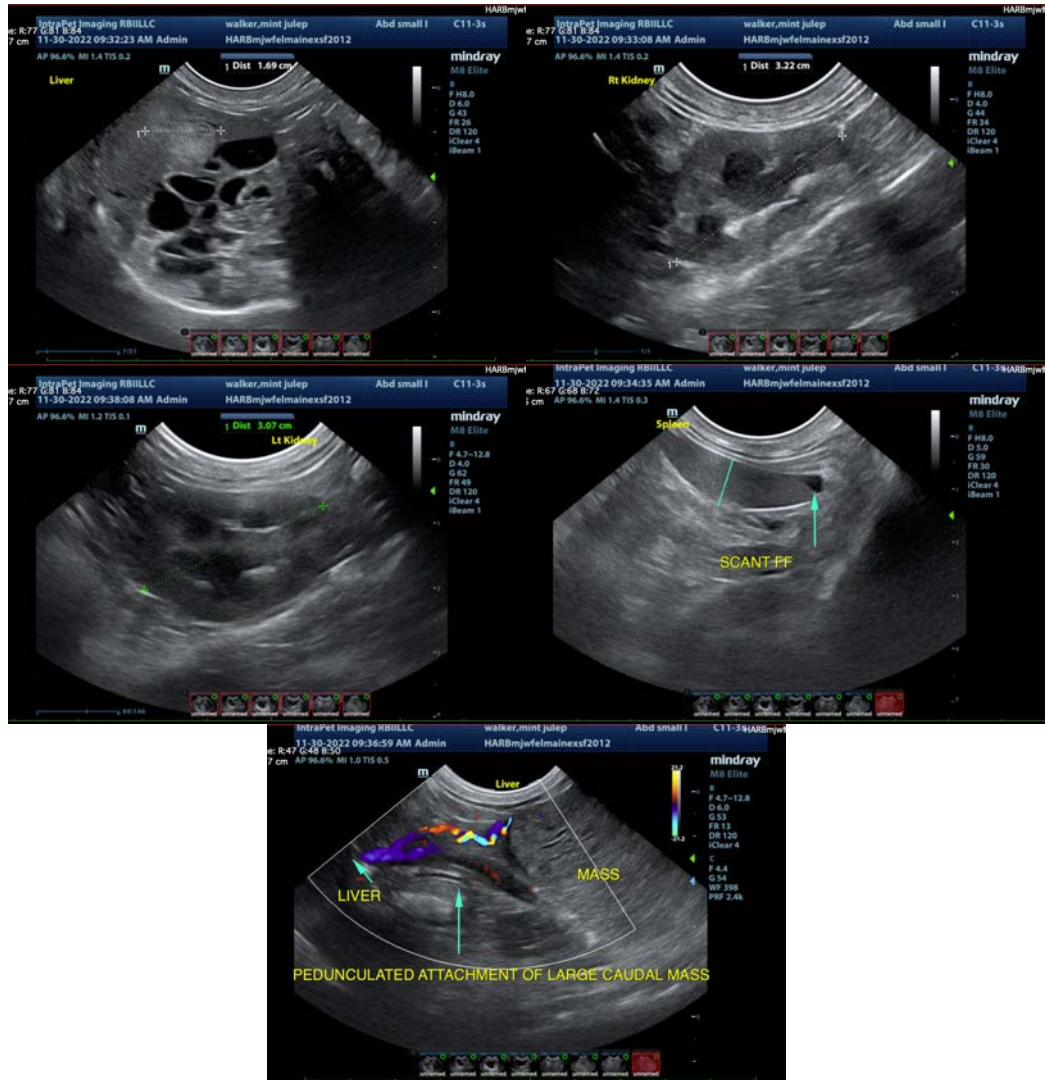
The cyst lesions and hyperechoic more solid lesions appear to be progressing. I still suspect these are progressive benign cystadenomas. There is likely ample normal liver tissue for normal liver function, but these become an issue with the size and space-occupying nature of the mass lesions. I suspect surgical options are pretty limited. There is a large caudal pedunculated mass effect, which could likely be removed if this is thought to be causing discomfort, etc. If surgical intervention is desired, I would strongly recommend a

contrast CT scan to get a more global view of the liver, and try to determine if a select liver lobe or mass effect could be removed, which could potentially improve quality of life. Over time, all of these lesions will progress, but if there is a focal area that is a problem, there is a possibility of surgical intervention for palliative therapy.

Recommend three view thoracic radiographs to evaluate for possible concurrent thoracic disease/involvement.

The changes in the kidneys are relatively mild and most consistent with age related change. Correlate with bloodwork, urinalysis, and possibly a blood pressure evaluation.





The information and recommendations provided are based on the images presented by the referring veterinarian/sonographer. No evaluation can be communicated regarding pathology that was not visible in the image/video clips provided.

Thank you for this referral. If the clinical or image interpretation does not parallel your findings or if I can be of any further assistance please contact me.

Kathleen Sennello DVM,MS, Diplomate ACVIM (Small animal Internal Medicine)
 kathleen.sennello@sonopath.com