



PATIENT

Maui Prager

SPECIES

Canine

BREED

Lab X

SEX

Neutered Male

AGE

12 Years

WEIGHT

63.4 Pounds

INTERPRETED BY

Kathleen Sennello DVM,
MS, Diplomate ACVIM
(Small Animal Internal
Medicine)

**IMAGING
PERFORMED BY**

Jessica Miller

HOSPITAL NAME

Millburn Vet Hospital

REFERRING VET

Dr. Turowsky

INVOICE

43053

DATE

11/30/22

PRESENTING CLINICAL SIGNS

Progressive liver enzyme elevation. Current meds: Denamarin, Dasuquin, Galliprant, Gabapentin
Abnormal PE/Chem/CBC/UA Results: ALT 446, AST 68

ULTRASONOGRAPHIC EXAMINATION OF THE ABDOMEN

Urinary System

The urinary bladder is moderately distended with anechoic urine. The Bladder wall, trigone, ureteral papillae and visible urethra (to a depth of 2cm) appear normal with no evidence of wall thickening, mucosal irregularities, masses or cystic calculi.

The prostate is normal in size (1.1 cm) and shape for this neutered male dog. The parenchyma is homogenous and the external margins are smooth. The prostatic urethra appears normal with no evidence of irregularity, invasion, mass effect or calculi.

The left kidney has a normal shape and size (6.92 cm). Overall echogenicity is normal with adequate corticomedullary distinction and a typical 1:3 cortex:medulla ratio. There is no evidence of focal perinephric inflammation or effusion. There is no evidence of pyelectasia, nephroliths, infarcts or hydroureter. Renal vasculature is normal.

The right kidney has a normal shape and size (5.66 cm). Overall echogenicity is normal with adequate corticomedullary distinction and a typical 1:3 cortex:medulla ratio. There is no evidence of focal perinephric inflammation or effusion. There is no evidence of pyelectasia, nephroliths, infarcts or hydroureter. Renal vasculature is normal.

Adrenal Glands

The left adrenal gland is normal in size measuring 0.61 cm at the caudal pole. It is observed in its normal position cranial to the left renal artery. It is normal in appearance (uniformly hypoechoic) and shape with no evidence of a mass effect.

The right adrenal gland is normal in size measuring 0.75 cm at the caudal pole. It is observed in its normal position between the cranial aspect of the right kidney and the caudal vena cava. It is normal in appearance (uniformly hypoechoic) and shape with no evidence of a mass effect.

Spleen

The spleen is subjectively normal in size and the echotexture is homogenous. The splenic capsule is smooth with no visible irregularities. Rare discrete focal hyperechoic, perivascular parenchymal abnormalities are present. The appearance of these lesions is most consistent with benign splenic myelolipomas. The blood flow through the hilus and splenic parenchyma appears normal.

Liver

The liver is subjectively normal in size, and echogenicity with smooth peripheral margins. The parenchyma is homogenous echotexture. The visible portions of the vasculature and biliary tract appear normal. No focal nodules or cystic lesions are observed.

The gall bladder lumen is moderately distended. The wall of the gall bladder is not thickened and has a smooth mucosal surface. There is a mild amount of non-organized echogenic debris. The cystic and common bile ducts are normal/not visible.

Gastrointestinal



PATIENT

Maui Prager

The stomach contains a moderate amount of fluid. It measures at a normal thickness of <0.7cm with some variability due to the presence of rugal folds. The distinction of the gastric wall layers is adequate and there is no impression of reduced peristaltic activity. No masses or focal lesions were observed.

SPECIES

Canine

The visualized areas of duodenum, jejunum and ileum have a relatively uniform diameter with minimal fluid distension. Wall thickness is normal. Bowel loops follow a curvilinear path with distinct wall layering maintaining the typical 1:3 muscularis:mucosa layer ratio. Jejunum wall measures 0.29 cm. Visualized peristalsis appears appropriate. There were no focal lesions consistent with obstruction or a mass effect observed.

BREED

Lab X

The ileocecal junction was visualized and exhibited normal intact wall layering and is subjectively of normal thickness. Sections of colon are visualized with formed fecal material and gas shadowing distally. There is no observed focal or generalized colon wall thickening or loss of layering.

SEX

Neutered Male

Pancreas

The pancreas is normal and isoechoic to surrounding mesentery. There is no evidence of nodules or cystic lesions. There is no evidence of regional mesenteric inflammation or fluid.

AGE

12 Years

Free Abdomen

Evaluation of the peritoneal cavity did not reveal any evidence of effusion, or subjective lymphadenomegaly. The Medial iliac nodes appear normal and there was no evidence of a caudal aortic thrombus at the bifurcation. The omentum is of normal uniform echogenicity.

WEIGHT

63.4 Pounds

Other

A brief view of the heart was submitted. No significant pericardial effusion was seen.

INTERPRETED BY

Kathleen Sennello DVM,
MS, Diplomate ACVIM
(Small Animal Internal
Medicine)

ULTRASONOGRAPHIC FINDINGS

- Hyperechoic foci visualized on the periphery of the spleen – These are most consistent with benign myelolipomas
- Mild gallbladder debris – The significance of the aggregated gallbladder debris is unclear. This could represent an early mucocele, cholestasis, or may be secondary to fasting but seems unlikely to be causing a current issue. Recommend continued monitoring.

IMAGING PERFORMED BY

Jessica Miller

INTERPRETATION OF THE FINDINGS & FURTHER RECOMMENDATIONS

No focal lesions or significant abnormalities were visualized associated with the liver or the biliary tract. Unfortunately, there are many causes for an elevation in ALT, which cannot be diagnosed by ultrasound alone.

HOSPITAL NAME

Millburn Vet Hospital

- Consider close evaluation of history for possible toxic changes examine medications, diet, dietary indiscretion etc...

REFERRING VET

Dr. Turowsky

- Consider PCR on urine/serum for leptospirosis (if not on antibiotics)/serology if recent antibiotic history

INVOICE

43053

- If not already done, consider pre and post prandial bile acids to evaluate liver function
- Consider Fine needle aspirate if round cell neoplasia is on your differentia list (25 g needle, normal coags)

DATE

11/30/22



PATIENT

Maui Prager

- If no response to supportive care (Denamarin, fluids, antibiotics, +/- ursodiol etc.) Consider liver biopsy with samples obtained for histopathology, culture, and copper levels.

SPECIES

Canine

If a cytologic diagnosis cannot be obtained and the ALT is persistently elevated/continuing to rise I would strongly consider biopsies (as recommended above) as some types of smoldering liver disease can progress to more significant liver dysfunction over time-with relatively mild liver enzyme elevations.

BREED

Lab X

SEX

Neutered Male

AGE

12 Years

WEIGHT

63.4 Pounds

INTERPRETED BY

Kathleen Sennello DVM,
MS, Diplomate ACVIM
(Small Animal Internal
Medicine)

**IMAGING
PERFORMED BY**

Jessica Miller

HOSPITAL NAME

Millburn Vet Hospital

REFERRING VET

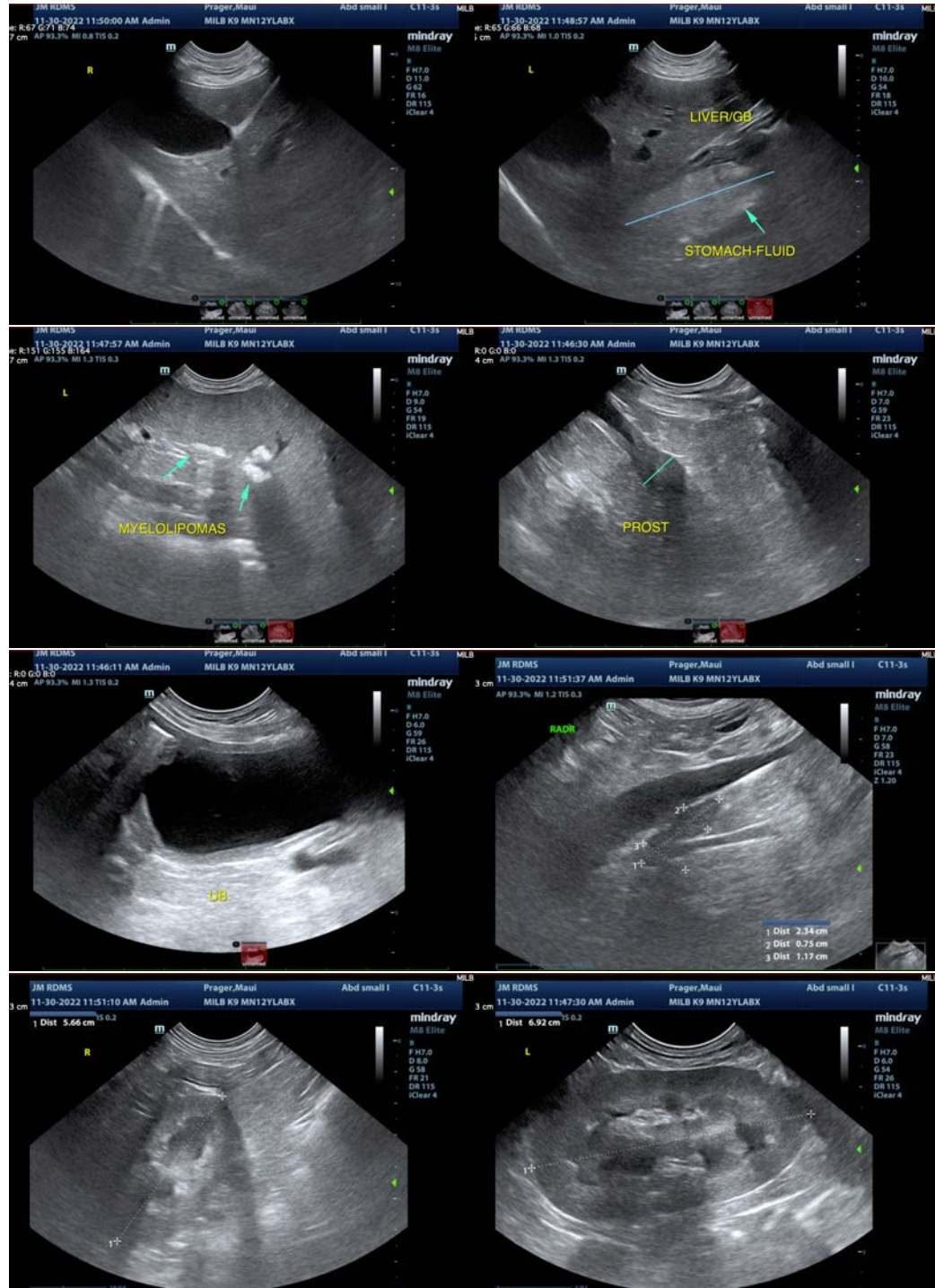
Dr. Turowsky

INVOICE

43053

DATE

11/30/22





PATIENT

Maui Prager

SPECIES

Canine

BREED

Lab X

SEX

Neutered Male

AGE

12 Years

WEIGHT

63.4 Pounds

INTERPRETED BY

Kathleen Sennello DVM,
MS, Diplomate ACVIM
(Small Animal Internal
Medicine)

**IMAGING
PERFORMED BY**

Jessica Miller

HOSPITAL NAME

Millburn Vet Hospital

REFERRING VET

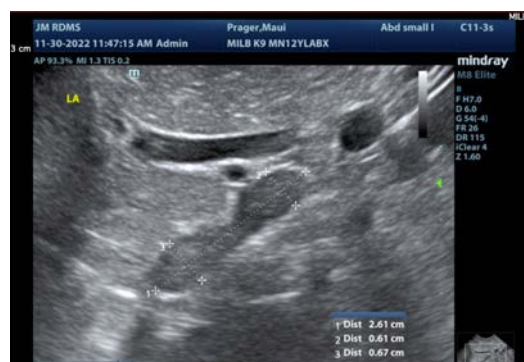Dr. Turowsky

INVOICE

43053

DATE

11/30/22



The information and recommendations provided are based on the images presented by the referring veterinarian/sonographer. No evaluation can be communicated regarding pathology that was not visible in the image/video clips provided.

Thank you for this referral. If the clinical or image interpretation does not parallel your findings or if I can be of any further assistance please contact me.

Kathleen Sennello DVM,MS, Diplomate ACVIM (Small animal Internal Medicine)

kathleen.sennello@sonopath.com