SonoPath
Clinical Sonography & Telecytology
EDUCATIONAL TELECONSULTATION SERVICES™
1-800-838-4268 info@sonopath.com SonoPath.com

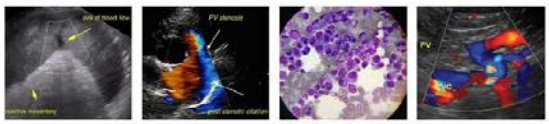

IMAGING PERFORMED BY
pawsonography@gmail.com 530-786-8340

PATIENT

Guinness Siwak

SPECIES

Canine

BREED

Poodle X

SEX

Neutered Male

AGE

13 Years

WEIGHT

22 Pounds

INTERPRETED BY

Kathleen Sennello DVM, MS, Diplomate ACVIM (Small Animal Internal Medicine)

IMAGING BY

Loetitia Saint-Jacques, LVT

HOSPITAL NAME

Brighton Greens VH

REFERRING VET

Dr. Robin Janeway

INVOICE

43082

DATE

11/30/22

PRESENTING CLINICAL SIGNS

recheck- stable- monitoring changes in abdomen- Last blood panel performed in May, current panel, ionized Ca and UPC pending Platelets increased, TP 7.6, ALP 988 (cushings disease), Calcium 12, ionized calcium WNL, T4 3.4, USG 1.014, pH 8.0, 2+ proteinuria, 2-3 amorphous crystals, UPCR 0.8 (<0.5), Current medications: Benazepril 5mg SID Vetoryl, 10mg BID Metacam 0.1mg/kg PO SID Ursodiol 125mg PO SID Pt is also on K/D diet

Abnormal PE/Chem/CBC/UA Results: O no longer monitoring parathyroid nodule, will not be pursuing tx of this.

ULTRASONOGRAPHIC EXAMINATION OF THE ABDOMEN

Urinary System

The urinary bladder is moderately distended with anechoic urine. The Bladder wall, trigone, ureteral papillae and visible urethra (to a depth of 2cm) appear normal with no evidence of wall thickening, mucosal irregularities, or masses. There is a moderate amount of dependent shadowing debris, most consistent with sandy debris/small stones.

The prostate is normal in size (0.89 cm) and shape for this neutered male dog. The parenchyma is homogenous and the external margins are smooth. The prostatic urethra appears normal with no evidence of irregularity, invasion, mass effect or calculi.

The left kidney has a normal shape and size (4.94 cm) with a small non-obstructive nephrolith measuring 0.21 cm. Overall echogenicity is slightly hyperechoic with poor corticomedullary distinction and a typical 1:3 cortex:medulla ratio. There is no evidence of focal perinephric inflammation or effusion. There is no evidence of pyelectasia, infarcts or hydroureter. Renal vasculature is normal.

The right kidney has a normal shape and size (4.56 cm). Overall echogenicity is slightly hyperechoic with poor corticomedullary distinction and a typical 1:3 cortex:medulla ratio. There is no evidence of focal perinephric inflammation or effusion. There is no evidence of pyelectasia, nephroliths, infarcts or hydroureter. Renal vasculature is normal.

Adrenal Glands

The left adrenal gland is large, measuring 0.92 cm at the caudal pole. It is observed in its normal position cranial to the left renal artery. It is normal in appearance (uniformly hypoechoic) and shape with no evidence of a mass effect.

The right adrenal gland is large, measuring 0.81 cm at the caudal pole. It is observed in its normal position between the cranial aspect of the right kidney and the caudal vena cava. It is normal in appearance (uniformly hypoechoic) and shape with no evidence of a mass effect.

Spleen

The spleen is subjectively normal in size, echotexture is homogenous, and the splenic capsule is smooth with no irregularities. The blood flow through the hilus and splenic parenchyma appears normal. No focal parenchymal abnormalities are visualized.

SonoPath
Clinical Sonography & Telecytology
EDUCATIONAL TELECONSULTATION SERVICES™
1-800-838-4268 info@sonopath.com SonoPath.com

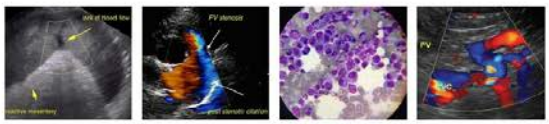

IMAGING PERFORMED BY
pawsonography@gmail.com 530-786-8340

PATIENT

Guinness Siwak

SPECIES

Canine

BREED

Poodle X

SEX

Neutered Male

AGE

13 Years

WEIGHT

22 Pounds

INTERPRETED BY

Kathleen Sennello DVM, MS, Diplomate ACVIM (Small Animal Internal Medicine)

IMAGING BY

Loetitia Saint-Jacques, LVT

HOSPITAL NAME

Brighton Greens VH

REFERRING VET

Dr. Robin Janeway

INVOICE

43082

DATE

11/30/22

Liver

The liver is large in size, and normal in echogenicity with smooth peripheral margins. The parenchyma is heterogenous in echotexture with subtle, indistinct focal mottling. The visible portions of the vasculature and biliary tract appear normal. There are numerous hyperechoic nodules visualized within the parenchyma, one of which measures 1.62 cm x 2.47 cm. Another measures 0.68 cm in diameter and 2.85 cm in diameter. Additionally, there are ill-defined hypoechoic nodules occasionally visualized (previous scan 5/26/22 – hyperechoic nodules measured 1.63 cm, 2.13 cm, and 0.49 cm in diameter).

The gall bladder lumen is significantly distended. Some areas of the wall appear mildly thickened (0.30 cm) with adherent debris and some areas have early mucosal stranding and organization of the debris into an early mucocele. There is a large amount of primarily non-organized echogenic debris present as well. There is no evidence of bile duct dilation.

Gastrointestinal

The stomach contains minimal luminal contents. It measures at a normal thickness of <0.7cm with some variability due to the presence of rugal folds. The distinction of the gastric wall layers is adequate and there is no impression of reduced peristaltic activity. No masses or focal lesions were observed.

The visualized areas of duodenum, jejunum and ileum have a relatively uniform diameter with minimal fluid distension. Wall thickness is normal. Bowel loops follow a curvilinear path with distinct wall layering maintaining the typical 1:3 muscularis:mucosa layer ratio. Duodenum wall measures 0.30 cm. Jejunum wall measures 0.26 cm. Visualized peristalsis appears appropriate. There were no focal lesions consistent with obstruction or a mass effect observed.

The ileocecal junction was visualized and exhibited normal intact wall layering and is subjectively of normal thickness. Sections of colon are visualized with formed fecal material and gas shadowing distally. There is no observed focal or generalized colon wall thickening or loss of layering.

Pancreas

The pancreas is normal and isoechoic to surrounding mesentery. There is no evidence of nodules or cystic lesions. There is no evidence of regional mesenteric inflammation or fluid.

Free Abdomen

Evaluation of the peritoneal cavity did not reveal any evidence of effusion. There is no significant lymphadenopathy present. The pancreaticoduodenal lymph node is prominent at 0.60 cm. The omentum is of normal echogenicity.

PRIMARY FINDINGS

- Dependent sandy debris/small stones in the urinary bladder – recommend urinalysis and culture and continued monitoring.
- Bilateral adrenomegaly – The bilateral adrenomegaly could be consistent with bilateral hyperplasia (e.g., secondary to pituitary-dependent hyperadrenocorticism), bilateral

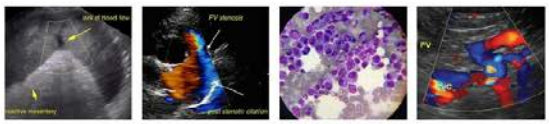

PATIENT

Guinness Siwak

SPECIES

Canine

BREED

Poodle X

SEX

Neutered Male

AGE

13 Years

WEIGHT

22 Pounds

INTERPRETED BY

Kathleen Sennello DVM, MS, Diplomate ACVIM (Small Animal Internal Medicine)

IMAGING BY

Loetitia Saint-Jacques, LVT

HOSPITAL NAME

Brighton Greens VH

REFERRING VET

Dr. Robin Janeway

INVOICE

43082

DATE

11/30/22

infiltrative neoplasia, inflammatory adrenal disease, other. Correlation with clinical findings is recommended.

- Large, heterogeneous liver with hyperechoic nodules and occasional hypoechoic nodules – The diffuse hepatic changes are non-specific and could be consistent with vacuolar hepatopathy, nodular hyperplasia, inflammatory/immune-mediated disease, fibrosis, extramedullary hematopoiesis, toxic hepatopathy (e.g., copper), infiltrative neoplasia (less likely) or other hepatopathy. The appearance of these nodules trends towards a benign etiology. No significant progression of these lesions is noted.

- Early gallbladder mucocele – The gall bladder changes are most consistent with a developing mucocele. Consider medical management and close monitoring for progression of this lesion.

SECONDARY FINDINGS

- Decreased corticomedullary distinction in both kidneys with a small left-sided nephrolith – The bilateral renal findings are consistent with age-related change.

INTERPRETATION OF THE FINDINGS & FURTHER RECOMMENDATIONS

Today's scan appears relatively stable from the previous scan on 5/26/22. There is some dependent sandy debris visualized in the urinary bladder. Recommend a urinalysis and culture, as this can be associated with an infection. Recommend continued monitoring, as there is a small risk of obstruction from the sandy debris.

The changes in the liver appear relatively stable. Of primary concern is that the gallbladder lesion appears mildly progressed. Continue the Ursodiol with continued monitoring of liver values and the gallbladder with ultrasound.

The changes reported in the kidneys are most consistent with chronic age related change. A blood pressure, urinalysis and culture should be considered to establish a baseline.

Recommend three view thoracic radiographs to evaluate for possible concurrent thoracic disease/involvement.

SonoPath
Clinical Sonography & Telecytology
EDUCATIONAL TELECONSULTATION SERVICES™
1-800-838-4268 info@sonopath.com SonoPath.com

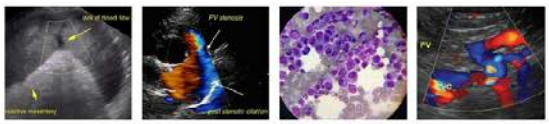

IMAGING PERFORMED BY
pawsonography@gmail.com 530-786-8340

PATIENT

Guinness Siwak

SPECIES

Canine

BREED

Poodle X

SEX

Neutered Male

AGE

13 Years

WEIGHT

22 Pounds

INTERPRETED BY

Kathleen Sennello DVM, MS, Diplomate ACVIM (Small Animal Internal Medicine)

IMAGING BY

Loetitia Saint-Jacques, LVT

HOSPITAL NAME

Brighton Greens VH

REFERRING VET

Dr. Robin Janeway

INVOICE

43082

DATE

11/30/22

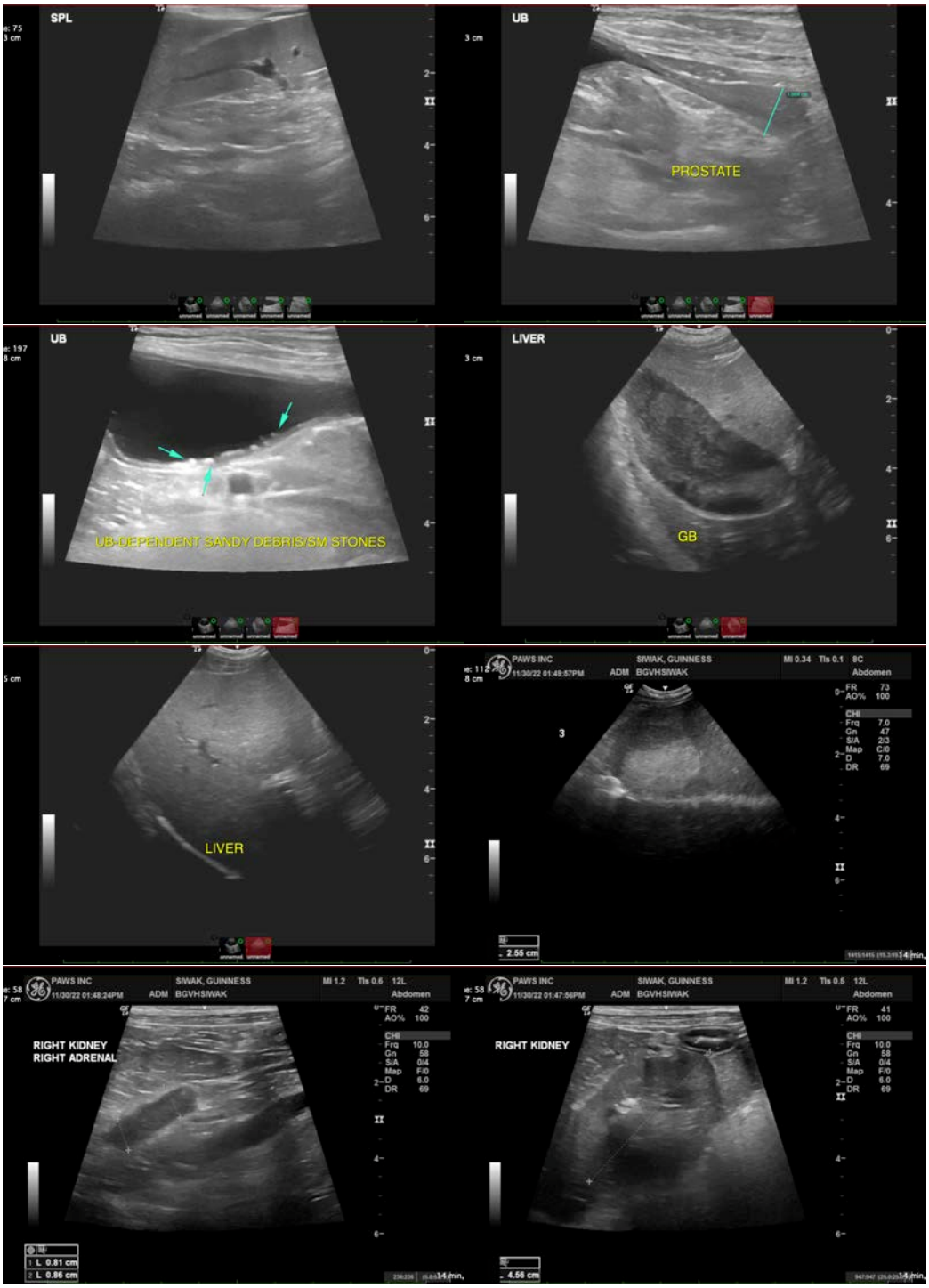

SonoPath
Clinical Sonography & Telecytology
EDUCATIONAL TELECONSULTATION SERVICES™
1-800-838-4268 info@sonopath.com SonoPath.com

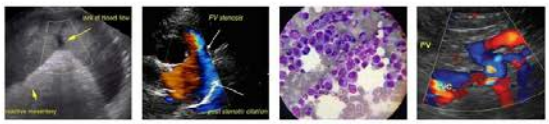

IMAGING PERFORMED BY
pawsonography@gmail.com 530-786-8340

PATIENT

Guinness Siwak

SPECIES

Canine

BREED

Poodle X

SEX

Neutered Male

AGE

13 Years

WEIGHT

22 Pounds

INTERPRETED BY

Kathleen Sennello DVM, MS, Diplomate ACVIM (Small Animal Internal Medicine)

IMAGING BY

Loetitia Saint-Jacques, LVT

HOSPITAL NAME

Brighton Greens VH

REFERRING VET

Dr. Robin Janeway

INVOICE

43082

DATE

11/30/22

SonoPath
Clinical Sonography & Telecytology
EDUCATIONAL TELECONSULTATION SERVICES™
1-800-838-4268 info@sonopath.com SonoPath.com

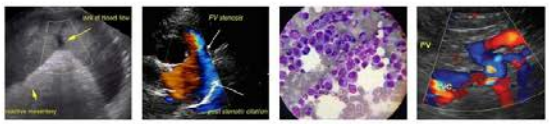

IMAGING PERFORMED BY
pawsonography@gmail.com 530-786-8340

PATIENT

Guinness Siwak

SPECIES

Canine

BREED

Poodle X

SEX

Neutered Male

AGE

13 Years

WEIGHT

22 Pounds

INTERPRETED BY

Kathleen Sennello DVM, MS, Diplomate ACVIM (Small Animal Internal Medicine)

IMAGING BY

Loetitia Saint-Jacques, LVT

HOSPITAL NAME

Brighton Greens VH

REFERRING VET

Dr. Robin Janeway

INVOICE

43082

DATE

11/30/22

The information and recommendations provided are based on the images presented by the referring veterinarian/sonographer. No evaluation can be communicated regarding pathology that was not visible in the image/video clips provided.

Thank you for this referral. If the clinical or image interpretation does not parallel your findings or if I can be of any further assistance please contact me.

Kathleen Sennello DVM,MS, Diplomate ACVIM (Small animal Internal Medicine)
kathleen.sennello@sonopath.com