

**DATE**

11/30/21

**PRESENTING CLINICAL SIGNS**

History: Presented for occasional vomiting, decreased appetite, lethargy. Physical was WNL.  
Current Medications: Was originally treated with Clavamox, 62.5 mg q 12 hours x 14 days, Mirtaz daily, and Cerenia. Currently on no medications.  
Lab Results: chemistries, t4 and free t4 WNL. CBC-WBC 25.8, Lymphocytes 11610. After 2 weeks of meds CBC repeated- WBC 19.9, Lymphocytes 10547.  
Date of Previous IntraPet Ultrasound: No previous IntraPet scans.  
Sedation: Gabapentin. Declined, required for further imaging.  
Stat Report: Not requested.

**PATIENT**

Roxy Taylor

**SPECIES**

Feline

**BREED**

Domestic Shorthair

**SEX**

Spayed Female

**AGE**

1/1/14

**WEIGHT**

8.5 lbs

**INTERPRETED BY**

Kathleen Sennello  
DVM, MS, Diplomate  
ACVIM (Small Animal  
Internal Medicine)

**IMAGING PERFORMED BY**

Rachel Brillhart RDMS

**HOSPITAL NAME**

Chadwell AH

**REFERRING VET**

Dr. Malick

**INVOICE**

94225

**ULTRASONOGRAPHIC EXAMINATION OF THE ABDOMEN****Urinary System**

The urinary bladder is moderately distended with anechoic urine. The Bladder wall, trigone, ureteral papillae and visible urethra (to a depth of 2cm) appear normal with no evidence of wall thickening, mucosal irregularities, masses or cystic calculi.

The left kidney has a normal shape and size (3.78 cm). Overall echogenicity is normal with adequate corticomedullary distinction and a typical 1:3 cortex:medulla ratio. There is no evidence of perinephric inflammation or effusion. There is no evidence of pyelectasia, nephroliths, infarcts or hydroureter. Renal vasculature is normal.

The right kidney has a normal shape and size (3.87 cm). Overall echogenicity is normal with adequate corticomedullary distinction and a typical 1:3 cortex:medulla ratio. There is no evidence of perinephric inflammation or effusion. There is no evidence of pyelectasia, nephroliths, infarcts or hydroureter. Renal vasculature is normal.

**Adrenal Glands**

The region of left adrenal (Cranial to left renal artery) is unremarkable but the adrenal is not distinctly visualized. No evidence of a mass effect.

The right adrenal gland is normal in size measuring 0.4 cm at the caudal pole. It is observed in its normal position between the cranial aspect of the right kidney and the caudal vena cava. It is normal in appearance (uniformly hypoechoic) and shape with no evidence of a mass effect.

**Spleen**

The spleen is subjectively normal in size, echotexture is homogenous, and the splenic capsule is smooth with no irregularities. The blood flow through the hilus and splenic parenchyma appears normal. No focal parenchymal abnormalities are visualized.

**Liver**

The liver is subjectively normal in size, and echogenicity with smooth peripheral margins. The parenchyma is heterogenous in echotexture with subtle, indistinct focal mottling. The visible portions of the vasculature and biliary tract appear normal. There is a hypoechoic, rounded, nodule that measured 1.21 x 0.98 cm in the area of the gallbladder. The wall of the gallbladder is not thickened and has a smooth mucosal surface. Luminal contents are primarily anechoic. The cystic and common bile ducts are normal/not visible.

### ***Gastrointestinal***

The stomach contains minimal luminal contents. It measures at a normal thickness of <0.36cm with some variability due to the presence of rugal folds. The distinction of the gastric wall layers is adequate and there is no impression of reduced peristaltic activity. No masses or focal lesions were observed.

The visualized areas of duodenum, jejunum and ileum have a uniform diameter with minimal fluid distension. Wall thickness is normal to slightly increased. Bowel loops follow a typical curvilinear path with distinct wall layering, but some areas display a prominent muscularis layer which does not display the typical 1:3 muscularis:mucosa layer ratio. The duodenum measured 0.34 cm and the jejunum measured 0.33 cm. Visualized peristalsis appears appropriate. There were no focal lesions consistent with obstruction or a mass effect observed.

The ileocecal junction was visualized and exhibited normal intact wall layering and is subjectively of normal thickness. Sections of colon are visualized with formed fecal material and gas shadowing distally. There is no observed focal or generalized colon wall thickening or loss of layering.

### ***Pancreas***

The region of the pancreas is normal and isoechoic to surrounding mesentery. There is no evidence of nodules or cystic lesions. There is no evidence of regional mesenteric inflammation or fluid.

### ***Free Abdomen***

Evaluation of the peritoneal cavity did not reveal any evidence of effusion. There are visible mesenteric lymph nodes that measured 0.41 cm and 0.38 cm. The omentum is of normal uniform echogenicity.

### ***Heart***

A brief view of the heart was submitted. No pericardial effusion was seen.

## **ULTRASONOGRAPHIC FINDINGS**

### **PRIMARY FINDINGS:**

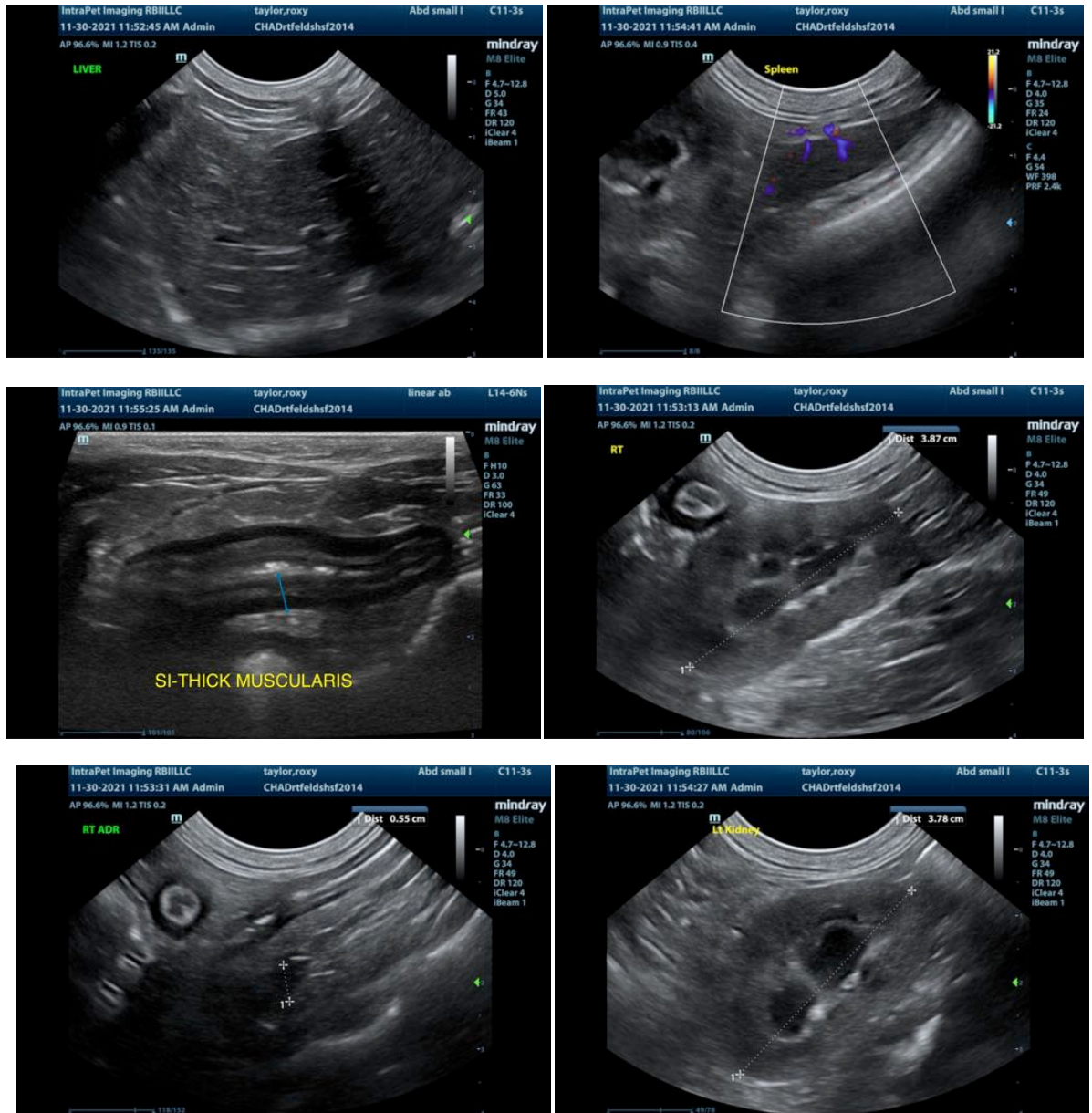
- Heterogenous liver with hypoechoic nodule. The diffuse hepatic changes are non-specific and could be consistent with vacuolar hepatopathy, nodular hyperplasia, inflammatory/immune-mediated disease, fibrosis, extramedullary hematopoiesis, toxic hepatopathy (e.g., copper), infiltrative neoplasia (less likely) or other hepatopathy.
- Thickened small intestine with prominent muscularis layer. The mild small intestinal wall changes may be a normal variant in this patient or could be consistent with an inflammatory process (e.g., inflammatory bowel disease).

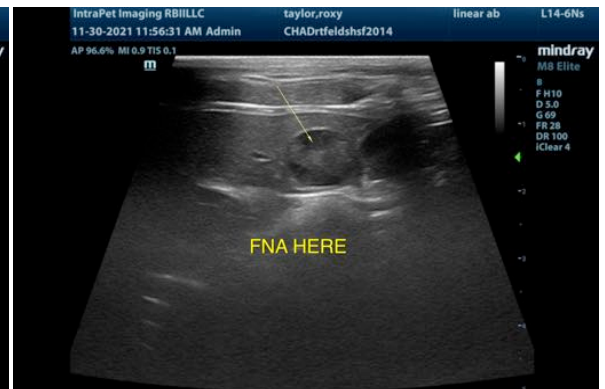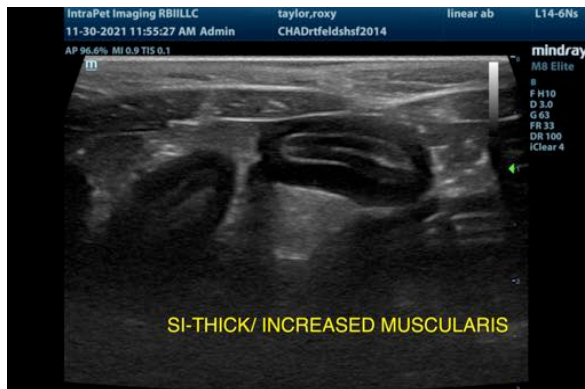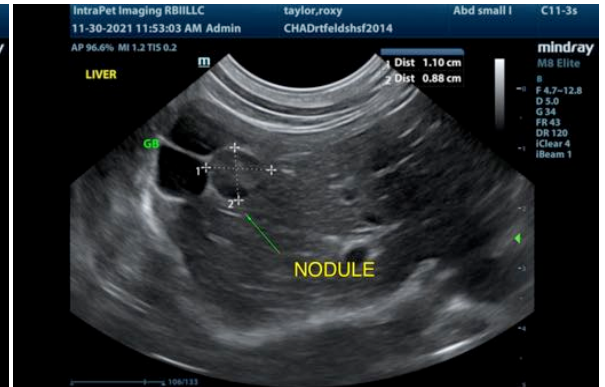
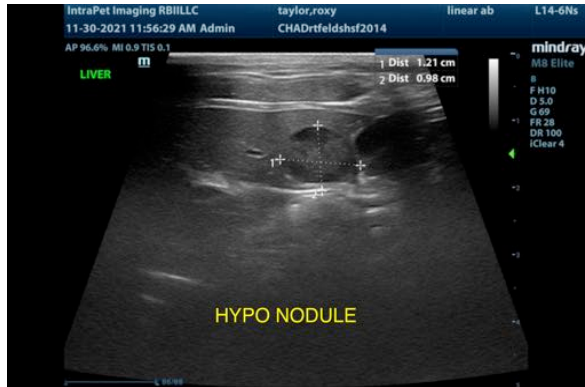
## **INTERPRETATION OF THE FINDINGS & FURTHER RECOMMENDATIONS**

There is a mildly hypoechoic rounded structure near the gallbladder. This could be consistent with a benign or cancerous lesion. Consider FNA to obtain more information regarding this lesion.

The small intestine appears significantly thickened with a very prominent muscularis layer. This combined with the elevated peripheral lymphocyte count is concerning for possible neoplastic condition, but biopsies of the small intestine would be necessary to confirm. Additionally, I would consider a pathologist review of

blood smear to see if this is consistent with leukemia. Recommend a GI panel to Texas A&Ms GI lab to look for evidence of B12 deficiency, bacterial overgrowth etc. I recommend three view thoracic radiographs.





The information and recommendations provided are based on the images presented by the referring veterinarian. No evaluation can be communicated regarding pathology that was not visible in the image/video clips provided.

Thank you for this referral. If the clinical or image interpretation does not parallel your findings or if I can be of any further assistance please contact me.

Kathleen Sennello DVM,MS, Diplomate ACVIM (Small animal Internal Medicine)  
kathleen.sennello@sonopath.com