



PATIENT

Ricky Pardo

PRESENTING CLINICAL SIGNS

Elevated liver values. Current meds: Gabapentin.
Abnormal PE/Chem/CBC/UA Results: ALT 432, ALKP 8218, GGT61, BUN/CREAT 30, Lyme +, USG 1.008, protein 2+

SPECIES

Canine

ULTRASONOGRAPHIC EXAMINATION OF THE ABDOMEN

BREED

Pomeranian

Urinary System

The urinary bladder is moderately distended with anechoic urine. The Bladder wall, trigone, ureteral papillae and visible urethra (to a depth of 2cm) appear normal with no evidence of wall thickening, mucosal irregularities, or masses. There is a hyperechoic focal shadowing mineralization in the dependent portion of the urinary bladder measuring 1.06 cm x 0.66 cm.

SEX

Neutered Male

The prostate is normal in size (0.75 cm) and shape for this neutered male dog. The parenchyma is homogenous and the external margins are smooth. The prostatic urethra appears normal with no evidence of irregularity, invasion, mass effect or calculi.

AGE

12 Years

The left kidney has a normal shape and size (3.76 cm). Overall echogenicity is slightly hyperechoic with poor corticomedullary distinction and a typical 1:3 cortex:medulla ratio. There is no evidence of focal perinephric inflammation or effusion. There is no evidence of pyelectasia, nephroliths, infarcts or hydroureter. Renal vasculature is normal.

WEIGHT

14.8 Pounds

The right kidney has a normal shape and size (4.07 cm). Overall echogenicity is slightly hyperechoic with poor corticomedullary distinction and a typical 1:3 cortex:medulla ratio. There is no evidence of focal perinephric inflammation or effusion. A cortical cyst is noted measuring 0.99 cm in diameter. There is no evidence of pyelectasia, nephroliths, infarcts or hydroureter. Renal vasculature is normal.

INTERPRETED BY

Kathleen Sennello DVM,
MS, Diplomate ACVIM
(Small Animal Internal
Medicine)

Adrenal Glands

The left adrenal gland is large and irregular in shape. It is observed in its normal position cranial to the left renal artery. It primarily consists of a large, mixed echogenic, globoid mass effect measuring approximately 2.48 cm x 3.21 cm. There is no overt evidence of vascular invasion, but the lesion impinges on the local vasculature.

IMAGING PERFORMED BY

Shari Reffi, CVT

The right adrenal gland is normal in size measuring 0.66 cm at the caudal pole. It is observed in its normal position between the cranial aspect of the right kidney and the caudal vena cava. It is normal in appearance (uniformly hypoechoic) and shape with no evidence of a mass effect.

HOSPITAL NAME

AH of Roxbury

Spleen

The spleen is subjectively normal in size, echotexture is homogenous, and the splenic capsule is smooth with no irregularities. The blood flow through the hilus and splenic parenchyma appears normal. No focal parenchymal abnormalities are visualized.

REFERRING VET

Dr. Elia

Liver

The liver is large with normal echogenicity and smooth peripheral margins. The parenchyma is heterogenous in echotexture with subtle, indistinct focal mottling. The visible portions of the vasculature and biliary tract appear normal. No focal nodules or cystic lesions are observed.

INVOICE

42528

The gallbladder lumen is moderately distended. The wall of the gall bladder is not thickened and has a smooth mucosal surface. Luminal contents are mild and primarily anechoic. The cystic and common bile ducts are normal/not visible.

DATE

11/3/22



PATIENT

Gastrointestinal

Ricky Pardo

The stomach contains minimal luminal contents. It measures at a normal thickness of <0.7cm with some variability due to the presence of rugal folds. The distinction of the gastric wall layers is adequate and there is no impression of reduced peristaltic activity. No masses or focal lesions were observed.

SPECIES

Canine

The visualized areas of duodenum, jejunum and ileum have a relatively uniform diameter with minimal fluid distension. Wall thickness is normal. Bowel loops follow a curvilinear path with distinct wall layering maintaining the typical 1:3 muscularis:mucosa layer ratio. The duodenum measured as normal (between 0.3-0.5cm in wall thickness) and the jejunum measured as normal (between 0.2-0.47cm.)

BREED

Pomeranian

Visualized peristalsis appears appropriate. There were no focal lesions consistent with obstruction or a mass effect observed.

SEX

Neutered Male

The ileocecal junction was visualized and exhibited normal intact wall layering and is subjectively of normal thickness. Sections of colon are visualized with formed fecal material and gas shadowing distally. There is no observed focal or generalized colon wall thickening or loss of layering.

Pancreas

AGE

12 Years

The pancreas is normal and isoechoic to surrounding mesentery. There is no evidence of nodules or cystic lesions. There is no evidence of regional mesenteric inflammation or fluid.

Free Abdomen

WEIGHT

14.8 Pounds

Evaluation of the peritoneal cavity did not reveal any evidence of effusion, or subjective lymphadenomegaly. The Medial iliac nodes appear normal and there was no evidence of a caudal aortic thrombus at the bifurcation. The omentum is of normal uniform echogenicity.

INTERPRETED BY

Kathleen Sennello DVM,
MS, Diplomate ACVIM
(Small Animal Internal
Medicine)

- Hyperechoic, shadowing mineralization in the dependent portion of the urinary bladder – Findings are most consistent with a bladder stone. Recommend urinalysis and culture.

IMAGING PERFORMED BY

Shari Reffi, CVT

- Large, mixed echogenic, hypoechoic left-sided adrenal mass – Adrenomegaly could be consistent with neoplasia (e.g., adenoma, carcinoma, pheochromocytoma), hyperplasia, inflammation, other.

HOSPITAL NAME

AH of Roxbury

- Large, heterogeneous liver – The diffuse hepatic changes are non-specific and could be consistent with vacuolar hepatopathy, nodular hyperplasia, inflammatory/immune-mediated disease, fibrosis, extramedullary hematopoiesis, toxic hepatopathy (e.g., copper), infiltrative neoplasia (less likely) or other hepatopathy.

SECONDARY FINDINGS

- Decreased corticomedullary distinction in both kidneys – The bilateral renal findings are consistent with age-related change.

REFERRING VET

Dr. Elia

INTERPRETATION OF THE FINDINGS & FURTHER RECOMMENDATIONS

INVOICE

42528

There is a large left-sided adrenal mass visualized. This could represent a benign or neoplastic lesion and could be secreting hormone or be non-secretory. The large size of this lesion is concerning for possible vascular invasion, but there is no evidence visualized at this time. Consider the following diagnostic and therapeutic plan:

DATE

11/3/22



PATIENT

Ricky Pardo

- If signs of cushings are present, consider adrenal function testing. I prefer an ACTH stimulation test combined with an adrenal panel to the University of Tennessee’s endocrine lab to look for atypical adrenal hormones as well as cortisol. (other testing can suffice)

SPECIES

Canine

- If adrenal dependent cushings is suspected and supported by adrenal function testing consider medical therapy with lysodren or trilostane and/or consider surgical removal (recommend referral to a board certified veterinary surgeon and possible pre op CT)-This can be a challenging surgery with significant risk for complication

BREED

Pomeranian

- Recommend blood pressure evaluation-if hypertensive consider testing catecholamine levels for a possible pheochromocytoma

SEX

Neutered Male

- Due to the invasive nature of these masses a CT scan is recommended to evaluate for metastasis and vascular invasion.

AGE

12 Years

- If no symptoms of cushings are present, consider either referral for surgery or if surgery is not an option consultation with a veterinary oncologist regarding chemotherapeutic options and continued monitoring with ultrasound (in 4-6 weeks) can be considered.

- Some aggressive adrenal tumors can grow quickly and there is risk for acute hemorrhage from vascular invasion.

WEIGHT

14.8 Pounds

Recommend three view thoracic radiographs to evaluate for possible concurrent thoracic disease/involvement.

INTERPRETED BY

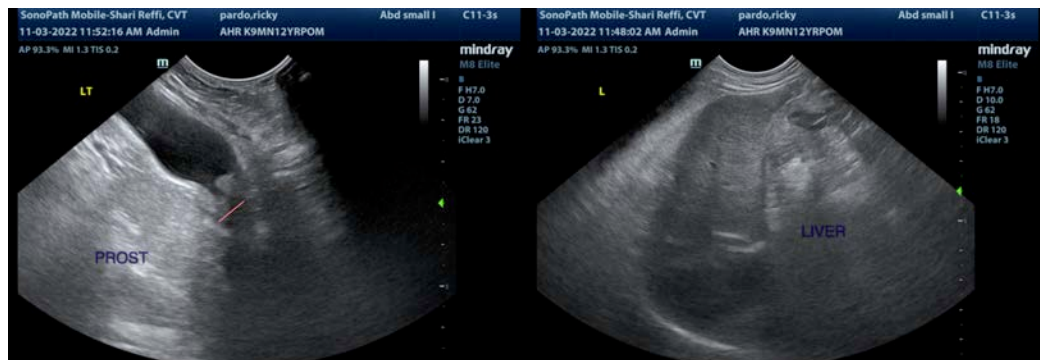
Kathleen Sennello DVM,
MS, Diplomate ACVIM
(Small Animal Internal
Medicine)

It is very possible that the elevation in liver enzymes is secondary to hormone release from the adrenal mass (adrenal dependent Cushing’s). Based on today’s evaluation, I feel that it is worth performing a CT scan to see if this can be surgically removed. If there is concern that this is a primary hepatopathy, not a steroid hepatopathy, then consider a fine needle aspirate of the liver and a liver function test.

There is a dependent stone in the urinary bladder. Recommend urinalysis and culture. If the patient is clinical for this stone, then a cystotomy would likely be necessary for removal. Correlate the size and location of this stone with abdominal radiographs.

IMAGING PERFORMED BY

Shari Reffi, CVT



HOSPITAL NAME

AH of Roxbury

REFERRING VET

Dr. Elia

INVOICE

42528

DATE

11/3/22



PATIENT

Ricky Pardo

SPECIES

Canine

BREED

Pomeranian

SEX

Neutered Male

AGE

12 Years

WEIGHT

14.8 Pounds

INTERPRETED BY

Kathleen Sennello DVM,
MS, Diplomate ACVIM
(Small Animal Internal
Medicine)

**IMAGING
PERFORMED BY**

Shari Reffi, CVT

HOSPITAL NAME

AH of Roxbury

REFERRING VET

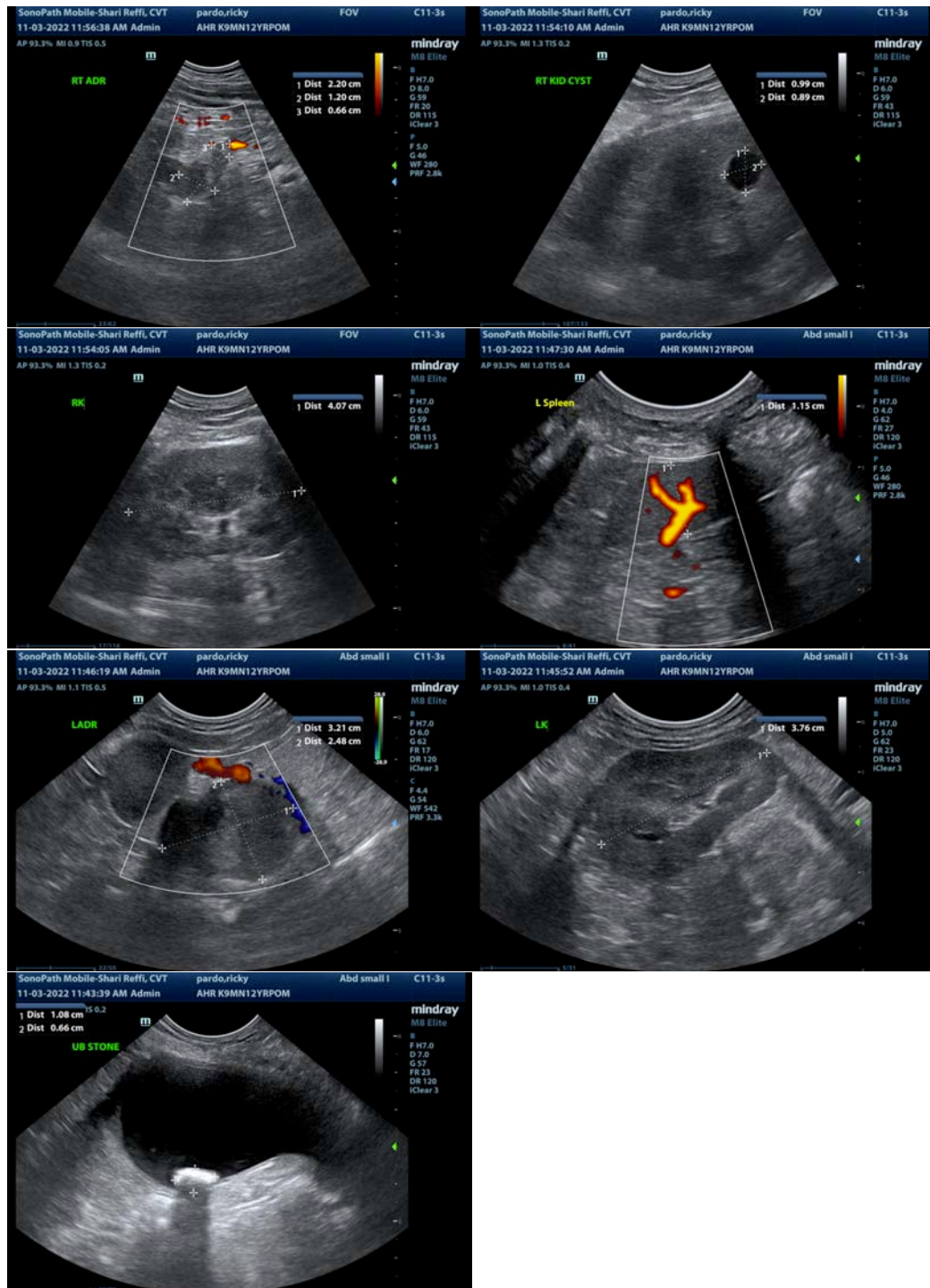
Dr. Elia

INVOICE

42528

DATE

11/3/22





PATIENT

Ricky Pardo

The information and recommendations provided are based on the images presented by the referring veterinarian/sonographer. No evaluation can be communicated regarding pathology that was not visible in the image/video clips provided.

SPECIES

Canine

Thank you for this referral. If the clinical or image interpretation does not parallel your findings or if I can be of any further assistance please contact me.

Kathleen Sennello DVM,MS, Diplomate ACVIM (Small animal Internal Medicine)

BREED

Pomeranian

kathleen.sennello@sonopath.com

SEX

Neutered Male

AGE

12 Years

WEIGHT

14.8 Pounds

INTERPRETED BY

Kathleen Sennello DVM,
MS, Diplomate ACVIM
(Small Animal Internal
Medicine)

**IMAGING
PERFORMED BY**

Shari Reffi, CVT

HOSPITAL NAME

AH of Roxbury

REFERRING VET

Dr. Elia

INVOICE

42528

DATE

11/3/22