



**PATIENT**

Minnie Lance

**SPECIES**

Feline

**BREED**

DSH

**SEX**

Spayed Female

**AGE**

15 Years

**WEIGHT**

9.3 Pounds

**INTERPRETED BY**

Kathleen Sennello DVM,  
MS, Diplomate ACVIM  
(Small Animal Internal  
Medicine)

**IMAGING  
PERFORMED BY**

Dr. Judy Schroeder

**HOSPITAL NAME**

Animal Health  
Associates

**REFERRING VET**

Dr. Judy Schroeder

**INVOICE**

42533

**DATE**

11/3/22

**PRESENTING CLINICAL SIGNS**

Patient seen for vomiting with blood and weight loss in August, which resolved with symptomatic treatment. Patient seen again end of October for same symptoms. Symptoms are improved with treatment, but weight loss continues. Patient has mildly elevated T4 and mild-moderate increase in fPL.

Abnormal PE/Chem/CBC/UA Results: ALP 63 U/l, normal ALT, bili Spec fPL 7.5 ug/l T4 4.9 ug/dl CBC unremarkable UA pending

**ULTRASONOGRAPHIC EXAMINATION OF THE ABDOMEN**

**Urinary System**

The urinary bladder is moderately distended with anechoic urine. The Bladder wall, trigone, ureteral papillae and visible urethra (to a depth of 2cm) appear normal with no evidence of wall thickening, mucosal irregularities, masses or cystic calculi.

The left kidney is normal in size but somewhat irregular, measuring 3.12 cm. There is a hyperechoic region in the caudal pole, most consistent with a previous infarct and a 0.76 cm cortical cyst. Overall echogenicity is slightly hyperechoic with poor corticomedullary distinction and a typical 1:3 cortex:medulla ratio. There is no evidence of focal perinephric inflammation or effusion. There is no evidence of pyelectasia, nephroliths or hydroureter. Renal vasculature is normal.

The right kidney has a normal shape and size (3.79 cm). Overall echogenicity is slightly hyperechoic with poor corticomedullary distinction and a typical 1:3 cortex:medulla ratio. There is no evidence of focal perinephric inflammation or effusion. There is no evidence of pyelectasia, nephroliths, infarcts or hydroureter. Renal vasculature is normal.

**Adrenal Glands**

The left adrenal gland is normal in size measuring 0.37 cm at the caudal pole. It is observed in its normal position cranial to the left renal artery. It is normal in appearance (uniformly hypoechoic) and shape with no evidence of a mass effect.

The right adrenal gland is normal in size measuring 0.41 cm at the caudal pole. It is observed in its normal position between the cranial aspect of the right kidney and the caudal vena cava. It is normal in appearance (uniformly hypoechoic) and shape with no evidence of a mass effect.

**Spleen**

The spleen is subjectively normal in size (0.71 cm), echotexture is homogenous, and the splenic capsule is smooth with no irregularities. The blood flow through the hilus and splenic parenchyma appears normal. No focal parenchymal abnormalities are visualized.

**Liver**

The liver is subjectively normal in size, and echogenicity with smooth peripheral margins. The parenchyma is heterogenous in echotexture with subtle, indistinct focal mottling. The visible portions of the vasculature and biliary tract appear normal. There is a somewhat ill-defined hypoechoic nodule visualized within the parenchyma measuring 0.71 cm.

The gallbladder lumen is moderately distended. The wall of the gall bladder is not thickened and has a smooth mucosal surface. Luminal contents are mild and primarily anechoic. The cystic and common bile ducts are normal/not visible.



**PATIENT**

***Gastrointestinal***

Minnie Lance

The stomach contains minimal luminal contents. It measures at a normal thickness of <0.36cm with some variability due to the presence of rugal folds. The distinction of the gastric wall layers is adequate and there is no impression of reduced peristaltic activity. No masses or focal lesions were observed.

**SPECIES**

Feline

The visualized areas of duodenum, jejunum and ileum have a uniform diameter with minimal fluid distension. Wall thickness is normal to slightly increased. Bowel loops follow a typical curvilinear path with distinct wall layering, but some areas display a prominent muscularis layer which does not display the typical 1:3 muscularis:mucosa layer ratio. Duodenum wall measured 0.26 cm. Jejunum wall measures 0.23 cm. Visualized peristalsis appears appropriate. There were no focal lesions consistent with obstruction or a mass effect observed.

**BREED**

DSH

**SEX**

Spayed Female

The ileocecal junction was visualized and exhibited normal intact wall layering and is subjectively of normal thickness. Sections of colon are visualized with formed fecal material and gas shadowing distally. There is no observed focal or generalized colon wall thickening or loss of layering.

***Pancreas***

**AGE**

15 Years

The pancreas is prominent and hypoechoic as compared to the surrounding isoechoic mesentery. There is no evidence of nodules or cystic lesions. There is no evidence of regional mesenteric inflammation or fluid.

***Free Abdomen***

**WEIGHT**

9.3 Pounds

Evaluation of the peritoneal cavity did not reveal any evidence of effusion, or subjective lymphadenomegaly. The Medial iliac nodes appear normal and there was no evidence of a caudal aortic thrombus at the bifurcation. The omentum is of normal uniform echogenicity.

**INTERPRETED BY**

Kathleen Sennello DVM,  
MS, Diplomate ACVIM  
(Small Animal Internal  
Medicine)

**ULTRASONOGRAPHIC FINDINGS**

- Decreased corticomedullary distinction in both kidneys with a left-sided cortical cyst and likely previous infarct – The bilateral renal findings are consistent with age-related change.
- Hypoechoic, prominent pancreas – The pancreatic changes are most consistent with mild pancreatitis or a recent episode of pancreatic inflammation.
- Mildly heterogeneous liver with a hypoechoic nodule – Hepatic changes are non-specific and could be consistent with inflammation/infection (cholangiohepatitis), infiltrative neoplasia, lipodosis or other hepatopathy. The hypoechoic nodule does not appear to interfere with normal hepatic architecture and could represent a benign or neoplastic lesion.
- Prominent muscularis layer to the small intestine – The small intestinal wall changes could be consistent with an underlying inflammatory process. These types of changes can sometimes be seen in normal older cats. Correlate with clinical signs.

**IMAGING PERFORMED BY**

Dr. Judy Schroeder

**HOSPITAL NAME**

Animal Health  
Associates

**REFERRING VET**

Dr. Judy Schroeder

**INTERPRETATION OF THE FINDINGS & FURTHER RECOMMENDATIONS**

The changes observed in the kidneys are most consistent with age related chronic renal disease. Recommend a blood pressure, urinalysis +/- culture for a baseline.

**INVOICE**

42533

The pancreas appears somewhat hypoechoic and prominent, and it appears somewhat mottled in the right limb. This could be consistent with a previous episode of pancreatitis or mild current pancreatitis. Correlate with an fPLI level.

**DATE**

11/3/22



**PATIENT**

Minnie Lance

The liver is somewhat heterogeneous with a hypoechoic nodule. It is relatively small but a fine needle aspirate could be considered. Alternately, recommend continued monitoring with ultrasound. Some of the parenchymal change could be consistent with age related remodeling, but given the elevated ALP, there could be underlying primary liver disease. Consider a fine needle aspirate of the liver if liver enzymes continue to rise, provided coagulation parameters are normal.

**SPECIES**

Feline

The small bowel appears somewhat ropey on today's exam. I suspect this might be associated with the weight loss reported. Consider the possibility of primary gastrointestinal disease.

**BREED**

DSH

Consider such differentials as food allergy/dietary intolerance, GI parasitism, chronic pancreatitis, IBD and less likely neoplasia, etc..

**SEX**

Spayed Female

- Consider a novel protein/hydrolyzed protein diet (exclusively at least 4-6 weeks)
- Consider a GI panel to Texas A&M for evaluation of B12 levels, folate, PLI/TLI etc.. to further evaluate for pancreatic/small intestinal disease.
- Recommend three view thoracic radiographs to evaluate for possible concurrent thoracic disease/involvement.
- If symptoms are persisting, consider an upper GI endoscopy to evaluate the stomach and to obtain biopsies of the stomach and small intestine.

**AGE**

15 Years

**WEIGHT**

9.3 Pounds

In some regions, the pancreas appears somewhat irregular and mottled. This area should be monitored by ultrasound for the development of a progressive lesion. If additional images of the abnormal pancreatic regions are available, please feel free to send and I will evaluate FURTHER.

**INTERPRETED BY**

Kathleen Sennello DVM,  
MS, Diplomate ACVIM  
(Small Animal Internal  
Medicine)

**IMAGING PERFORMED BY**

Dr. Judy Schroeder

**HOSPITAL NAME**

Animal Health  
Associates

**REFERRING VET**

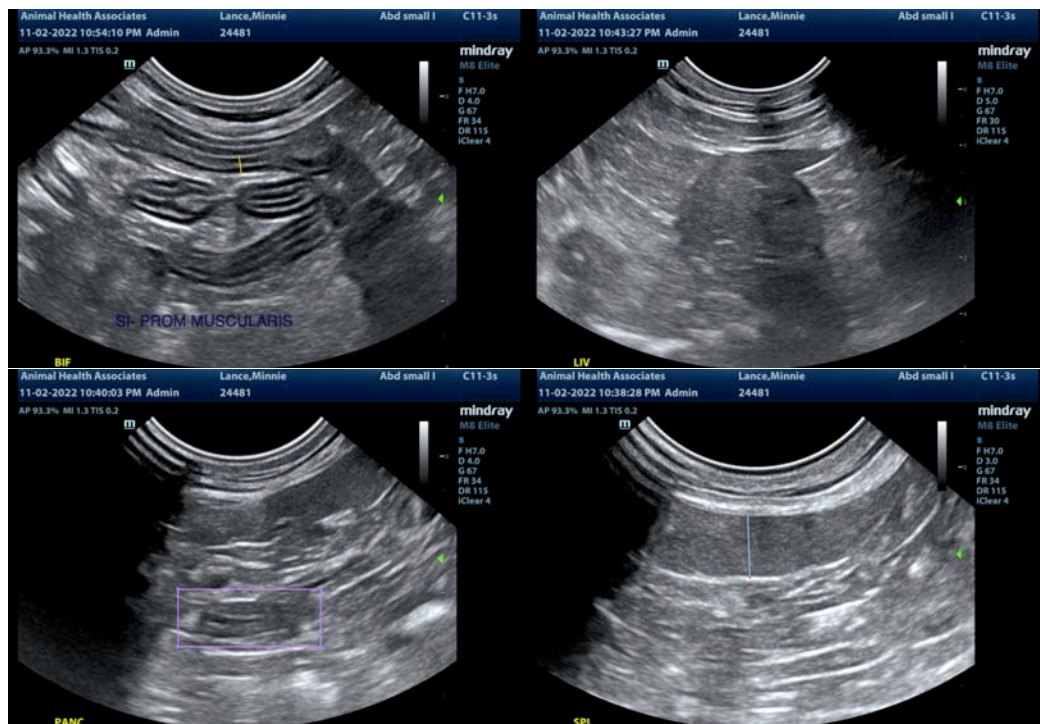
Dr. Judy Schroeder

**INVOICE**

42533

**DATE**

11/3/22





**PATIENT**

Minnie Lance

**SPECIES**

Feline

**BREED**

DSH

**SEX**

Spayed Female

**AGE**

15 Years

**WEIGHT**

9.3 Pounds

**INTERPRETED BY**

Kathleen Sennello DVM,  
MS, Diplomate ACVIM  
(Small Animal Internal  
Medicine)

**IMAGING  
PERFORMED BY**

Dr. Judy Schroeder

**HOSPITAL NAME**

Animal Health  
Associates

**REFERRING VET**

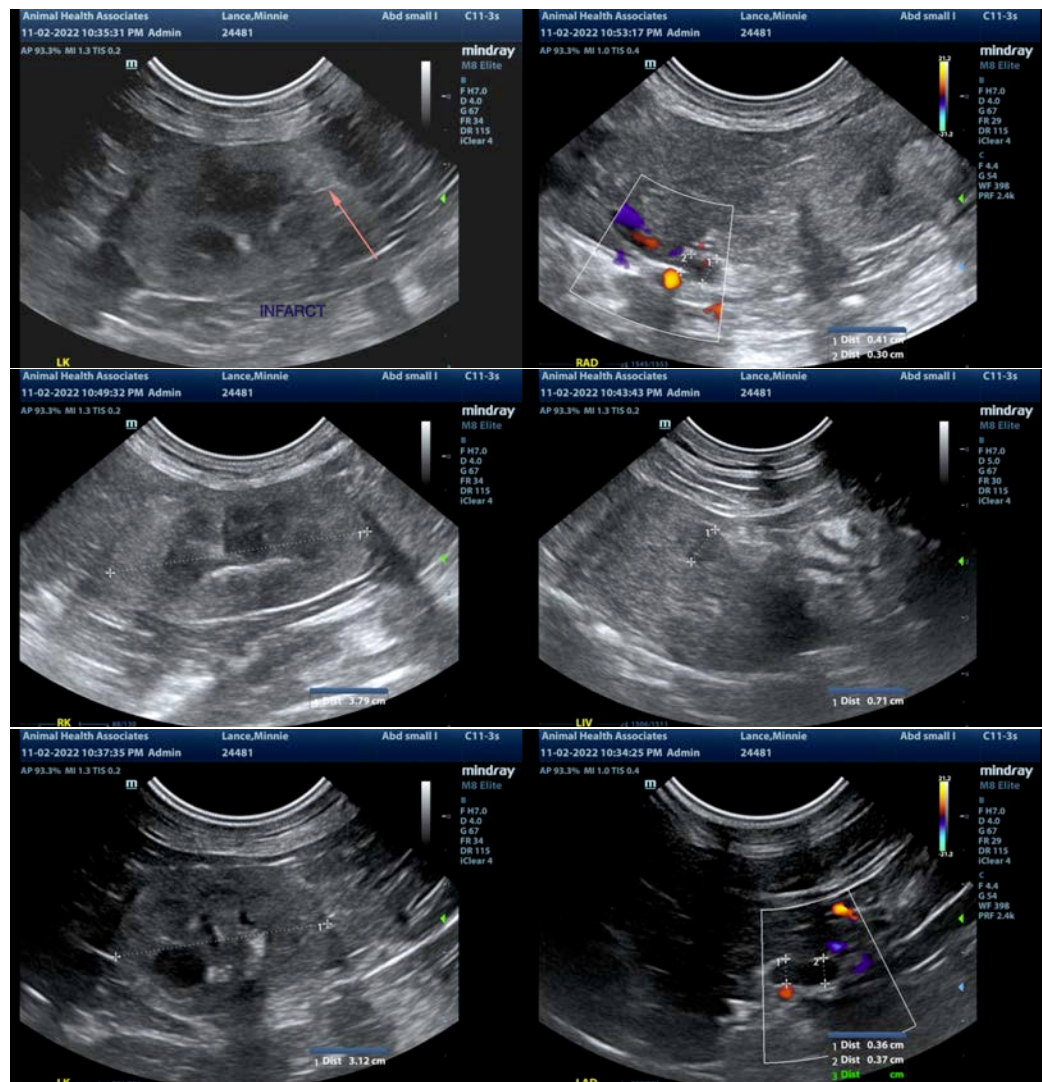
Dr. Judy Schroeder

**INVOICE**

42533

**DATE**

11/3/22



The information and recommendations provided are based on the images presented by the referring veterinarian/sonographer. No evaluation can be communicated regarding pathology that was not visible in the image/video clips provided.

Thank you for this referral. If the clinical or image interpretation does not parallel your findings or if I can be of any further assistance please contact me.

Kathleen Sennello DVM,MS, Diplomate ACVIM (Small animal Internal Medicine)

kathleen.sennello@sonopath.com