



PATIENT

Edward Rooney

SPECIES

Canine

BREED

Lab X

SEX

Neutered Male

AGE

9 Years

WEIGHT

101 Pounds

INTERPRETED BY

Kathleen Sennello DVM,
MS, Diplomate ACVIM
(Small Animal Internal
Medicine)

**IMAGING
PERFORMED BY**

Anthony Smatt

HOSPITAL NAME

The Pets I Love

REFERRING VET

Dr. Debra Szpicek

INVOICE

42544

DATE

11/3/22

PRESENTING CLINICAL SIGNS

patient has pulmonary disease and enlarge heart. No evidence of obvious nodules or neoplasia within the chest. Radiologist recommended abdominal ultrasound.

Abnormal PE/Chem/CBC/UA Results: none

ULTRASONOGRAPHIC EXAMINATION OF THE ABDOMEN

Urinary System

The urinary bladder is moderately distended with anechoic urine. The Bladder wall, trigone, ureteral papillae and visible urethra (to a depth of 2cm) appear normal with no evidence of wall thickening, mucosal irregularities, masses or cystic calculi.

The visualized areas of prostate and surrounding tissue appear normal. Unfortunately, the prostate is not fully visualized likely due to its intrapelvic location. Correlate with rectal exam findings.

The left kidney has a normal shape and size (7.2 cm). Overall echogenicity is normal with adequate corticomedullary distinction and a typical 1:3 cortex:medulla ratio. There is no evidence of focal perinephric inflammation or effusion. There is no evidence of pyelectasia, nephroliths, infarcts or hydroureter. Renal vasculature is normal.

The right kidney has a normal shape and size (6.98 cm). Overall echogenicity is normal with adequate corticomedullary distinction and a typical 1:3 cortex:medulla ratio. There is no evidence of focal perinephric inflammation or effusion. There is no evidence of pyelectasia, nephroliths, infarcts or hydroureter. Renal vasculature is normal.

Adrenal Glands

The region of left adrenal (Cranial to left renal artery) is unremarkable but the adrenal is not distinctly visualized. No evidence of a mass effect.

The region of the right adrenal (between right cranial kidney and vena cava) is unremarkable, but the adrenal is not distinctly visualized. No evidence of a mass effect.

Spleen

The spleen is normal in size but irregular in shape. The blood flow through the hilus and splenic parenchyma appears normal. A hypoechoic mass effect is visualized in the cranial third of the spleen measuring 3.85 cm x 3.64 cm.

Liver

The liver is large and irregular with rounded margins. I cannot differential if the caudal liver has a mass effect or just an irregular margin. The parenchyma is heterogenous in echotexture with subtle, indistinct focal mottling. The visible portions of the vasculature and biliary tract appear normal. No focal nodules or cystic lesions are observed.

The gallbladder lumen is moderately distended. The wall of the gall bladder is not thickened and has a smooth mucosal surface. Luminal contents are mild and primarily anechoic. The cystic and common bile ducts are normal/not visible.



PATIENT

Gastrointestinal

Edward Rooney

The stomach is moderately dilated with fluid and irregular shadowing material most consistent with normal ingesta and gas. It measures at a normal thickness of <0.7cm with some variability due to the presence of rugal folds. The distinction of the gastric wall layering is adequate and there is no impression of reduced peristaltic activity. No masses or focal lesions were observed.

SPECIES

Canine

The visualized areas of duodenum, jejunum and ileum have a relatively uniform diameter with minimal fluid distension. Wall thickness is normal. Bowel loops follow a curvilinear path with distinct wall layering maintaining the typical 1:3 muscularis:mucosa layer ratio. The duodenum measured as normal (between 0.3-0.5cm in wall thickness) and the jejunum measured as normal (between 0.2-0.47cm.)

BREED

Lab X

Visualized peristalsis appears appropriate. There were no focal lesions consistent with obstruction or a mass effect observed.

SEX

Neutered Male

The ileocecal junction was visualized and exhibited normal intact wall layering and is subjectively of normal thickness. Sections of colon are visualized with formed fecal material and gas shadowing distally. There is no observed focal or generalized colon wall thickening or loss of layering.

AGE

9 Years

Pancreas

The area of the pancreas is normal and isoechoic to surrounding mesentery. There is no evidence of nodules or cystic lesions. There is no evidence of regional mesenteric inflammation or fluid.

WEIGHT

101 Pounds

Free Abdomen

There is a small amount of free fluid near the tail of the spleen. No lymphadenopathy noted. The omentum is generally of normal echogenicity.

INTERPRETED BY

Kathleen Sennello DVM,
MS, Diplomate ACVIM
(Small Animal Internal
Medicine)

- Hypoechoic splenic mass – A focal solid mixed echogenicity mass is visualized associate with the spleen. This mass distorts the splenic capsule. Differentials include : benign lesions (lymphoid hyperplasia, hemangioma etc..) or cancerous lesions (hemangiosarcoma, lymphoma, histiocytic sarcoma etc..)
- Large, irregular, heterogeneous liver – The diffuse hepatic changes are non-specific and could be consistent with vacuolar hepatopathy, nodular hyperplasia, inflammatory/immune-mediated disease, fibrosis, extramedullary hematopoiesis, toxic hepatopathy (e.g., copper), infiltrative neoplasia (less likely) or other hepatopathy.
- Free abdominal fluid (small amount)

IMAGING PERFORMED BY

Anthony Smatt

HOSPITAL NAME

The Pets I Love

INTERPRETATION OF THE FINDINGS & FURTHER RECOMMENDATIONS

There appears to be a hypoechoic mass lesion in the cranial third of the spleen. Additionally, there is some free fluid near the tail of the spleen. This could be concerning for hemorrhage. Consider sampling to better evaluate. The liver is large and heterogeneous with irregular margins. This could just be a large, congested liver, or there could be an isoechoic mass effect present. Recommend 3-view thoracic radiographs and consider a splenectomy for both diagnostic and therapeutic purposes, provided the pulmonary and cardiac disease is not too severe.

REFERRING VET

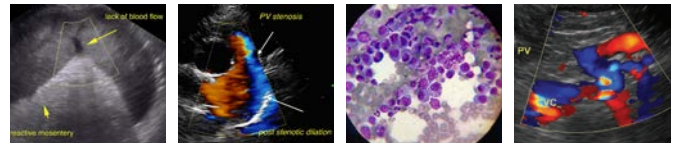
Dr. Debra Szpicek

INVOICE

42544

DATE

11/3/22



PATIENT

Edward Rooney

SPECIES

Canine

BREED

Lab X

SEX

Neutered Male

AGE

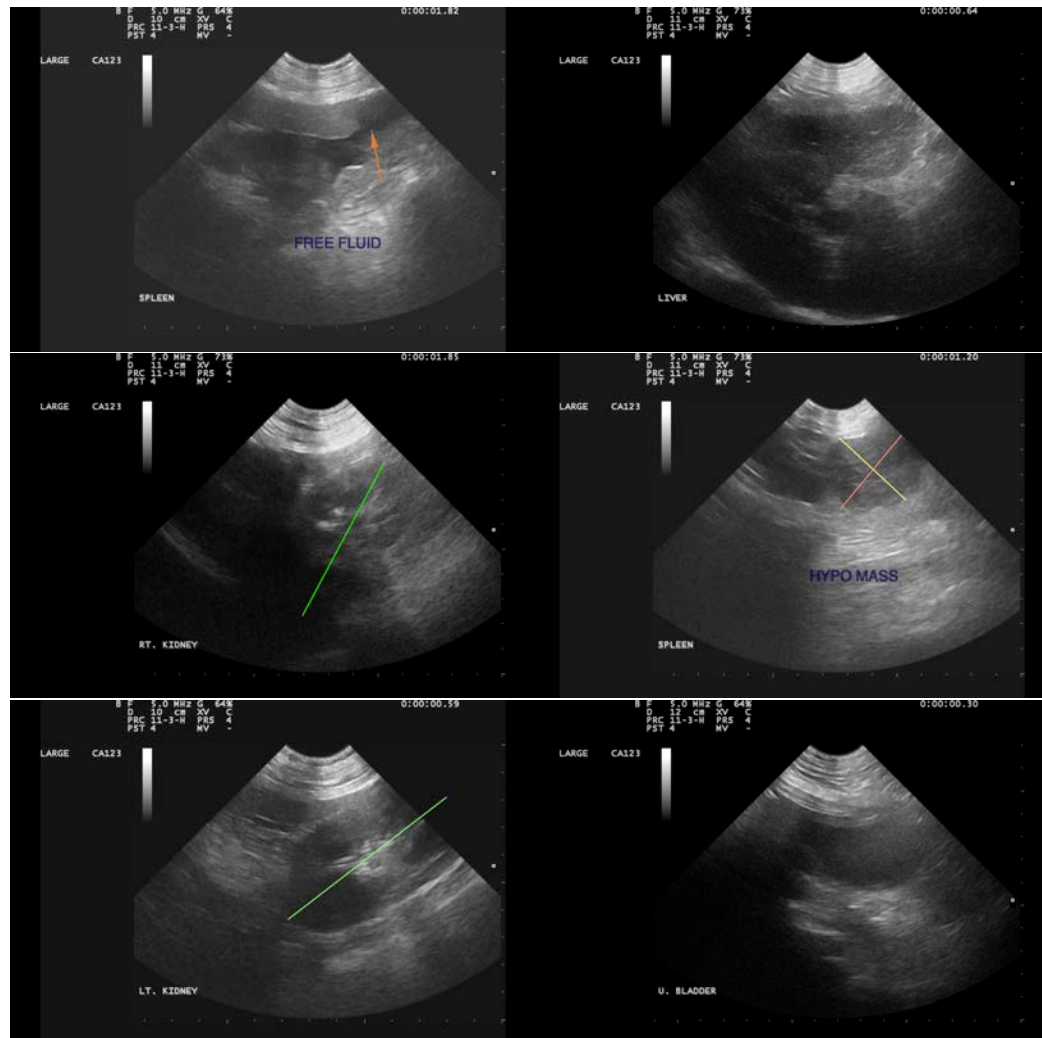
9 Years

WEIGHT

101 Pounds

INTERPRETED BY

Kathleen Sennello DVM,
MS, Diplomate ACVIM
(Small Animal Internal
Medicine)



IMAGING PERFORMED BY

Anthony Smatt

HOSPITAL NAME

The Pets I Love

REFERRING VET

Dr. Debra Szpicek

INVOICE

42544

DATE

11/3/22

The information and recommendations provided are based on the images presented by the referring veterinarian/sonographer. No evaluation can be communicated regarding pathology that was not visible in the image/video clips provided.

Thank you for this referral. If the clinical or image interpretation does not parallel your findings or if I can be of any further assistance please contact me.

Kathleen Sennello DVM,MS, Diplomate ACVIM (Small animal Internal Medicine)

kathleen.sennello@sonopath.com