

**DATE PRESENTING CLINICAL SIGNS**

11/3/22 For last 2 weeks, O. has been walking dog and noticed blood towards the end of his urination. No straining or increased frequency of urination. No Pu/PD.

**PATIENT**

Baloo Nolker

Current Medications: supplements for arthritis.

Lab Results: U/A- SG 1.029, RBC 11-20 rest wnl.

Date of Previous IntraPet Ultrasound: No previous.

**SPECIES**

Canine

Sedation: Not required to complete full diagnostic ultrasound.

Stat Report: Not requested.

**ULTRASONOGRAPHIC EXAMINATION OF THE ABDOMEN****BREED**

Bernese Mtn Dog

**Urinary System**

The urinary bladder is moderately distended with somewhat echogenic urine. Much of the bladder wall appears normal, but in the apical dorsal aspect of the urinary bladder, there is an irregular mass effect measuring 2.95 cm x 3.91 cm. The region of the trigone, ureteral papillae and proximal urethra appear free of any mass lesions, calculi, etc. Findings are most concerning for a bladder tumor, much less likely an irregular adhered blood clot.

**SEX**

Neutered Male

**AGE**

5/17/09

The prostate is normal in size (1.4 cm) and shape for this neutered male dog. The parenchyma is homogenous and the external margins are smooth. The prostatic urethra appears normal with no evidence of irregularity, invasion, mass effect or calculi.

**WEIGHT**

80.2 Pounds

The left kidney is normal in size (6.19 cm) but irregular in shape. There is a very large cortical cyst arising from the left kidney, distorting normal architecture. The cyst measures 8.37 cm x 6.7 cm. Overall echogenicity is slightly hyperechoic with poor corticomedullary distinction and a typical 1:3 cortex:medulla ratio. There is no evidence of focal perinephric inflammation or effusion. There is no evidence of pyelectasia, nephroliths, infarcts or hydronephrosis. Renal vasculature is normal.

**INTERPRETED BY**

Kathleen Sennello DVM,  
MS, Diplomate ACVIM  
(Small Animal Internal  
Medicine)

The right kidney has a normal shape and size (6.35 cm). Overall echogenicity is slightly hyperechoic with poor corticomedullary distinction and a typical 1:3 cortex:medulla ratio. There is no evidence of focal perinephric inflammation or effusion. There is no evidence of pyelectasia, nephroliths, infarcts or hydronephrosis. Renal vasculature is normal.

**IMAGING PERFORMED BY**

Rachel Brillhart RDMS

**Adrenal Glands**

The left adrenal gland is normal in size measuring 0.74 cm at the caudal pole. It is observed in its normal position cranial to the left renal artery. It is normal in appearance (uniformly hypoechoic) and shape with no evidence of a mass effect.

**HOSPITAL NAME**

Healing Paws Vet  
Wellness Center

The right adrenal gland is normal in size measuring 0.66 cm at the caudal pole. It is observed in its normal position between the cranial aspect of the right kidney and the caudal vena cava. It is normal in appearance (uniformly hypoechoic) and shape with no evidence of a mass effect.

**REFERRING VET**

Dr. Levitsky

**Spleen**

The spleen is subjectively normal in size. The spleen echotexture is heterogenous and mottled, the splenic capsule is smooth with no irregularities. The blood flow through the hilus and splenic parenchyma appears normal. There are ill-defined hypoechoic regions/nodules visualized in the spleen.

**INVOICE**

42532

**Liver**

The liver is large in size, and normal in echogenicity with smooth peripheral margins. The parenchyma is heterogenous in echotexture with subtle, indistinct focal mottling. The visible portions of the vasculature and biliary tract appear normal. No focal nodules or cystic lesions are observed.

The gall bladder lumen is moderately distended. The wall of the gall bladder is not thickened and has a smooth mucosal surface. There is a moderate amount of non-organized echogenic debris. The cystic and common bile ducts are normal/not visible.

### ***Gastrointestinal***

The stomach contains minimal luminal contents. It measures at a normal thickness of <0.7cm with some variability due to the presence of rugal folds. The distinction of the gastric wall layers is adequate and there is no impression of reduced peristaltic activity. No masses or focal lesions were observed.

The visualized areas of duodenum, jejunum and ileum have a relatively uniform diameter with minimal fluid distension. Wall thickness is normal. Bowel loops follow a curvilinear path with distinct wall layering maintaining the typical 1:3 muscularis:mucosa layer ratio. Duodenum wall measured 0.52 cm. Jejunum wall measures 0.42 cm. Visualized peristalsis appears appropriate. There were no focal lesions consistent with obstruction or a mass effect observed.

The ileocecal junction was visualized and exhibited normal intact wall layering and is subjectively of normal thickness. Sections of colon are visualized with formed fecal material and gas shadowing distally. There is no observed focal or generalized colon wall thickening or loss of layering.

### ***Pancreas***

The pancreas is normal and isoechoic to surrounding mesentery. There is no evidence of nodules or cystic lesions. There is no evidence of regional mesenteric inflammation or fluid.

### ***Free Abdomen***

Evaluation of the peritoneal cavity did not reveal any evidence of effusion, or subjective lymphadenomegaly. The Medial iliac nodes appear normal and there was no evidence of a caudal aortic thrombus at the bifurcation. The omentum is of normal uniform echogenicity.

### ***Other***

There is a large, mixed echogenic mass effect visualized in the region of the mesenteric root measuring 5.03 cm x 3.17 cm. This could represent an effaced lymph node or primary mass effect. No association with other structures is visualized.

## **ULTRASONOGRAPHIC FINDINGS**

- Mass effect in the apical portion of the urinary bladder – This is most consistent with a transitional cell carcinoma but other differentials such as a blood clot, benign lesion, etc. exist.
- Decreased corticomedullary distinction in both kidneys with very large left-sided cortical cyst – The bilateral renal findings are consistent with age-related change. The cortical cyst is likely benign and asymptomatic at this time.
- Mottled spleen – The diffuse splenic changes are non-specific and could be consistent with lymphoid hyperplasia, extramedullary hematopoiesis, infiltrative neoplasia, inflammation, other. Cytology or histopathology would be necessary to get a definitive diagnosis.
- Large, heterogeneous liver – The diffuse hepatic changes are non-specific and could be consistent with vacuolar hepatopathy, nodular hyperplasia, inflammatory/immune-mediated disease, fibrosis, extramedullary hematopoiesis, toxic hepatopathy (e.g., copper), infiltrative neoplasia (less likely) or other hepatopathy.

- Large, mixed echogenic mass effect at the mesenteric root – Findings are very concerning for a neoplastic lesion. A benign lesion is possible.

## INTERPRETATION OF THE FINDINGS & FURTHER RECOMMENDATIONS

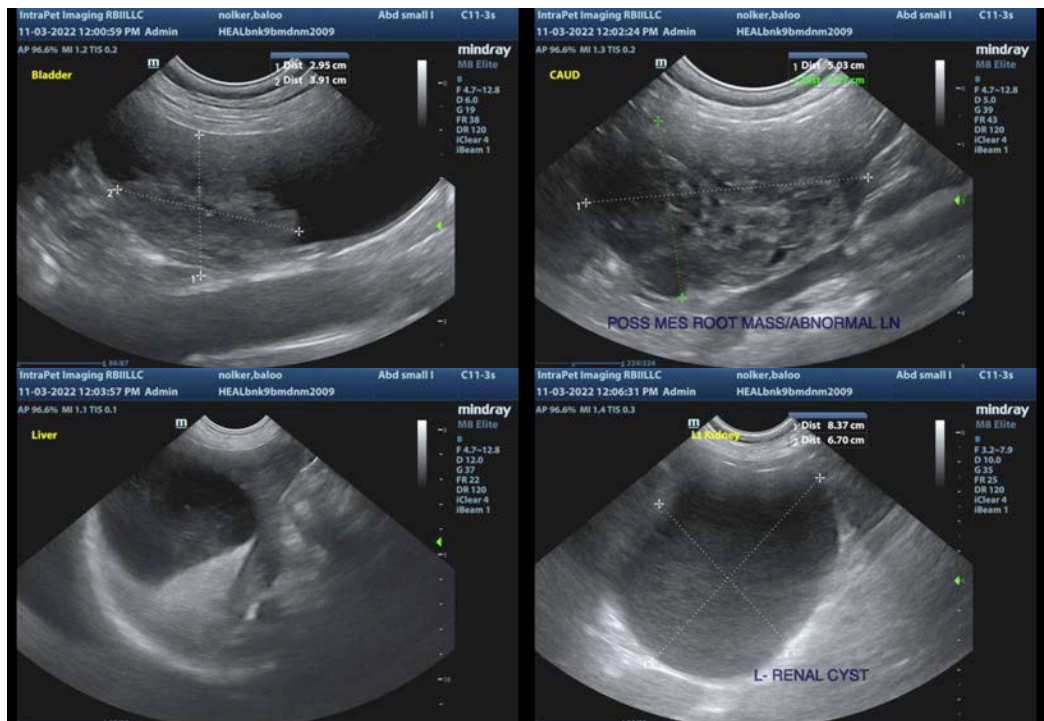
There is a mass effect in the apical portion of the urinary bladder, most consistent with a transitional cell carcinoma. Recommend a traumatic catheterization for cytology as well as a urinalysis and culture.

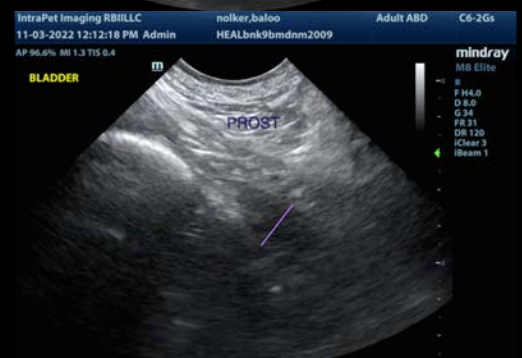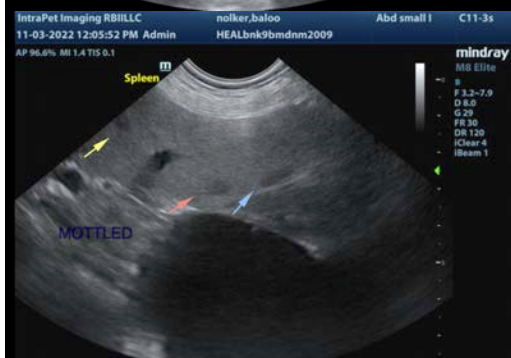
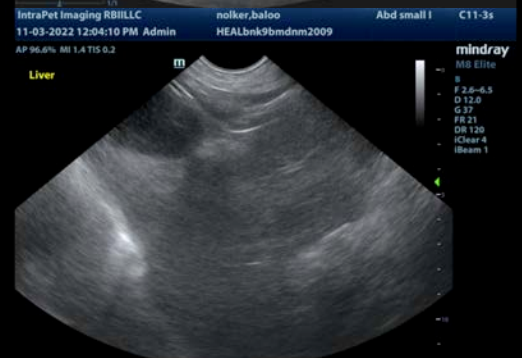
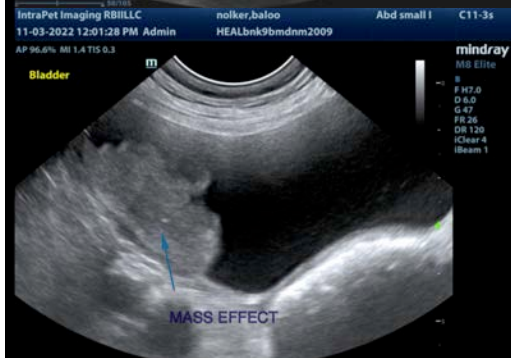
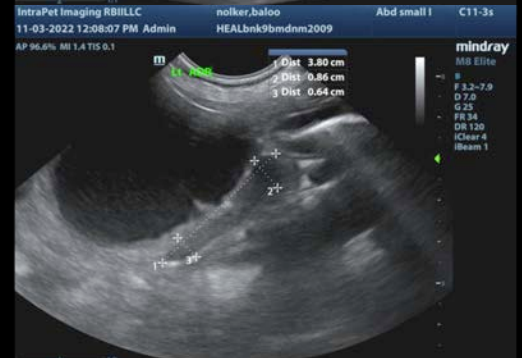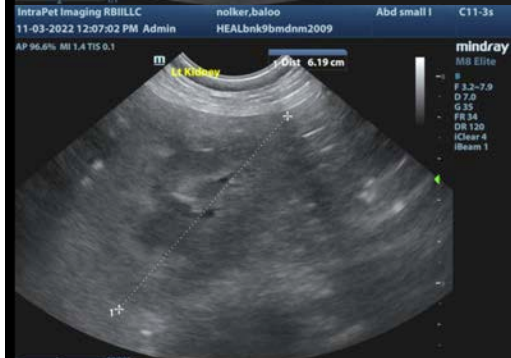
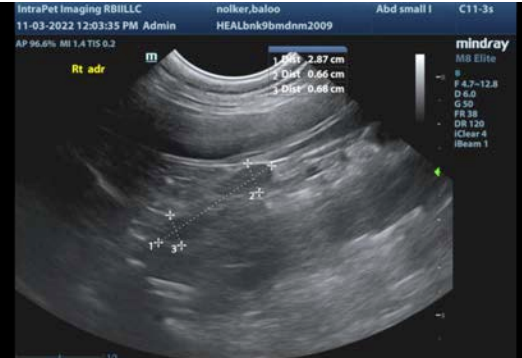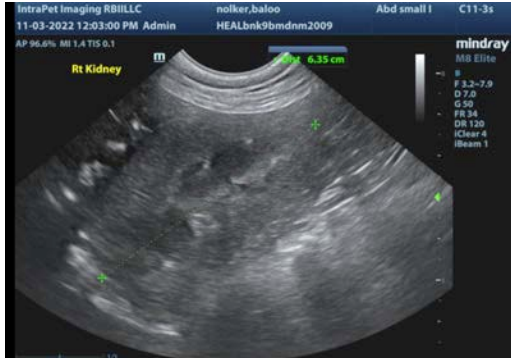There is a mixed echogenic mass effect at the mesenteric root. This is a concerning location, as it could represent a metastatic lymph node, a primary mass effect, etc. I believe this is large enough to be aspirated with caution, but I would initially recommend aspirating the mottled spleen. In this breed, a histiocytic sarcoma would be of primary concern, but other differentials exist.

Recommend three view thoracic radiographs to evaluate for possible concurrent thoracic disease/involvement.

The liver is somewhat heterogeneous. I suspect this age related remodeling, although a fine needle aspirate could be considered.

If cytologic diagnosis cannot be obtained, consider surgical biopsies and consultation with a veterinary oncologist. The apical bladder mass could possibly be removed, but given the concurrent disease process, it is possible that a more conservative approach would be appropriate.





**The information and recommendations provided are based on the images presented by the referring veterinarian/sonographer. No evaluation can be communicated regarding pathology that was not visible in the image/video clips provided.**

Thank you for this referral. If the clinical or image interpretation does not parallel your findings or if I can be of any further assistance please contact me.

Kathleen Sennello DVM,MS, Diplomate ACVIM (Small animal Internal Medicine)  
kathleen.sennello@sonopath.com