

**DATE PRESENTING CLINICAL SIGNS**

11/29/22

Patient presents for evaluation of inappropriate elimination- patient was adopted about two months ago- age is estimated. Labwork showed an increased BUN. Still having inappropriate elimination. R/O medical causes.

PATIENT

Binx Zeglin

Current Medications: None listed.

Lab Results: See attached.

Date of Previous IntraPet Ultrasound: No previous.

Sedation: Not required to complete full diagnostic ultrasound.

Stat Report: Not requested.

SPECIES

Feline

ULTRASONOGRAPHIC EXAMINATION OF THE ABDOMEN**BREED**

DSH

Urinary System

The urinary bladder is moderately distended with mild primarily suspended echogenic debris present. The Bladder wall, trigone, ureteral papillae and visible urethra (to a depth of 2cm) appear normal with no evidence of wall thickening, mucosal irregularities, masses or calculi. Echogenic debris of this type can be associated with small crystals, cellular debris and proteinaceous debris.

SEX

Neutered Male

The left kidney has a normal shape and size (3.54 cm). Overall echogenicity is slightly hyperechoic with poor corticomedullary distinction and a typical 1:3 cortex:medulla ratio. There is no evidence of focal perinephric inflammation or effusion. There is no evidence of pyelectasia, nephroliths, infarcts or hydroureter. Renal vasculature is normal.

AGE

11/16/18

WEIGHT

10 Pounds

The right kidney has a normal shape and size (4.9 cm). Overall echogenicity is slightly hyperechoic with poor corticomedullary distinction and a typical 1:3 cortex:medulla ratio. There is no evidence of focal perinephric inflammation or effusion. There is no evidence of pyelectasia, nephroliths, infarcts or hydroureter. Renal vasculature is normal.

INTERPRETED BY

Kathleen Sennello DVM,
MS, Diplomate ACVIM
(Small Animal Internal
Medicine)

Adrenal Glands

The left adrenal gland is normal in size measuring 0.45 cm at the caudal pole. It is observed in its normal position cranial to the left renal artery. It is normal in appearance (uniformly hypoechoic) and shape with no evidence of a mass effect.

IMAGING PERFORMED BY

Andi Parkinson RDMS

The right adrenal gland is normal in size measuring 0.45 cm at the caudal pole. It is observed in its normal position between the cranial aspect of the right kidney and the caudal vena cava. It is normal in appearance (uniformly hypoechoic) and shape with no evidence of a mass effect.

HOSPITAL NAME

Perry Hall AH

Spleen

The spleen is normal/borderline large (1.2 cm in width at the level of the hilus), echotexture is homogenous, and the splenic capsule is smooth with no irregularities. The blood flow through the hilus and splenic parenchyma appears normal. No focal parenchymal abnormalities are visualized.

REFERRING VET

Dr. Miller

Liver

The liver is subjectively normal in size, and echogenicity with smooth peripheral margins. The parenchyma is homogenous echotexture. The visible portions of the vasculature and biliary tract appear normal. No focal nodules or cystic lesions are observed.

INVOICE

43007

The gall bladder lumen is moderately distended. The wall of the gall bladder is not thickened and has a smooth mucosal surface. There is a mild amount of non-organized echogenic debris. The cystic and common bile ducts are normal/not visible.

Gastrointestinal

The stomach contains minimal luminal contents. It measures at a normal thickness of <0.36cm with some variability due to the presence of rugal folds. The distinction of the gastric wall layers is adequate and there is no impression of reduced peristaltic activity. No masses or focal lesions were observed.

The visualized areas of duodenum, jejunum and ileum have a uniform diameter with minimal fluid distension. Wall thickness is normal to slightly increased. Bowel loops follow a typical curvilinear path with distinct wall layering, but some areas display a prominent muscularis layer which does not display the typical 1:3 muscularis:mucosa layer ratio. Jejunum wall measures 0.27 cm. Visualized peristalsis appears appropriate. There were no focal lesions consistent with obstruction or a mass effect observed.

The ileocecal junction was visualized and exhibited normal intact wall layering and is subjectively of normal thickness. Sections of colon are visualized with formed fecal material and gas shadowing distally. There is no observed focal or generalized colon wall thickening or loss of layering.

Pancreas

The pancreas is prominent and hypoechoic as compared to the surrounding isoechoic mesentery. There is no evidence of nodules or cystic lesions. There is no evidence of regional mesenteric inflammation or fluid.

Free Abdomen

Evaluation of the peritoneal cavity did not reveal any evidence of effusion, or subjective lymphadenomegaly. The Medial iliac nodes appear normal and there was no evidence of a caudal aortic thrombus at the bifurcation. The omentum is of normal uniform echogenicity.

Other

There is a small focal shadowing structure visualized adjacent to the urinary bladder, most consistent with a small shadowing bates body.

There is occasional hyperechoic shadowing associated with the diaphragm, most consistent with ringdown artifact.

PRIMARY FINDINGS

- Decreased corticomedullary distinction in both kidneys – Mild loss of corticomedullary distinction in both kidneys could be consistent with chronic degenerative disease or interstitial nephrosis.
- Hypoechoic, prominent pancreas – The pancreatic changes are most consistent with mild pancreatitis or a recent episode of pancreatic inflammation.
- Prominent muscularis layer to the small intestine – The small intestinal wall changes could be consistent with an underlying inflammatory process. These types of changes can sometimes be seen in normal older cats. Correlate with clinical signs.
- Echogenic debris in the urinary bladder – The echogenic debris in the bladder lumen could be consistent with cells, crystals, and/or mucus.
- Ringdown artifact at the level of the diaphragm – This can be seen associated with pulmonary parenchymal disease. Consider 3-view thoracic radiographs.

SECONDARY FINDINGS

- Borderline large spleen – The spleen appears somewhat plump and irregular. This could be normal for a large cat. If infiltrative disease is suspected, consider a fine needle aspirate of the spleen.

- Small shadowing structure visualized near the urinary bladder – Findings could be consistent with a benign bates body. Correlate with abdominal radiographs.

INTERPRETATION OF THE FINDINGS & FURTHER RECOMMENDATIONS

There is some echogenic debris visualized within the urinary bladder. Recommend a urinalysis and culture (provided this patient has not been on antibiotics within the last week). There are no significant focal lesions visualized, and there is some decreased corticomedullary distinction in the kidneys, which could be consistent with early renal disease. Consider a baseline blood pressure, urinalysis and culture.

The spleen appears slightly irregular and large. This is a large cat, so this could be within normal limits for this individual. Additionally, the pancreas is hypoechoic and prominent. Correlate these findings with a qualitative fPLI level, as these changes could be consistent with previous episodes of pancreatic inflammation or a mild current episode.

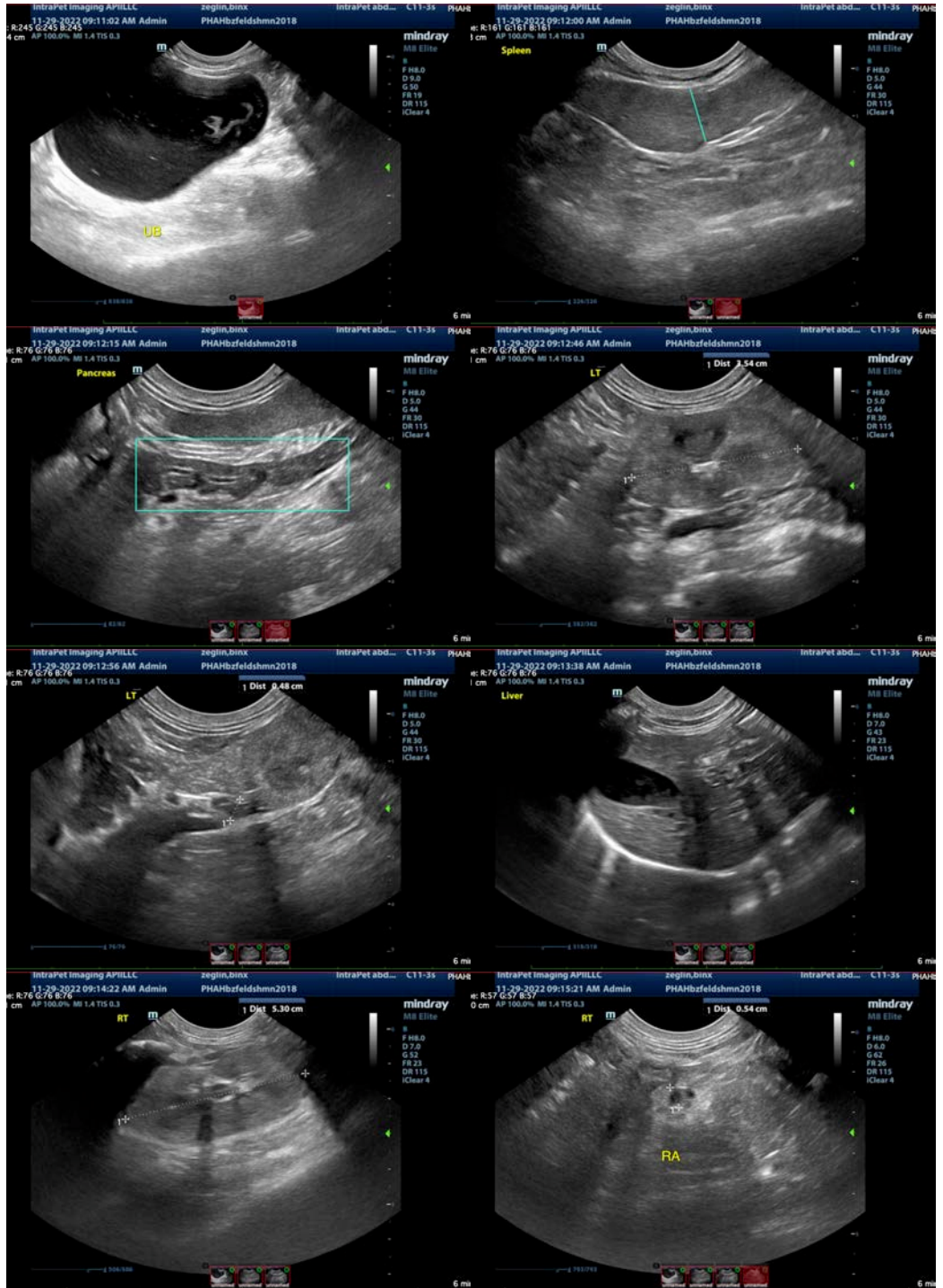
The muscularis layer to the small intestine is somewhat prominent. This can be normal in some older cats or could be associated with underlying gastrointestinal disease. If there is no evidence of underlying GI symptoms, continued monitoring is warranted.

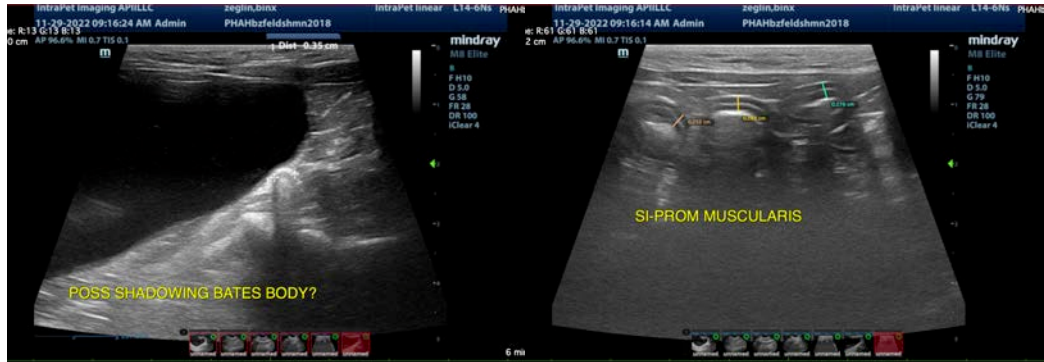
There is a shadowing structure visualized near the urinary bladder. This could be consistent with a benign bates body. Correlate with abdominal radiographs.

Additionally, there is ringdown artifact visualized at the level of the diaphragm. Correlate this with thoracic radiographs.

Many of the reported abnormalities visualized may not be clinically relevant at this time. If no evidence of a urinary tract infection is identified on urine culture, then consider sterile cystitis (although there is no evidence of inflammation on the urinalysis) or behavioral eliminations. These are my recommendations if interstitial cystitis is suspected:

- Urinalysis and culture are recommended.
- Due to the diffuse nature of the lesion, interstitial cystitis is suspected (if culture is negative)
- Treatment of FIC can be frustrating as it is a waxing and waning disease. Treatment strategies vary and there is no “one fits all” approach. There is currently no cure for FIC. Goals of therapy include reduction of severity and duration of clinical signs during an acute episode; increasing the interval between episodes; and decreasing severity of signs in cats with persistent FIC. Approximately 85% of cats will experience clinical improvement with or without therapy.
- Numerous therapies can be considered including: diet, multimodal environmental modification, analgesics, anti-inflammatories, anti-anxiety medications etc..
- Close observation is warranted as some cats do experience life-threatening urinary obstruction.
- If symptoms are worsening re-evaluation with ultrasound should be considered.





The information and recommendations provided are based on the images presented by the referring veterinarian/sonographer. No evaluation can be communicated regarding pathology that was not visible in the image/video clips provided.

Thank you for this referral. If the clinical or image interpretation does not parallel your findings or if I can be of any further assistance please contact me.

Kathleen Sennello DVM,MS, Diplomate ACVIM (Small animal Internal Medicine)
kathleen.sennello@sonopath.com