



PATIENT

Monty Westers

SPECIES

Feline

BREED

DSH

SEX

NM

AGE

11 years 6 months

WEIGHT

4.4 kg

INTERPRETED BY

Kathleen Sennello DVM,
MS, Diplomate ACVIM
(Small Animal Internal
Medicine)

IMAGING PERFORMED BY

Dr. Jill Rankin

HOSPITAL NAME

Southpointe Pet
Hospital

REFERRING VET

Dr. Blaise Callan

INVOICE

10834

DATE

11/27/2025

PRESENTING CLINICAL SIGNS

Hyperthyroid cat, previously stable on methimazole, presenting with a 10-day history of progressive gastrointestinal signs including vomiting, anorexia, and diarrhea. The patient's current clinical concern began approximately 10 days ago with the onset of vomiting and anorexia. Following an initial veterinary visit where a maropitant injection was administered, there was some temporary improvement. However, the patient has since relapsed, and the clinical signs have progressed to include diarrhea for the past three days. Blood work performed recently was reportedly insignificant. Diagnosed with hyperthyroidism in September and was started on methimazole, to which the patient initially responded well. A recent check of thyroid values, conducted as part of the blood work seven days ago, confirmed that the levels were within the normal range.

ULTRASONOGRAPHIC EXAMINATION OF THE ABDOMEN

Urinary System

The urinary bladder is moderately distended with mild primarily suspended echogenic debris present. The Bladder wall, trigone, ureteral papillae and visible urethra (to a depth of 2cm) appear normal with no evidence of wall thickening, mucosal irregularities, masses or calculi. Echogenic debris of this type can be associated with small crystals, cellular debris and proteinaceous debris.

The left kidney has a normal shape and size (3.75 cm). The cortex is of increased echogenicity with adequate corticomedullary distinction and a typical 1:3 cortex:medulla ratio. There is no evidence of focal perinephric inflammation or effusion. There is no evidence of pyelectasia, nephroliths, infarcts or hydroureter. Renal vasculature is normal.

The right kidney has a normal shape and size (3.89 cm). The cortex is of increased echogenicity with adequate corticomedullary distinction and a typical 1:3 cortex:medulla ratio. There is no evidence of focal perinephric inflammation or effusion. There is no evidence of pyelectasia, nephroliths, infarcts or hydroureter. Renal vasculature is normal.

Adrenal Glands

The left adrenal gland is normal in size measuring 0.27 cm at the caudal pole. It is observed in its normal position cranial to the left renal artery. It is normal in appearance (uniformly hypoechoic) and shape with no evidence of a mass effect.

The right adrenal gland is normal in size measuring 0.31 cm at the caudal pole. It is observed in its normal position between the cranial aspect of the right kidney and the caudal vena cava. It is normal in appearance (uniformly hypoechoic) and shape with no evidence of a mass effect.

Spleen

The spleen is subjectively normal in size (0.73 cm), echotexture is homogenous, and the splenic capsule is smooth with no irregularities. The blood flow through the hilus and splenic parenchyma appears normal. No focal parenchymal abnormalities are visualized.

Liver

The liver is subjectively normal in size, and echogenicity with smooth peripheral margins. The parenchyma is homogenous echotexture. The visible portions of the vasculature and biliary tract appear normal. No focal nodules or cystic lesions are observed.



PATIENT

Monty Westers

SPECIES

Feline

BREED

DSH

SEX

NM

AGE

11 years 6 months

WEIGHT

4.4 kg

INTERPRETED BY

Kathleen Sennello DVM,
MS, Diplomate ACVIM
(Small Animal Internal
Medicine)

IMAGING PERFORMED BY

Dr. Jill Rankin

HOSPITAL NAME

Southpointe Pet
Hospital

REFERRING VET

Dr. Blaise Callan

INVOICE

10834

DATE

11/27/2025

The gall bladder lumen is moderately distended. The wall of the gall bladder is not thickened and has a smooth mucosal surface. Luminal contents are mild and likely incidental at this time. The bile duct appears mildly dilated and tortuous measuring at 0.37 cm. No evidence of an obstruction is visualized.

Gastrointestinal

The stomach contains minimal luminal contents. It measures at a normal thickness of 0.27 cm with some variability due to the presence of rugal folds. The distinction of the gastric wall layers is adequate and there is no impression of reduced peristaltic activity. No masses or focal lesions were observed.

The visualized areas of duodenum, jejunum and ileum have a uniform diameter with minimal fluid distension. Wall thickness is normal to slightly increased. Bowel loops follow a typical curvilinear path with distinct wall layering, but some areas display a prominent muscularis layer which does not display the typical 1:3 muscularis:mucosa layer ratio. The duodenum measured 0.27 cm in diameter and the jejunum measured 0.23 cm in diameter. Visualized peristalsis appears appropriate. There were no focal lesions consistent with obstruction or a mass effect observed.

The ileocecal junction was visualized and exhibited normal intact wall layering and is subjectively of normal thickness. Sections of colon are visualized with non-formed fecal material and gas shadowing distally. Transverse colon wall is prominent measuring 0.21 cm with intact wall layering.

Pancreas

The pancreas is large and hypoechoic to surrounding mesentery. There is no evidence of nodules or cystic lesions. There is evidence of regional mesenteric inflammation. Consistent with mild pancreatitis.

Free Abdomen

Evaluation of the peritoneal cavity revealed scant free fluid. There is a mild/moderate diffuse lymphadenopathy, particularly at the ileocecal junction where there are lymph nodes measuring 0.67 cm, 0.42 cm, and 1.0 cm in diameter. A lymph node medial to the spleen is prominent measuring 0.39 cm. The omentum is diffusely hyperechoic in these regions.

ULTRASONOGRAPHIC FINDINGS

- Suspended echogenic debris in the urinary bladder. The echogenic debris in the bladder lumen could be consistent with cells, crystals, and/or mucus. Recommend urinalysis and culture
- Hypoechoic, mottled pancreas. Findings are most consistent with mild chronic pancreatitis.
- Inflammatory type pattern visualized associated with the small intestine with some areas exhibiting a slightly prominent muscularis layer. The small intestinal wall changes are most consistent with an inflammatory process (i.e., inflammatory bowel disease) with a low possibility of emerging lymphoma
- Mild/moderate mesenteric lymphadenopathy, particularly at the ileocecal junction where there is focal inflammation. Findings are most consistent with highly reactive or early neoplastic lymph nodes.

INTERPRETATION OF THE FINDINGS & FURTHER RECOMMENDATIONS



PATIENT

Monty Westers

SPECIES

Feline

BREED

DSH

SEX

NM

AGE

11 years 6 months

WEIGHT

4.4 kg

INTERPRETED BY

Kathleen Sennello DVM,
MS, Diplomate ACVIM
(Small Animal Internal
Medicine)

**IMAGING
PERFORMED BY**

Dr. Jill Rankin

HOSPITAL NAME

Southpointe Pet
Hospital

REFERRING VET

Dr. Blaise Callan

INVOICE

10834

DATE

11/27/2025

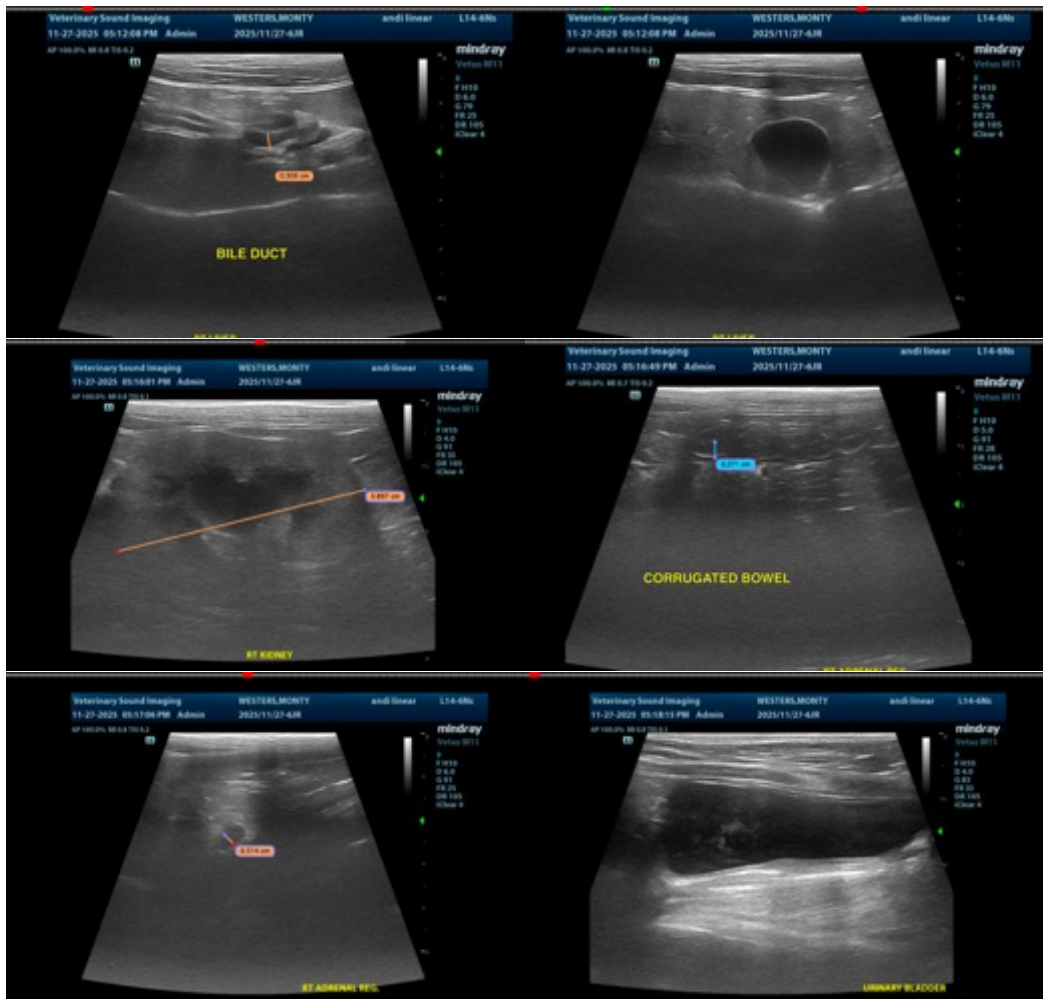
Generally, the changes observed involving the small intestine and lymph nodes are most consistent with an inflammatory type change/IBD type pattern. Early neoplastic change cannot be ruled out.

Additionally, the pancreas is prominent, hypoechoic and mottled with some regional inflammation, possibly consistent with chronic active pancreatitis. Consider the following:

- Recommend an ultra low fat/hydrolyzed protein prescription diet.
- Consider a GI panel to Texas A&M for evaluation of B12 levels, folate, PLI/TLI etc.. to further evaluate for pancreatic/small intestinal disease.
- Recommend chronic probiotic therapy.

Recommend non-specific therapy for pancreatitis. If symptoms are persistent, biopsies of the GI tract may be necessary to further evaluate.

Additionally, consider repeat imaging in the future looking for progressive enlargement of the mesenteric lymph nodes as a fine needle aspirate may eventually be considered.





PATIENT

Monty Westers

SPECIES

Feline

BREED

DSH

SEX

NM

AGE

11 years 6 months

WEIGHT

4.4 kg

INTERPRETED BY

Kathleen Sennello DVM,
MS, Diplomate ACVIM
(Small Animal Internal
Medicine)

**IMAGING
PERFORMED BY**

Dr. Jill Rankin

HOSPITAL NAME

Southpointe Pet
Hospital

REFERRING VET

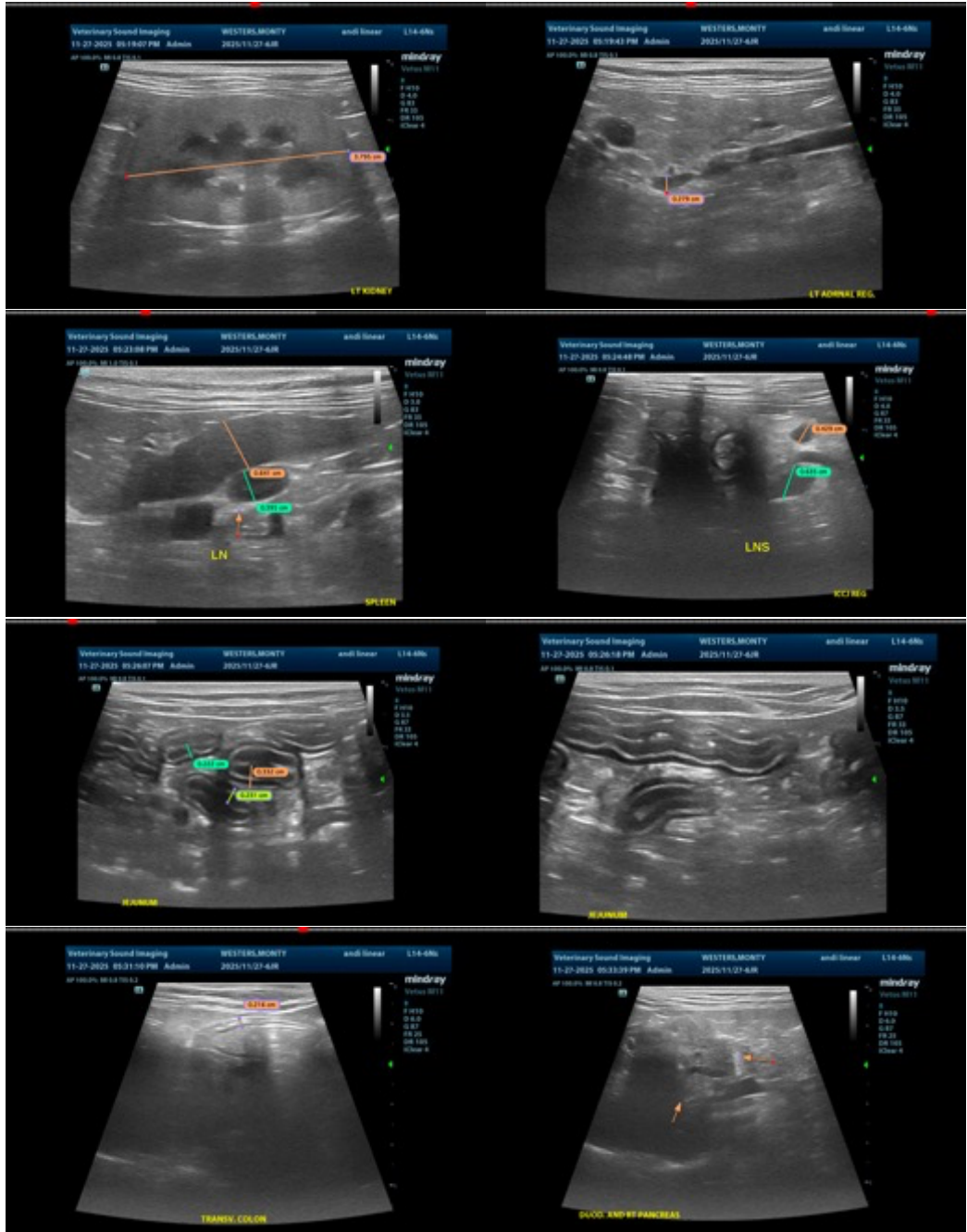
Dr. Blaise Callan

INVOICE

10834

DATE

11/27/2025



The information and recommendations provided are based on the images presented by the referring veterinarian/sonographer. No evaluation can be communicated regarding pathology that was not visible in the image/video clips provided.

Thank you for this referral. If the clinical or image interpretation does not parallel your findings or if I can be of any further assistance please contact me.

Kathleen Sennello DVM,MS, Diplomate ACVIM (Small animal Internal Medicine). info@sonopath.com