



DATE PRESENTING CLINICAL SIGNS

11/26/25

Patient History: Continued weight loss. Recent DDx IRIS Stage 2 CKD. Attempted to transition to renal diets and fish oil. Pet will not eat renal diets. Recheck of bloodwork reveals progression of renal values and now elevation in liver values. Concern for possible underlying cause.

PATIENT

Leo Lanham

Current Medications: None at this time.

Labwork Results: SDMA: 20 (previously 20) Crea: 2.3 (previously 1.7). BUN: 33 (previously 39). Phos normal. Urine SG: 1.015, ALT: 234 (previously 109). AST: 73, ALKP: 62, Mild anemia (HCT 30%)

SPECIES

Date of Previous IntraPet Ultrasound: No previous.

Feline

Sedation: IV.

Stat Report: Not requested.

BREED

Imaging Performed by: Rachel Brillhart, RDMS.

DLH

ULTRASONOGRAPHIC EXAMINATION OF THE ABDOMEN

SEX

Urinary System

The urinary bladder is moderately distended with anechoic urine. The Bladder wall, trigone, ureteral papillae and visible urethra (to a depth of 2cm) appear normal with no evidence of wall thickening, mucosal irregularities, masses or cystic calculi.

Neutered Male

AGE

The left kidney has a normal shape and size (3.97 cm) with pyelectasia at 0.57 cm. The cortex is of increased echogenicity, with poor corticomedullary distinction and a typical 1:3 cortex:medulla ratio. There is no evidence of focal perinephric inflammation or effusion. There is no evidence of nephroliths, infarcts or hydroureter. Renal vasculature is normal.

1/1/10

WEIGHT

The right kidney has a normal shape and size (4.11 cm) with pyelectasia at 0.32 cm. The cortex is of increased echogenicity, with poor corticomedullary distinction and a typical 1:3 cortex:medulla ratio. There is no evidence of focal perinephric inflammation or effusion. There is no evidence of nephroliths, infarcts or hydroureter. Renal vasculature is normal.

12.3 lbs

INTERPRETED BY

Kathleen Sennello DVM,
MS, Diplomate ACVIM
(Small Animal Internal
Medicine)

HOSPITAL NAME

Timonium Animal
Hospital

Adrenal Glands

The left adrenal gland is normal in size measuring 0.50 cm at the caudal pole. It is observed in its normal position cranial to the left renal artery. It is normal in appearance (uniformly hypoechoic) and shape with no evidence of a mass effect.

REFERRING VET

Dr. McMichael

The right adrenal gland is normal in size measuring 0.51 cm at the caudal pole. It is observed in its normal position between the cranial aspect of the right kidney and the caudal vena cava. It is normal in appearance (uniformly hypoechoic) and shape with no evidence of a mass effect.

Spleen

The spleen is subjectively normal in size (0.84 cm), echotexture is homogenous, and the splenic capsule is smooth with no irregularities. The blood flow through the hilus and splenic parenchyma appears normal. No focal parenchymal abnormalities are visualized.

INVOICE

72158

Liver

The liver is subjectively large in size, and subjectively mildly hyperechoic with smooth peripheral margins. The parenchyma is mildly heterogenous in echotexture with subtle, indistinct focal mottling. The visible portions of the vasculature and biliary tract appear normal. No focal nodules or cystic lesions are observed.

The gall bladder lumen is moderately distended. The wall of the gall bladder is not thickened and has a smooth mucosal surface. Luminal contents are mild and likely incidental at this time. The cystic and common bile ducts are normal/not visible.

Gastrointestinal

The stomach contains minimal luminal contents. It measures at a normal thickness of <0.36cm with some variability due to the presence of rugal folds. The distinction of the gastric wall layers is adequate and there is no impression of reduced peristaltic activity. No masses or focal lesions were observed.

The visualized areas of duodenum, jejunum and ileum have a uniform diameter with minimal fluid distension. Wall thickness is normal to slightly increased. Bowel loops follow a typical curvilinear path with distinct wall layering, but some areas display a prominent muscularis layer which does not display the typical 1:3 muscularis:mucosa layer ratio. Duodenum wall measures 0.22 cm. Jejunum wall measures 0.21 cm. Visualized peristalsis appears appropriate. There were no focal lesions consistent with obstruction or a mass effect observed.

The ileocecal junction was visualized and exhibited normal intact wall layering and is subjectively of normal thickness. Sections of colon are visualized with formed fecal material and gas shadowing distally. There is no observed focal or generalized colon wall thickening or loss of layering.

Pancreas

The right limb of the pancreas is prominent and hypoechoic as compared to the surrounding isoechoic mesentery. There is no evidence of nodules or cystic lesions. There is no evidence of regional mesenteric inflammation or fluid.

Free Abdomen

Evaluation of the peritoneal cavity did not reveal any evidence of effusion, or subjective lymphadenomegaly. The Medial iliac nodes appear normal and there was no evidence of a caudal aortic thrombus at the bifurcation. The omentum is of normal uniform echogenicity.

ULTRASONOGRAPHIC FINDINGS

- Hyperechoic kidneys with decreased corticomedullary distinction and bilateral pyelectasia – Mild loss of corticomedullary distinction in both kidneys could be consistent with chronic degenerative disease or interstitial nephrosis. Pyelectasia of the kidney(s) could be consistent with pyelonephritis, chronic renal disease, secondary to PU/PD or fluid therapy (if applicable), other.
- Pancreatic changes most consistent with chronic pancreatic remodeling/chronic active pancreatitis.
- Prominent/mildly hyperechoic liver – Hepatic changes are non-specific and could be consistent with hepatic lipidosis, inflammatory/infectious disease, infiltrative neoplasia, or other hepatopathy.
- “Ropey” small intestine with some areas exhibiting a mildly thickened/prominent muscularis layer – The small intestinal wall changes are most consistent with an inflammatory process (i.e., inflammatory bowel disease) with a low possibility of emerging lymphoma.

INTERPRETATION OF THE FINDINGS & FURTHER RECOMMENDATIONS

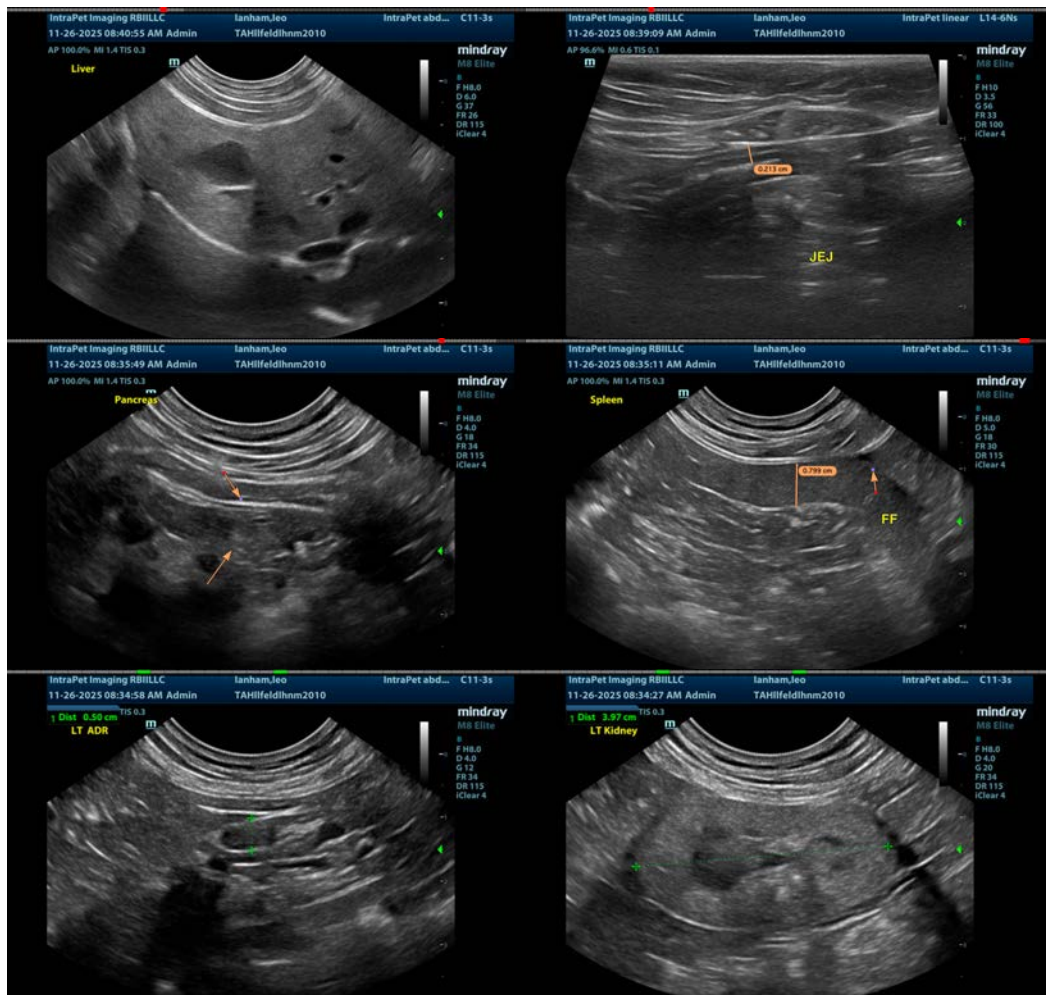
Both kidneys have changes consistent with chronic renal disease. Given the significant pyelectasia present, recommend a urine culture and potentially treatment for pyelonephritis.

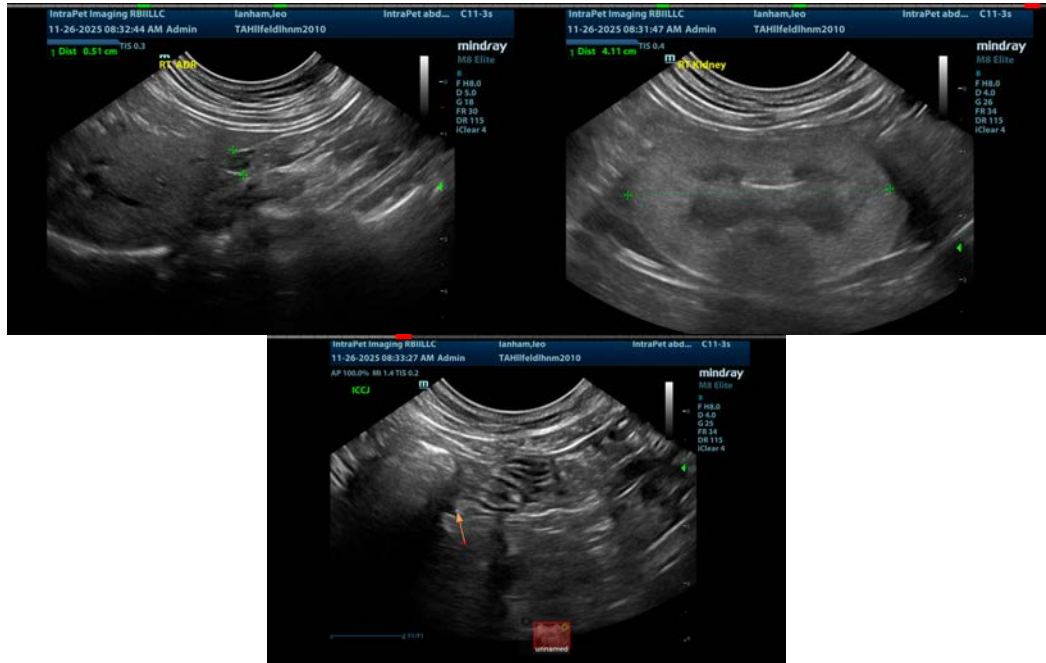
The right limb of the pancreas is prominent and hypoechoic, most consistent with pancreatic remodeling, but mild concurrent inflammation is possible. Correlate with PLI level and consider concurrent treatment for pancreatitis if clinically appropriate.

The small intestine is somewhat “ropey” with some areas exhibiting a very mildly prominent muscularis layer. These changes could be consistent with mild inflammatory type change.

The combination of liver enzyme elevations, mild gastrointestinal changes, and pancreatic changes could be consistent with mild Triaditis. Consider a GI panel to Texas A&M for a qualitative fPLI, TLI, cobalamin and folate, as this may help to better determine if underlying gastrointestinal disease is present and if further evaluation is warranted.

The elevation in liver enzymes could be due to a primary hepatopathy, a mild reactive lymphadenopathy secondary to pancreatic inflammation, etc. If liver enzyme elevations are persistent, options would include a liver function test (pre- and post-prandial bile acids) and a fine needle aspirate of the liver (provided coagulation parameters are normal).





The information and recommendations provided are based on the images presented by the referring veterinarian/sonographer. No evaluation can be communicated regarding pathology that was not visible in the image/video clips provided.

Thank you for this referral. If the clinical or image interpretation does not parallel your findings or if I can be of any further assistance please contact me.

Kathleen Sennello DVM,MS, Diplomate ACVIM (Small animal Internal Medicine)
info@sonopath.com