**DATE**

11/26/21

PRESENTING CLINICAL SIGNS

11-23-2021 Notes: Saw rDVM this morning for recheck of GI issues; referred for continued care. Hx from owner: Last week went to ER for vomiting and diarrhea. Had fecal; owner thinks was positive for parasites. Had treatments and went home but had to go back 2 days later (?) and stay overnight. Was not dewormed when there; sent home w/dewormer and advised to give to her after she had not vomited for 4 days, but she started vomiting again today. Went to rDVM; had x-rays. Referred for continued care. On PE slightly dehydrated Painful upon palpation of abdomen (vocalized when palpated)

PATIENT

Olive Woron

SPECIES

Canine

Current Medications: Metronidazole, sucralfate, bene-pac, metocloperamide, fenbendazole

BREED

Pitbull Mix

Lab Results: Attached.

Radiographs: stomach is gas distended, no obvious fb, but also has one gas pocket-- possible SI, one appears to be cecum

SEX

Female

Date of Previous IntraPet Ultrasound: No previous.

Sedation: Not required to complete full diagnostic ultrasound.

Stat Report: Not requested.

AGE

3.52 lbs

ULTRASONOGRAPHIC EXAMINATION OF THE ABDOMEN**Urinary System**

The urinary bladder is moderately distended with anechoic urine. The Bladder wall, trigone, ureteral papillae and visible urethra (to a depth of 2cm) appear normal with no evidence of wall thickening, mucosal irregularities, masses or cystic calculi.

The left kidney has a normal shape and size (3.65 cm). Overall echogenicity is normal with adequate corticomedullary distinction and a typical 1:3 cortex:medulla ratio. There is no evidence of perinephric inflammation or effusion. There is no evidence of pyelectasia, nephroliths, infarcts or hydroureter. Renal vasculature is normal.

The right kidney has a normal shape and size (3.96 cm). Overall echogenicity is normal with adequate corticomedullary distinction and a typical 1:3 cortex:medulla ratio. There is no evidence of perinephric inflammation or effusion. There is no evidence of pyelectasia, nephroliths, infarcts or hydroureter. Renal vasculature is normal.

INTERPRETED BY

Kathleen Sennello
DVM, MS, Diplomate
ACVIM (Small Animal
Internal Medicine)

IMAGING PERFORMED BY

Andi Parkinson RDMS

HOSPITAL NAME

Animal Emergency
Hospital

REFERRING VET

Dr. Martinoli

Adrenal Glands

The left adrenal gland is normal in size measuring 0.35 cm at the caudal pole It is observed in its normal position cranial to the left renal artery. It is normal in appearance (uniformly hypoechoic) and shape with no evidence of a mass effect.

The right adrenal gland is normal in size measuring 0.42 cm at the caudal pole It is observed in its normal position between the cranial aspect of the right kidney and the caudal vena cava. It is normal in appearance (uniformly hypoechoic) and shape with no evidence of a mass effect.

Spleen

The spleen is subjectively normal in size, echotexture is homogenous, and the splenic capsule is smooth with no irregularities. The blood flow through the hilus and splenic parenchyma appears normal. No focal parenchymal abnormalities are visualized.

INVOICE

94132

Liver

The liver is subjectively normal in size, and echogenicity with smooth peripheral margins. The parenchyma is homogenous echotexture. The visible portions of the vasculature and biliary tract appear normal. No focal nodules or cystic lesions are observed. The gallbladder lumen is moderately distended. The wall of the gallbladder is not thickened and has a smooth mucosal surface. Luminal contents are primarily anechoic. The cystic and common bile ducts are normal/not visible.

Gastrointestinal

The stomach is moderately dilated with fluid and irregular shadowing material most consistent with normal ingesta and gas. It measures at a maximal thickness of <0.7cm with some variability due to the presence of rugal folds. The distinction of the gastric wall layering is adequate and there is no impression of reduced peristaltic activity. No masses or focal lesions were observed.

Many of the visualized areas of duodenum, jejunum and ileum have a relatively uniform diameter with minimal fluid distension. Some other areas appear to have shadowing ingesta and mild fluid distension. The wall thickness appears normal. The bowel loops typically follow a curvilinear path with distinct wall layering maintaining a full 1:3 muscularis:mucosa ratio. The duodenum measured as normal (between 0.3-0.5cm in wall thickness) and the jejunum measured as normal (between 0.2-0.47cm.) Visualized peristalsis appears appropriate. There were no focal lesions consistent with obstruction or a mass effect observed, but there are may areas of shadowing ingesta and fluid dilation making it difficult to rule out the possibility of obstructive foreign material.

The ileocecal junction was visualized and exhibited normal intact wall layering and is subjectively of normal thickness. Many areas of the colon are fluid distended shadowing liquid fecal material and gas. There is no observed focal or generalized colon wall thickening or loss of layering.

Pancreas

The pancreas is prominent and hypoechoic as compared to the surrounding isoechoic mesentery. There is no evidence of nodules or cystic lesions. There is no evidence of regional mesenteric inflammation or fluid.

Free Abdomen

There are scant triangles of anechoic free fluid visualized. No lymphadenopathy is noted and the omentum is generally of normal echogenicity.

ULTRASONOGRAPHIC FINDINGS

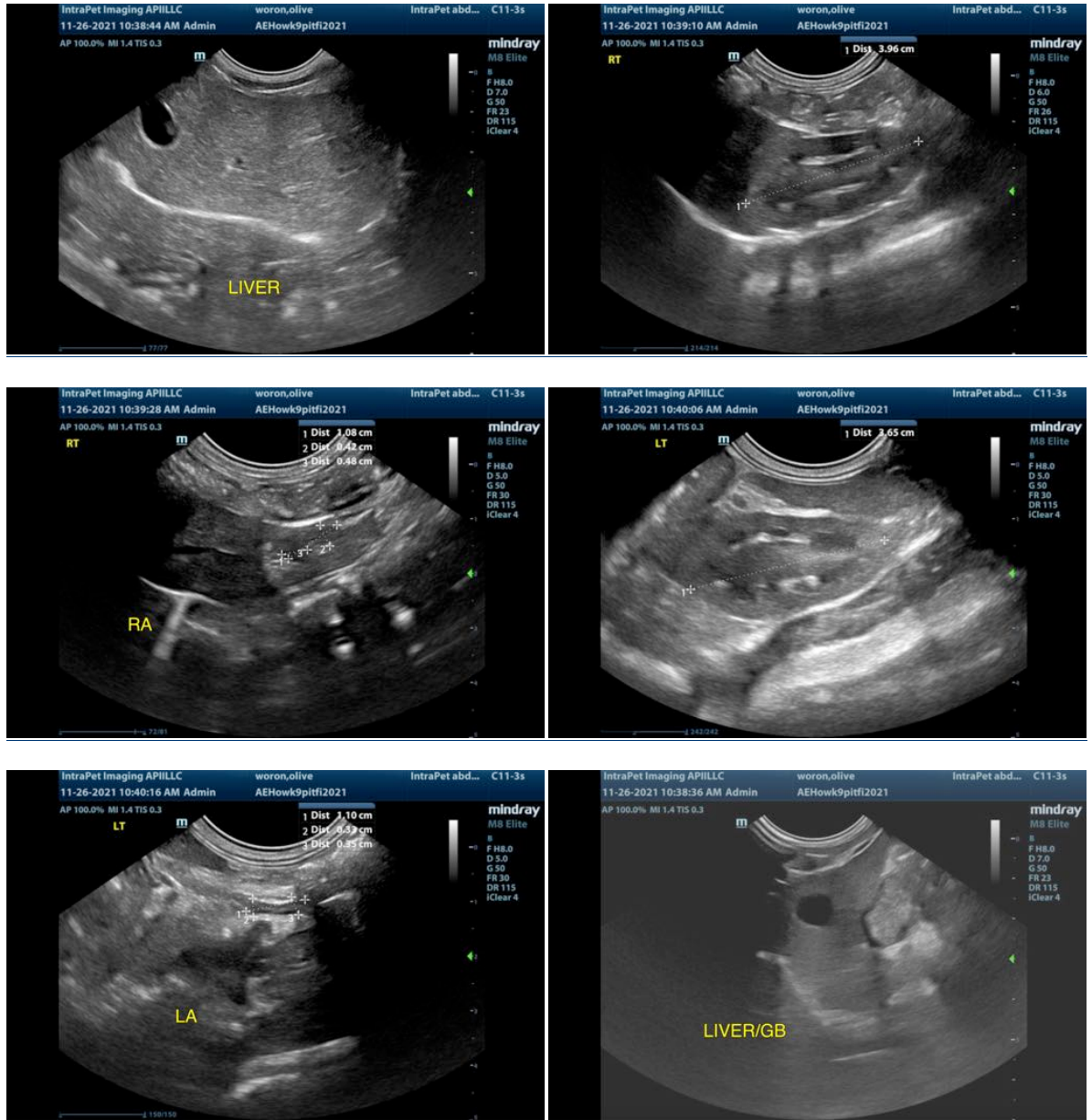
PRIMARY FINDINGS:

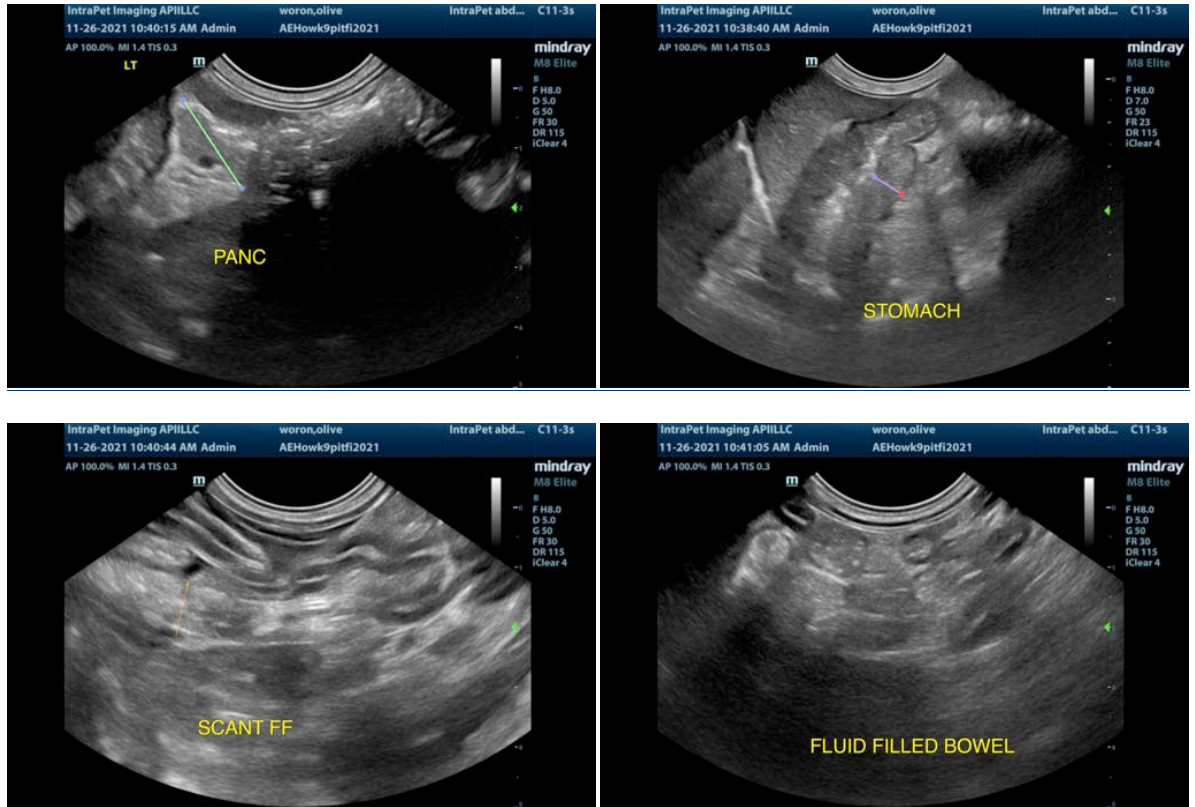
- Hypoechoic, prominent pancreas. The pancreatic changes are most consistent with mild pancreatitis or a recent episode of pancreatic inflammation.
- Diffuse fluid dilation of small bowel and colon with shadowing ingesta an foreign material. The findings are most consistent with enteritis, but obstructive foreign material cannot be definitively ruled out.

INTERPRETATION OF THE FINDINGS & FURTHER RECOMMENDATIONS

The appearance of the abdomen is most consistent with a diffuse enteritis with distension of the large bowel and areas of the small bowel. Unfortunately there is shadowing material present and obstruction or partial

obstruction cannot be definitively ruled out. I recommend medical treatment for enteritis (viral, parasitic, dietary indiscretion, etc) and close monitoring clinically and with imaging (radiographs +/- ultrasound). If there is concern for lack of improvement or worsening then consider exploratory to rule out a foreign body/foreign material. I recommend Parvo testing, fecal analysis and baseline cortisol if clinically appropriate.





The information and recommendations provided are based on the images presented by the referring veterinarian. No evaluation can be communicated regarding pathology that was not visible in the image/video clips provided.

Thank you for this referral. If the clinical or image interpretation does not parallel your findings or if I can be of any further assistance please contact me.

Kathleen Sennello DVM,MS, Diplomate ACVIM (Small animal Internal Medicine)
kathleen.sennello@sonopath.com