



**PATIENT**

Brody Keogh

**PRESENTING CLINICAL SIGNS**

Renal disease and pancreatitis. Current meds: IVF, Cerenia, famotadine, unasyn, and metronidazole.

**SPECIES**

Canine

**ULTRASONOGRAPHIC EXAMINATION OF THE ABDOMEN**

**Urinary System**

The urinary bladder is moderately distended with anechoic urine. The Bladder wall, trigone, ureteral papillae and visible urethra (to a depth of 2cm) appear normal with no evidence of wall thickening, mucosal irregularities, masses or cystic calculi.

**BREED**

Chihuahua

The prostate is normal in size (0.66 cm) and shape for this neutered male dog. The parenchyma is homogenous and the external margins are smooth. The prostatic urethra appears normal with no evidence of irregularity, invasion, mass effect or calculi.

**SEX**

Neutered Male

The left kidney has a normal shape and size (3.62 cm). Overall echogenicity is slightly hyperechoic with poor corticomedullary distinction and a typical 1:3 cortex:medulla ratio. There is no evidence of perinephric inflammation or effusion. There is no evidence of pyelectasia, nephroliths, infarcts or hydroureter. Renal vasculature is normal.

**AGE**

15 Years

The right kidney has a normal shape and size (3.28 cm). Overall echogenicity is slightly hyperechoic with poor corticomedullary distinction and a typical 1:3 cortex:medulla ratio. There is no evidence of perinephric inflammation or effusion. There is no evidence of pyelectasia, nephroliths, infarcts or hydroureter. Renal vasculature is normal.

**WEIGHT**

7.7 Pounds

**Adrenal Glands**

The left adrenal gland is normal in size measuring 0.49 cm at the caudal pole. It is observed in its normal position cranial to the left renal artery. It is normal in appearance (uniformly hypoechoic) and shape with no evidence of a mass effect.

The right adrenal gland is normal in size measuring 0.55 cm at the caudal pole. It is observed in its normal position between the cranial aspect of the right kidney and the caudal vena cava. It is normal in appearance (uniformly hypoechoic) and shape with no evidence of a mass effect.

**INTERPRETED BY**

Kathleen Sennello DVM,  
MS, Diplomate ACVIM  
(Small Animal Internal  
Medicine)

**IMAGING PERFORMED BY**

Kelly Vazquez

**HOSPITAL NAME**

Westwood Regional

**Spleen**

The spleen is subjectively normal in size, echotexture is homogenous, and the splenic capsule is smooth with no irregularities. The blood flow through the hilus and splenic parenchyma appears normal. No focal parenchymal abnormalities are visualized.

**Liver**

The liver is subjectively normal in size, and echogenicity with smooth peripheral margins. The parenchyma is homogenous echotexture. The visible portions of the vasculature and biliary tract appear normal. No focal nodules or cystic lesions are observed.

**REFERRING VET**

Dr. Taylor McConnell

**INVOICE**

33102

The gallbladder lumen is significantly distended. The majority of the wall appears thickened and hypoechoic with a large amount of adherent debris. Some of this debris has early organization, consistent with an early gallbladder mucocele. There is inflammation surrounding the area of the gallbladder, and no evidence of bile duct dilation.

**DATE**

11/26/21



**PATIENT**

***Gastrointestinal***

Brody Keogh

The stomach contains minimal luminal contents. It measures at a normal thickness of <0.7cm with some variability due to the presence of rugal folds. The distinction of the gastric wall layers is adequate and there is no impression of reduced peristaltic activity. No masses or focal lesions were observed.

**SPECIES**

Canine

The visualized areas of duodenum, jejunum and ileum have a uniform diameter with minimal fluid distension. Wall appears subjectively, mildly increased. Bowel loops follow a typical curvilinear path with distinct wall layering. Visualized peristalsis appears appropriate. There were no focal lesions consistent with obstruction or a mass effect observed. Duodenum wall measured 0.35 cm. Jejunum wall measured 0.29 cm.

**BREED**

Chihuahua

The ileocecal junction was visualized and exhibited normal intact wall layering and is subjectively of normal thickness. Sections of colon are visualized with formed fecal material and gas shadowing distally. There is no observed focal or generalized colon wall thickening or loss of layering.

**SEX**

Neutered Male

***Pancreas***

The pancreas is enlarged, irregular and hypoechoic as compared to the surrounding hyperechoic mesentery. It appears very solid and somewhat mass like, and caudally it appears to become a more discreet mass effect, measuring approximately 3.67 cm x 2.9 cm. There is a large amount of regional inflammation surrounding this mass effect, but no free fluid. Suspect mass effect is of pancreatic origin (cannot rule out spleen).

**AGE**

15 Years

**WEIGHT**

7.7 Pounds

***Free Abdomen***

No free fluid. There is a cranial mesenteric lymphadenopathy present with a gastric lymph node measuring approximately 1.05 cm in diameter. The omentum is hyperechoic and inflamed, particularly in the area around the gallbladder and pancreas/pancreatic mass.

**INTERPRETED BY**

Kathleen Sennello DVM,  
MS, Diplomate ACVIM  
(Small Animal Internal  
Medicine)

**IMAGING  
PERFORMED BY**

Kelly Vazquez

**HOSPITAL NAME**

Westwood Regional

**REFERRING VET**

Dr. Taylor McConnell

**PRIARY FINDINGS**

- Large, inflamed, irregular, hypoechoic caudal abdominal mass – This mass appears to extend from abnormal pancreatic tissue. Suspect pancreatic mass, but cannot exclude the possibility of a splenic mass or lymph node.
- Large distended gallbladder with thickened wall – consistent with gallbladder mucocele and secondary inflammation.
- Subjectively thickened small intestine – The mild small intestinal wall changes may be a normal variant in this patient or could be consistent with an inflammatory process (e.g., inflammatory bowel disease).
- Enlarged cranial abdominal lymph nodes – These changes could be consistent with inflammation, infection, or a neoplastic change.

**SECONDARY FINDINGS**

- Decreased corticomedullary distinction in both kidneys – Mild loss of corticomedullary distinction in both kidneys could be consistent with chronic degenerative disease or interstitial nephrosis.

**INVOICE**

33102

**DATE**

11/26/21

**INTERPRETATION OF THE FINDINGS & FURTHER RECOMMENDATIONS**

There is a large caudal abdominal mass that appears very inflamed and appears to extend from the area of the pancreas. Primary differential is pancreatic neoplasia. Consider fine needle aspirate of this mass effect.



**PATIENT**

Brody Keogh

Additionally, the gallbladder appears thickened and enlarged, and there is inflammation surrounding the gallbladder. Some of this reactivity could also be due to the pancreatic mass, but correlate with bloodwork findings, as this could be an early surgical gallbladder. Recommend 3-view thoracic radiographs to look for evidence of metastasis and to evaluate for concurrent intrathoracic disease. Options moving forward include:

**SPECIES**

Canine

- Fine needle aspirate of the abdominal mass to obtain more information. Pancreatic carcinoma would carry a very guarded prognosis, and complete surgical resection would be unlikely.
- You could consider advanced imaging (CT scan with contrast) of the abdomen to further evaluate the abdominal mass and the gallbladder.
- You could also consider referral to a veterinary surgeon for gallbladder removal and biopsy/removal of the abdominal mass. There is concern if this of pancreatic origin that removal may not be a viable option.
- If a diagnosis can be made regarding the abdominal mass, consider consultation with a veterinary oncologist regarding surgical and chemotherapeutic options.

**BREED**

Chihuahua

**SEX**

Neutered Male

Recommend antibiotics for the gallbladder +/- Ursodiol and close monitoring. It is difficult to say if this patient is not feeling well due to the mass effect, gallbladder, or both.

**AGE**

15 Years

**WEIGHT**

7.7 Pounds

**INTERPRETED BY**

Kathleen Sennello DVM, MS, Diplomate ACVIM (Small Animal Internal Medicine)

**IMAGING PERFORMED BY**

Kelly Vazquez

**HOSPITAL NAME**

Westwood Regional

**REFERRING VET**

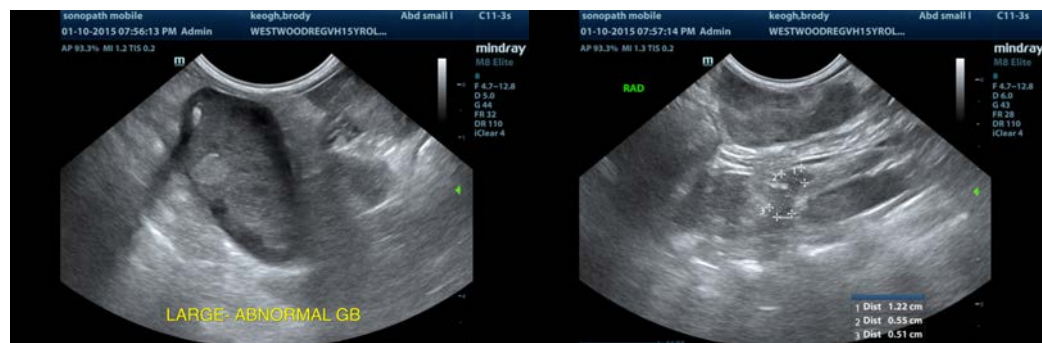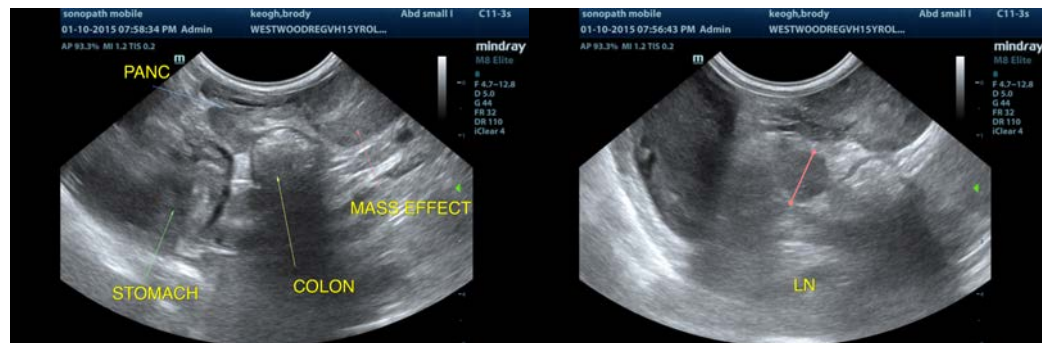
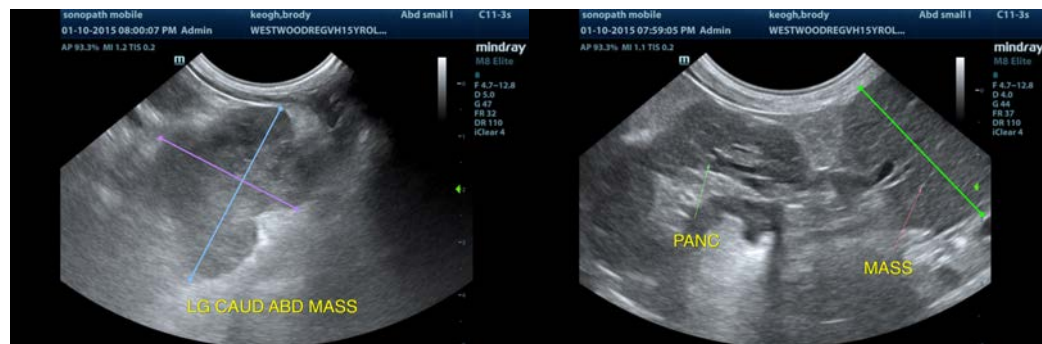
Dr. Taylor McConnell

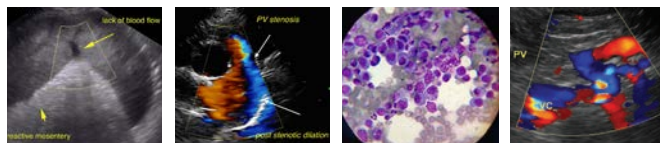
**INVOICE**

33102

**DATE**

11/26/21





**PATIENT**

Brody Keogh

**SPECIES**

Canine

**BREED**

Chihuahua

**SEX**

Neutered Male

**AGE**

15 Years

**WEIGHT**

7.7 Pounds

**INTERPRETED BY**

Kathleen Sennello DVM,  
MS, Diplomate ACVIM  
(Small Animal Internal  
Medicine)

**IMAGING  
PERFORMED BY**

Kelly Vazquez

**HOSPITAL NAME**

Westwood Regional

**REFERRING VET**

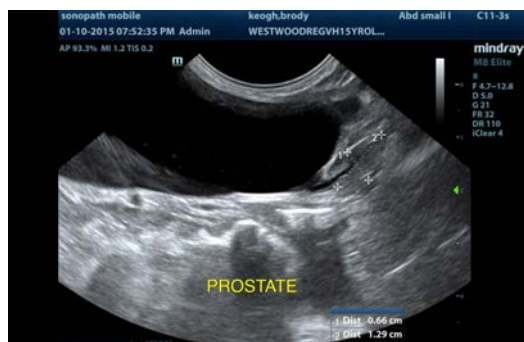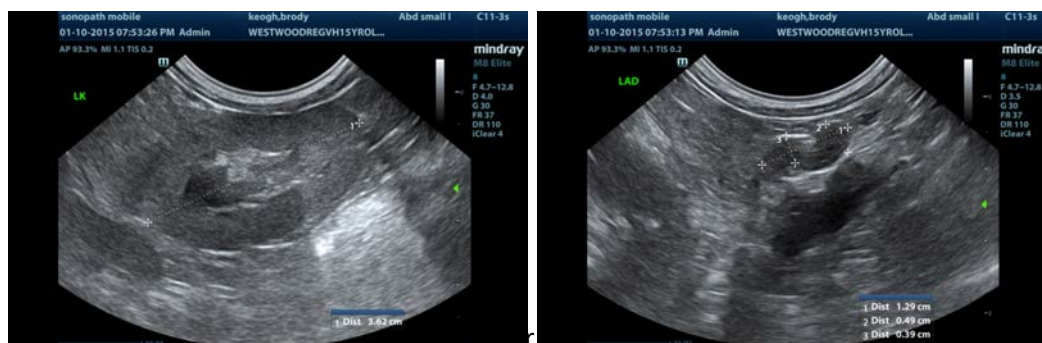
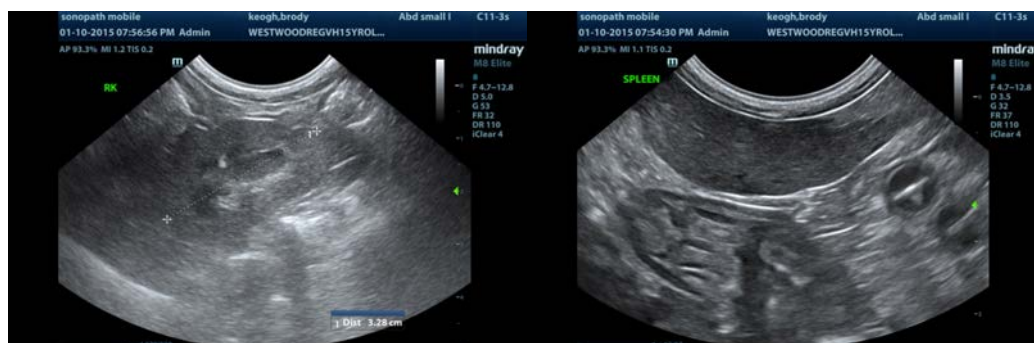Dr. Taylor McConnell

**INVOICE**

33102

**DATE**

11/26/21



The information and recommendations provided are based on the images presented by the referring veterinarian. No evaluation can be communicated regarding pathology that was not visible in the image/video clips provided.

Thank you for this referral. If the clinical or image interpretation does not parallel your findings or if I can be of any further assistance please contact me.

Kathleen Sennello DVM,MS, Diplomate ACVIM (Small animal Internal Medicine)  
kathleen.sennello@sonopath.com