



DATE PRESENTING CLINICAL SIGNS

11/25/25

Patient History: Senior Screening scan, no clinical signs at home, history multiple subcutaneous/cutaneous benign masses (confirmed benign with outside pathologist review), grade 2/6 CM

PATIENT

Koda Coakley

Current Medications: None.

Labwork Results: Labwork not attached, reported as: 09/20/25 liver panel- mild increase alpk (H) 423

Date of Previous IntraPet Ultrasound: No previous.

Sedation: Not required to complete full diagnostic ultrasound.

Stat Report: Not requested.

Imaging Performed by: Stephanie Warga RDCS, RVT.

SPECIES

Canine

BREED

Mixed

SEX

Spayed Female

AGE

3/20/14

WEIGHT

48 lbs

INTERPRETED BY

Kathleen Sennello DVM,
MS, Diplomate ACVIM
(Small Animal Internal
Medicine)

ULTRASONOGRAPHIC EXAMINATION OF THE ABDOMEN

Urinary System

The urinary bladder is moderately distended with anechoic urine. The Bladder wall, trigone, ureteral papillae and visible urethra (to a depth of 2cm) appear normal with no evidence of wall thickening, mucosal irregularities, masses or cystic calculi.

The left kidney has a normal shape and size (5.85 cm). Overall echogenicity is normal with adequate corticomedullary distinction and a typical 1:3 cortex:medulla ratio. There is no evidence of focal perinephric inflammation or effusion. There is no evidence of pyelectasia, nephroliths, infarcts or hydroureter. Renal vasculature is normal.

The right kidney has a normal shape and size (5.73 cm). Overall echogenicity is normal with adequate corticomedullary distinction and a typical 1:3 cortex:medulla ratio. There is no evidence of focal perinephric inflammation or effusion. There is no evidence of pyelectasia, nephroliths, infarcts or hydroureter. Renal vasculature is normal.

Adrenal Glands

The left adrenal gland is normal in size measuring 0.67 cm at the cranial pole and 0.73 cm at the caudal pole. It is observed in its normal position cranial to the left renal artery. It is normal in appearance (uniformly hypoechoic) and shape with no evidence of a mass effect.

The right adrenal gland is normal in size measuring 0.88 cm at the cranial pole and 0.60 cm at the caudal pole. It is observed in its normal position between the cranial aspect of the right kidney and the caudal vena cava. It is normal in appearance (uniformly hypoechoic) and shape with no evidence of a mass effect.

Spleen

The spleen is subjectively normal in size (1.22 cm), echotexture is homogenous, and the splenic capsule is smooth with no irregularities. The blood flow through the hilus and splenic parenchyma appears normal. No focal parenchymal abnormalities are visualized.

Liver

The liver is subjectively normal in size, and echogenicity with smooth peripheral margins. The parenchyma is subjectively mildly heterogenous in echotexture with subtle, indistinct focal mottling. The visible portions of the vasculature and biliary tract appear normal. No focal nodules or cystic lesions are observed.

HOSPITAL NAME

Perry Hall Animal
Hospital

REFERRING VET

Dr. Baer

INVOICE

72098

The gall bladder lumen is moderately distended. The wall of the gall bladder is not thickened and has a smooth mucosal surface. There is a moderate amount of non-organized echogenic debris. The cystic and common bile ducts are normal/not visible.

Gastrointestinal

The stomach contains mild ingesta. It measures at a normal thickness of <0.7cm with some variability due to the presence of rugal folds. The distinction of the gastric wall layers is adequate and there is no impression of reduced peristaltic activity. No masses or focal lesions were observed.

The visualized areas of duodenum, jejunum and ileum have a relatively uniform diameter with minimal fluid distension. Wall thickness is normal. Bowel loops follow a curvilinear path with distinct wall layering maintaining the typical 1:3 muscularis:mucosa layer ratio. Jejunum wall measures 0.26 cm. Visualized peristalsis appears appropriate. There were no focal lesions consistent with obstruction or a mass effect observed.

Sections of colon are visualized with formed fecal material and gas shadowing distally. There is no observed focal or generalized colon wall thickening or loss of layering.

Pancreas

The pancreas is normal and isoechoic to surrounding mesentery. There is no evidence of nodules or cystic lesions. There is no evidence of regional mesenteric inflammation or fluid.

Free Abdomen

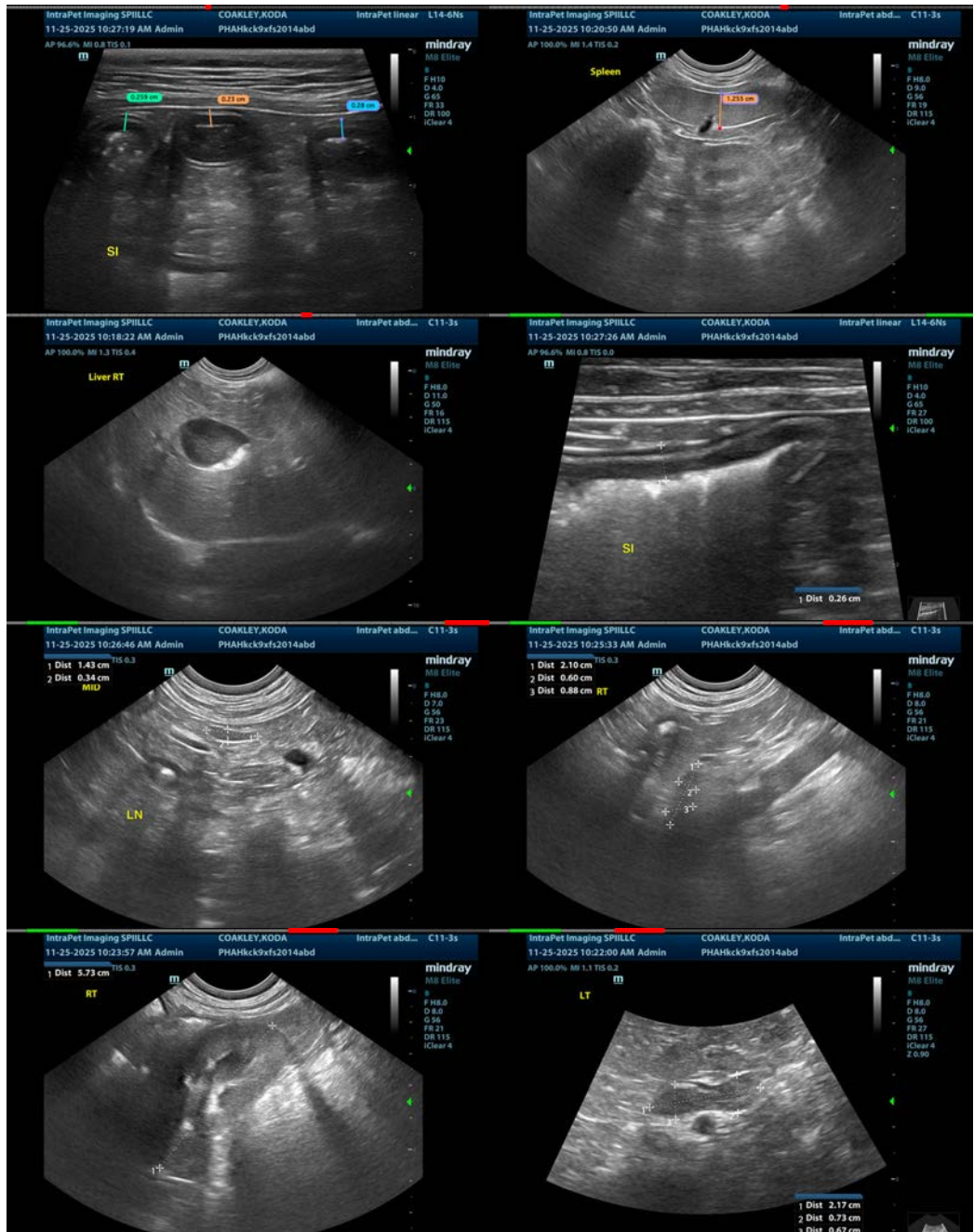
Evaluation of the peritoneal cavity did not reveal any evidence of effusion. There is no significant lymphadenopathy. A mesenteric lymph node is visualized measuring 0.34 cm. The omentum is of normal echogenicity.

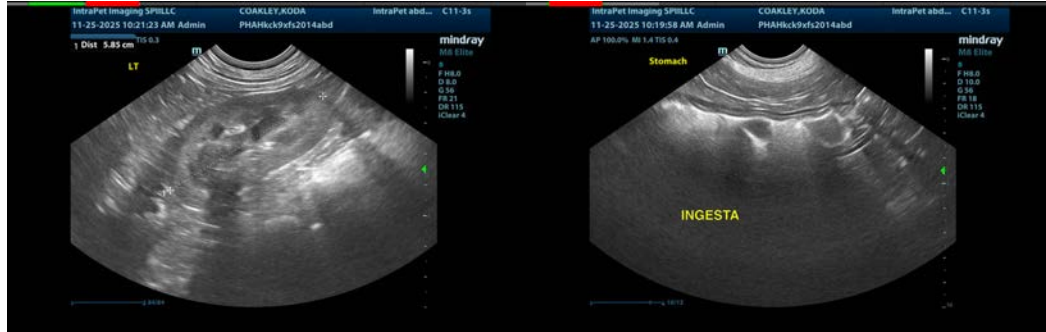
ULTRASONOGRAPHIC FINDINGS

- Subjectively mildly heterogeneous liver – The diffuse hepatic changes are non-specific and could be consistent with vacuolar hepatopathy, nodular hyperplasia, inflammatory/immune-mediated disease, fibrosis, extramedullary hematopoiesis, toxic hepatopathy (e.g., copper), infiltrative neoplasia (less likely) or other hepatopathy.
- Moderate gallbladder debris – The significance of the aggregated gallbladder debris is unclear. This could represent an early mucocele, cholestasis, or may be secondary to fasting but seems unlikely to be causing a current issue. Recommend continued monitoring.
- Mild ingesta visualized within the gastric lumen – Findings are most consistent with a non-fasted patient.

INTERPRETATION OF THE FINDINGS & FURTHER RECOMMENDATIONS

No focal lesions are visualized associated with the liver. Subjectively, the parenchyma appears mildly heterogeneous. This is a non-specific finding. Consider a liver function test (pre- and post-prandial bile acids) to further evaluate. If bile acids are elevated, recommend further evaluation, likely with a liver biopsy with samples for histopathology, culture and copper levels. Otherwise, consider Denamarin and continued monitoring with reassessment if liver values continue to rise.





The information and recommendations provided are based on the images presented by the referring veterinarian/sonographer. No evaluation can be communicated regarding pathology that was not visible in the image/video clips provided.

Thank you for this referral. If the clinical or image interpretation does not parallel your findings or if I can be of any further assistance please contact me.

Kathleen Sennello DVM,MS, Diplomate ACVIM (Small animal Internal Medicine)
info@sonopath.com