



**PATIENT**

Henna Weitzmann

**SPECIES**

Canine

**BREED**

Redbone Coonhound

**SEX**

Spayed Female

**AGE**

7 Years

**WEIGHT**

83.4 lbs

**INTERPRETED BY**

Kathleen Sennello DVM,  
MS, Diplomate ACVIM  
(Small Animal Internal  
Medicine)

**IMAGING PERFORMED BY**

Shari Reffi, CVT

**HOSPITAL NAME**

Nazareth Veterinary  
Center

**REFERRING VET**

Dr. Gusztaw

**INVOICE**

72072

**DATE**

11/25/25

**PRESENTING CLINICAL SIGNS**

H/O Mesenteric lymphadenopathy on prior abd. ultrasound 5/2024 (prev report attached); Elevated ALKP, mildly pendulous abdomen. Hyposthenuria with +2 proteinuria. Episode of hematochezia in 10/25.

Abnormal PE/Chem/CBC/UA Results: ALKP 1660; UA: USG 1.013; +2 protein

**ULTRASONOGRAPHIC EXAMINATION OF THE ABDOMEN**

**Urinary System**

The urinary bladder is moderately distended with anechoic urine. The Bladder wall, trigone, ureteral papillae and visible urethra (to a depth of 2cm) appear normal with no evidence of wall thickening, mucosal irregularities, masses or cystic calculi.

The left kidney has a normal shape and size (8.04 cm). Overall echogenicity is normal with adequate corticomedullary distinction and a typical 1:3 cortex:medulla ratio. There is no evidence of focal perinephric inflammation or effusion. There is no evidence of pyelectasia, nephroliths, infarcts or hydroureter. Renal vasculature is normal.

The right kidney has a normal shape and size (7.63 cm). Overall echogenicity is normal with adequate corticomedullary distinction and a typical 1:3 cortex:medulla ratio. There is no evidence of focal perinephric inflammation or effusion. There is no evidence of pyelectasia, nephroliths, infarcts or hydroureter. Renal vasculature is normal.

**Adrenal Glands**

The left adrenal gland is normal in size measuring 0.62 cm at the cranial pole and 0.61 cm at the caudal pole. It is observed in its normal position cranial to the left renal artery. It is normal in appearance (uniformly hypoechoic) and shape with no evidence of a mass effect.

The right adrenal gland is normal in size measuring 0.82 cm at the cranial pole and 0.78 cm at the caudal pole. It is observed in its normal position between the cranial aspect of the right kidney and the caudal vena cava. It is normal in appearance (uniformly hypoechoic) and shape with no evidence of a mass effect.

**Spleen**

The spleen is subjectively normal in size (3.22 cm), echotexture is homogenous, and the splenic capsule is smooth with no irregularities. The blood flow through the hilus and splenic parenchyma appears normal. No focal parenchymal abnormalities are visualized.

**Liver**

The liver is large in size and slightly rounded. The parenchyma is heterogenous in echotexture with subtle, indistinct focal mottling. The visible portions of the vasculature and biliary tract appear normal. No focal nodules or cystic lesions are observed.

The gall bladder lumen is moderately distended. The wall of the gall bladder is not thickened and has a smooth mucosal surface. Luminal contents are mild and likely incidental at this time. The cystic and common bile ducts are normal/not visible.



**PATIENT**

Henna Weitzmann

**SPECIES**

Canine

**BREED**

Redbone Coonhound

**SEX**

Spayed Female

**AGE**

7 Years

**WEIGHT**

83.4 lbs

**INTERPRETED BY**

Kathleen Sennello DVM,  
MS, Diplomate ACVIM  
(Small Animal Internal  
Medicine)

**IMAGING PERFORMED BY**

Shari Reffi, CVT

**HOSPITAL NAME**

Nazareth Veterinary  
Center

**REFERRING VET**

Dr. Gusztaw

**INVOICE**

72072

**DATE**

11/25/25

**Gastrointestinal**

The stomach contains minimal luminal contents. It measures at a normal thickness of <0.7cm with some variability due to the presence of rugal folds. The distinction of the gastric wall layers is adequate and there is no impression of reduced peristaltic activity. No masses or focal lesions were observed.

The visualized areas of duodenum, jejunum and ileum have a relatively uniform diameter with minimal fluid distension. Wall thickness is normal. Bowel loops follow a curvilinear path with distinct wall layering maintaining the typical 1:3 muscularis:mucosa layer ratio. Duodenum wall measures 0.57 cm. Jejunum wall measures 0.45 cm. Visualized peristalsis appears appropriate. There were no focal lesions consistent with obstruction or a mass effect observed.

Sections of colon are visualized with formed fecal material and gas shadowing distally. There is no observed focal or generalized colon wall thickening or loss of layering.

**Pancreas**

The pancreas is normal and isoechoic to surrounding mesentery. There is no evidence of nodules or cystic lesions. There is no evidence of regional mesenteric inflammation or fluid.

**Free Abdomen**

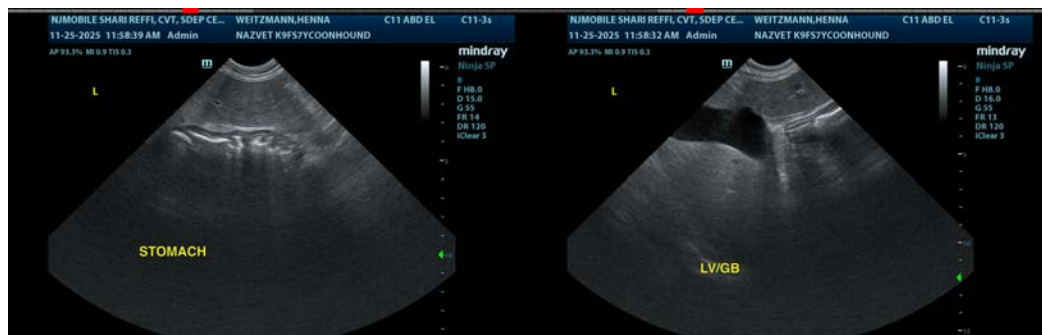
Evaluation of the peritoneal cavity did not reveal any evidence of effusion, or subjective lymphadenomegaly. The Medial iliac nodes appear normal and there was no evidence of a caudal aortic thrombus at the bifurcation. The omentum is of normal uniform echogenicity.

**ULTRASONOGRAPHIC FINDINGS**

- Large, heterogeneous, rounded liver – The liver has the appearance most consistent with a vacuolar hepatopathy. Other hepatopathies are possible.

**INTERPRETATION OF THE FINDINGS & FURTHER RECOMMENDATIONS**

The liver is large and slightly heterogeneous with some rounded margins. A discrete focal lesion is not clearly visualized. Based on the appearance, a vacuolar hepatopathy is most likely, but other hepatopathies are also possible. If Cushing's is suspected, you could consider adrenal function testing. The adrenals are normal in size, but this does not rule out the possibility of Cushing's disease. If a more significant hepatopathy is suspected, consider a liver function test and a fine needle aspirate of the liver.





**PATIENT**

Henna Weitzmann

**SPECIES**

Canine

**BREED**

Redbone Coonhound

**SEX**

Spayed Female

**AGE**

7 Years

**WEIGHT**

83.4 lbs

**INTERPRETED BY**

Kathleen Sennello DVM,  
 MS, Diplomate ACVIM  
 (Small Animal Internal  
 Medicine)

**IMAGING PERFORMED BY**

Shari Reffi, CVT

**HOSPITAL NAME**

Nazareth Veterinary  
 Center

**REFERRING VET**

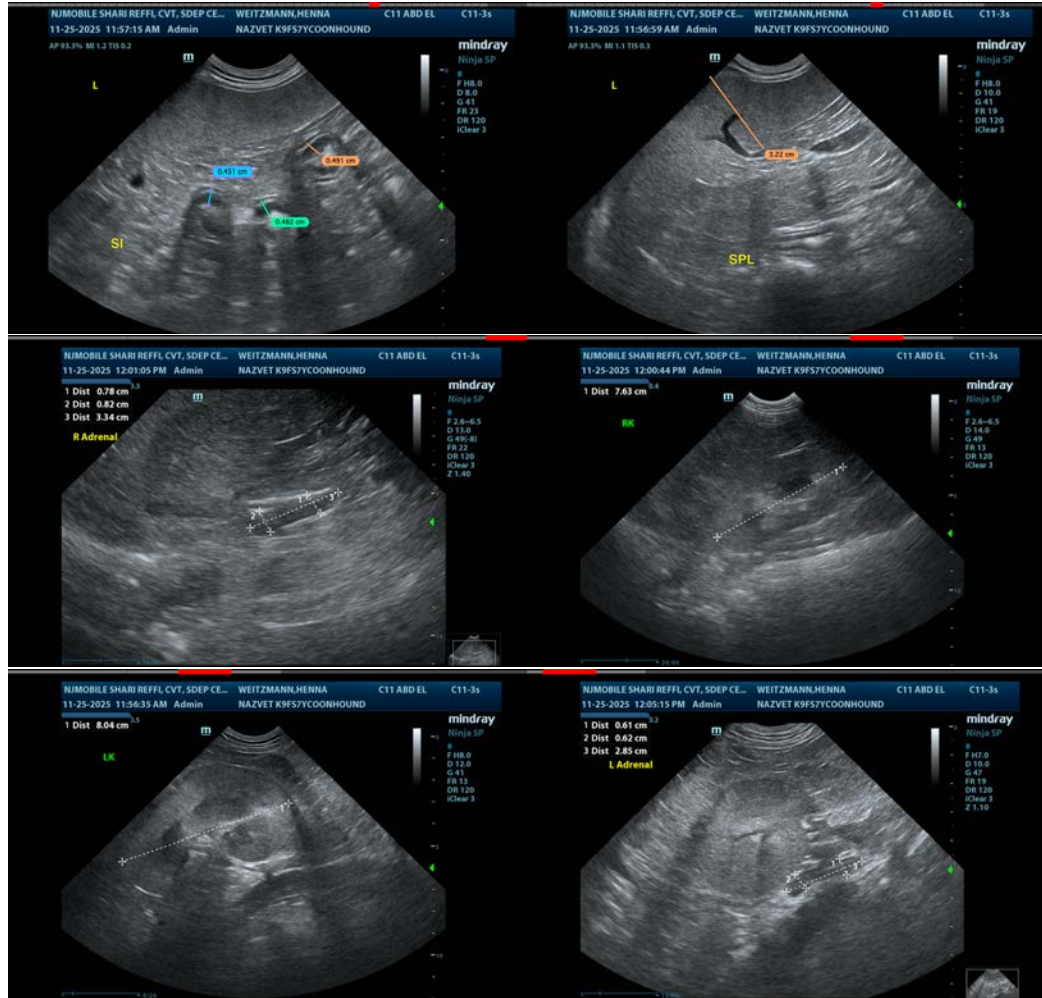
Dr. Gusztaw

**INVOICE**

72072

**DATE**

11/25/25



The information and recommendations provided are based on the images presented by the referring veterinarian/sonographer. No evaluation can be communicated regarding pathology that was not visible in the image/video clips provided.

Thank you for this referral. If the clinical or image interpretation does not parallel your findings or if I can be of any further assistance please contact me.

Kathleen Sennello DVM,MS, Diplomate ACVIM (Small animal Internal Medicine)

info@sonopath.com