



PATIENT

Delilah Naidu

SPECIES

Canine

BREED

Chihuahua X

SEX

FS

AGE

9 years

WEIGHT

18.2 lbs

INTERPRETED BY

Kathleen Sennello DVM,
MS, Diplomate ACVIM
(Small Animal Internal
Medicine)

IMAGING PERFORMED BY

Dr. Judy Schroeder

HOSPITAL NAME

Animal Health
Associates

REFERRING VET

Dr. Judy Schroeder

INVOICE

10819

DATE

11/25/2025

PRESENTING CLINICAL SIGNS

Seen at ER for pain, dx with UTI, culture showed E coli, tx with clavacillin. Seen 10 d later for pain, UA showed rod bacteriuria, tx with enrofloxacin. Follow up UA after enro showed 2 + epithelial cells, otherwise normal. Blood testing showed mild increase in ALP. Rads to check for urolith showed hepatomegaly.

Abnormal PE/Chem/CBC/UA Results: Mild cranial abdominal distension. Most recent UA showed USG 1.028, 2 + epithelial cells, 1+ bili. No blood, bacteria, crystals, wbc noted. ALP 197 U/l.

ULTRASONOGRAPHIC EXAMINATION OF THE ABDOMEN

Urinary System

The urinary bladder is moderately distended with mild primarily suspended echogenic debris present. The Bladder wall, trigone, ureteral papillae and visible urethra (to a depth of 2cm) appear normal with no evidence of wall thickening, mucosal irregularities, masses or calculi. Echogenic debris of this type can be associated with small crystals, cellular debris and proteinaceous debris.

The left kidney has a normal shape and size (4.32 cm). Overall echogenicity is slightly hyperechoic with poor corticomedullary distinction and a typical 1:3 cortex:medulla ratio. There is no evidence of focal perinephric inflammation or effusion. There is no evidence of pyelectasia, nephroliths, infarcts or hydroureter. Renal vasculature is normal.

The right kidney has a normal shape and size (4.63 cm). Overall echogenicity is slightly hyperechoic with poor corticomedullary distinction and a typical 1:3 cortex:medulla ratio. There is no evidence of focal perinephric inflammation or effusion. There is a small pinpoint cortical mineralization is noted. There is no evidence of pyelectasia, infarcts or hydroureter. Renal vasculature is normal.

Adrenal Glands

The left adrenal gland is normal in size measuring 0.48 cm at the cranial pole and 0.49 cm at the caudal pole. It is observed in its normal position cranial to the left renal artery. It is normal in appearance (uniformly hypoechoic) and shape with no evidence of a mass effect.

The right adrenal gland is normal in size measuring 0.61 cm at the cranial pole and 0.69 cm at the caudal pole. It is observed in its normal position between the cranial aspect of the right kidney and the caudal vena cava. It is normal in appearance (uniformly hypoechoic) and shape with no evidence of a mass effect.

Spleen

The spleen is subjectively normal in size (0.98 cm) and the echotexture is homogenous. The splenic capsule is smooth with no visible irregularities. The blood flow through the hilus and splenic parenchyma appears normal. There's a very subtle, hypoechoic nodule visualized at the periphery of the spleen measuring 0.59 cm.

Liver

The liver is large in size, and normal in echogenicity with smooth peripheral margins. The parenchyma is mildly heterogenous in echotexture with subtle, indistinct focal mottling. The visible portions of the vasculature and biliary tract appear normal. No focal nodules or cystic lesions are observed.



PATIENT

Delilah Naidu

The gall bladder lumen is moderately distended. The wall of the gall bladder is not thickened and has a smooth mucosal surface. Luminal contents are mild and likely incidental at this time. The cystic and common bile ducts are normal/not visible.

SPECIES

Canine

Gastrointestinal

The stomach contains minimal luminal contents. It measures at a normal thickness of <0.7cm with some variability due to the presence of rugal folds. The distinction of the gastric wall layers is adequate and there is no impression of reduced peristaltic activity. No masses or focal lesions were observed.

BREED

Chihuahua X

The visualized areas of duodenum, jejunum and ileum have a relatively uniform diameter with minimal fluid distension. Wall thickness is normal. Bowel loops follow a curvilinear path with distinct wall layering maintaining the typical 1:3 muscularis:mucosa layer ratio. The duodenum measured as normal (0.32 in wall thickness) and the jejunum measured as normal (0.23 cm.) Visualized peristalsis appears appropriate. There were no focal lesions consistent with obstruction or a mass effect observed.

SEX

FS

AGE

9 years

Sections of colon are visualized with formed fecal material and gas shadowing distally. There is no observed focal or generalized colon wall thickening or loss of layering.

WEIGHT

18.2 lbs

Pancreas

The pancreas is mildly mottled. There is no evidence of nodules or cystic lesions. There is no evidence of regional mesenteric inflammation or fluid.

INTERPRETED BY

Kathleen Sennello DVM,
MS, Diplomate ACVIM
(Small Animal Internal
Medicine)

Free Abdomen

Evaluation of the peritoneal cavity did not reveal any evidence of effusion, or subjective lymphadenomegaly. The Medial iliac nodes appear normal and there was no evidence of a caudal aortic thrombus at the bifurcation. The omentum is of normal uniform echogenicity.

IMAGING PERFORMED BY

Dr. Judy Schroeder

ULTRASONOGRAPHIC FINDINGS

- Age related changes visualized associated with both kidneys.
- Mild suspended echogenic debris in the urinary bladder. The echogenic debris in the bladder lumen could be consistent with cells, crystals, and/or mucus. Recommend urinalysis and culture.
- Subtle, hypoechoic nodule in the spleen. There is a non-cavitated, hypoechoic splenic nodule visualized. Differentials include lymphoid hyperplasia, extramedullary hematopoiesis, infiltrative neoplasia, inflammation, other. Cytology or histopathology would be necessary to get a definitive diagnosis.
- Pancreatic changes most consistent with mild pancreatic remodeling.
- Large, mildly heterogenous liver. Changes are mild and non-specific, possibly consistent with a vacuolar hepatopathy or similar.

HOSPITAL NAME

Animal Health
Associates

REFERRING VET

Dr. Judy Schroeder

INVOICE

10819

DATE

11/25/2025

INTERPRETATION OF THE FINDINGS & FURTHER RECOMMENDATIONS

The changes observed on today's scan are mild. No masses or stones were visualized associated with



PATIENT

Delilah Naidu

SPECIES

Canine

BREED

Chihuahua X

SEX

FS

AGE

9 years

WEIGHT

18.2 lbs

INTERPRETED BY

Kathleen Sennello DVM,
MS, Diplomate ACVIM
(Small Animal Internal
Medicine)

**IMAGING
PERFORMED BY**

Dr. Judy Schroeder

HOSPITAL NAME

Animal Health
Associates

REFERRING VET

Dr. Judy Schroeder

INVOICE

10819

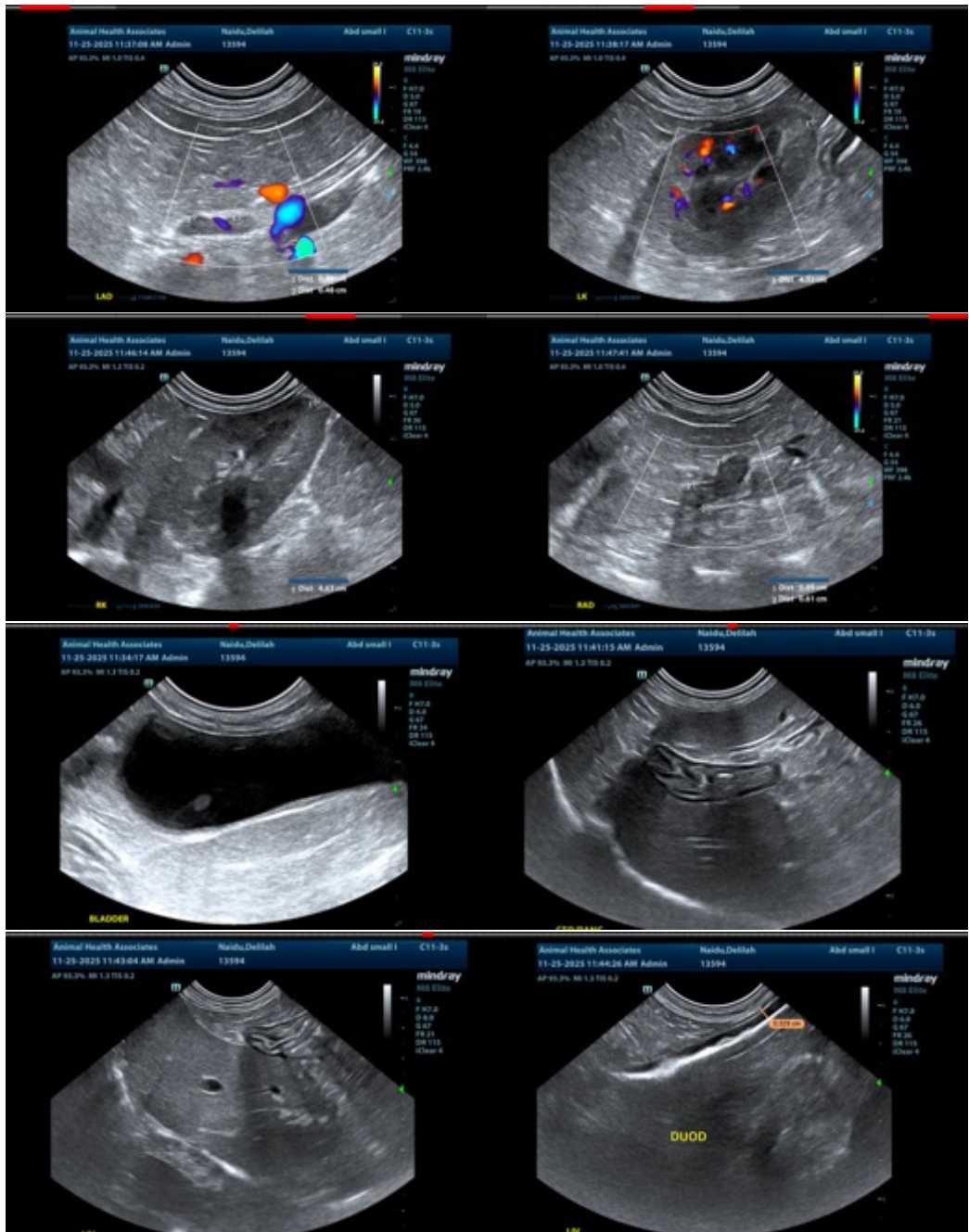
DATE

11/25/2025

the urinary tract to explain the symptoms reported. There's a small amount of echogenic material most consistent with debris, mucous, etc. Recommend a urinalysis and culture to further evaluate.

There's a very subtle, small hypoechoic nodule in the spleen. Options moving forward could include a fine needle aspirate or continued monitoring with ultrasound.

The hepatic changes are mild and non-specific. Possibly consistent with an early vacuolar hepatopathy. Recommend continued monitoring.





PATIENT

Delilah Naidu

SPECIES

Canine

BREED

Chihuahua X

SEX

FS

AGE

9 years

WEIGHT

18.2 lbs

INTERPRETED BY

Kathleen Sennello DVM,
MS, Diplomate ACVIM
(Small Animal Internal
Medicine)

IMAGING PERFORMED BY

Dr. Judy Schroeder

HOSPITAL NAME

Animal Health
Associates

REFERRING VET

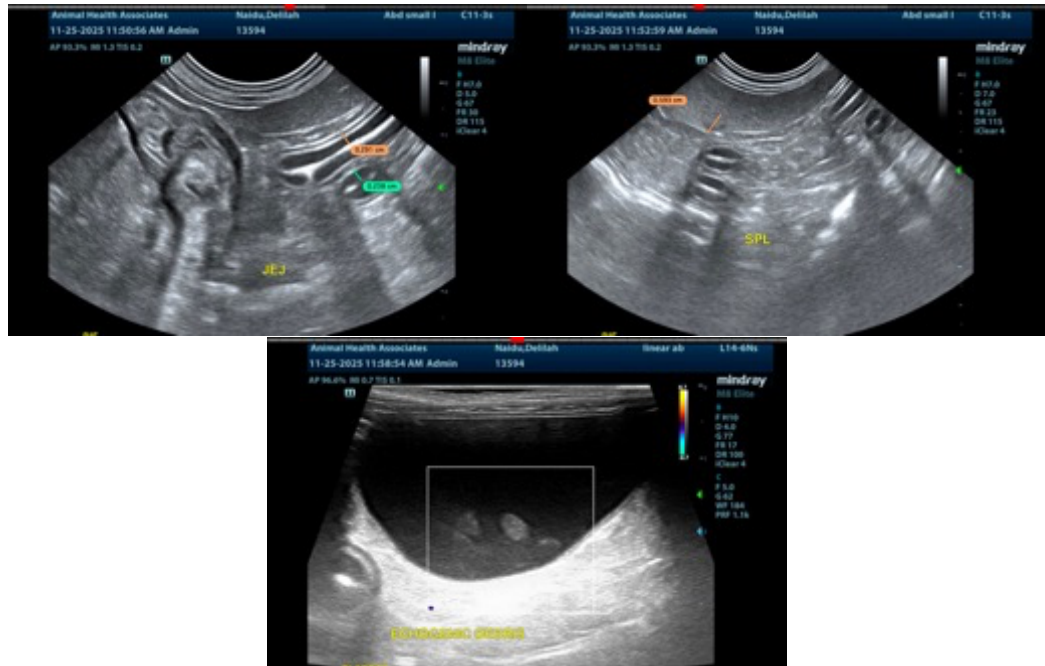
Dr. Judy Schroeder

INVOICE

10819

DATE

11/25/2025



The information and recommendations provided are based on the images presented by the referring veterinarian/sonographer. No evaluation can be communicated regarding pathology that was not visible in the image/video clips provided.

Thank you for this referral. If the clinical or image interpretation does not parallel your findings or if I can be of any further assistance please contact me.

Kathleen Sennello DVM,MS, Diplomate ACVIM (Small animal Internal Medicine)

info@sonopath.com