



PATIENT

Cooper Maeda

SPECIES

Canine

BREED

Mini Daschund

SEX

MN

AGE

14

WEIGHT

10.8

INTERPRETED BY

Kathleen Sennello DVM,
MS, Diplomate ACVIM
(Small Animal Internal
Medicine)

IMAGING PERFORMED BY

Dr. Brittany Wolfe

HOSPITAL NAME

Home Vets

REFERRING VET

Dr. Brittany Wolfe

INVOICE

10827

DATE

11/25/2025

PRESENTING CLINICAL SIGNS

P presented for persistent liver enzyme elevation since feb 2025, recent elevated cPL and diarrhea (now resolved).

Abnormal PE/Chem/CBC/UA Results: Feb 2025 ALT 411, ALP normal at 59 (cPL not tested) Nov 2025 ALT 466 ALP 255, cPL 1,710.

ULTRASONOGRAPHIC EXAMINATION OF THE ABDOMEN

Urinary System

The urinary bladder is mildly distended with anechoic urine. The Bladder wall, trigone, ureteral papillae and visible urethra (to a depth of 2cm) appear normal with no evidence of wall thickening, mucosal irregularities, masses or cystic calculi.

The visualized areas of prostate and surrounding tissue appear normal. Unfortunately, the prostate is not fully visualized likely due to its intrapelvic location. Correlate with rectal exam findings.

The left kidney has a normal shape and size (4.1 cm). Overall echogenicity is normal with adequate corticomedullary distinction and a typical 1:3 cortex:medulla ratio. There is no evidence of focal perinephric inflammation or effusion. There is no evidence of pyelectasia, nephroliths, infarcts or hydroureter. Renal vasculature is normal.

The right kidney has a normal shape and size (4.25 cm). Overall echogenicity is normal with adequate corticomedullary distinction and a typical 1:3 cortex:medulla ratio. There is no evidence of focal perinephric inflammation or effusion. There is no evidence of pyelectasia, nephroliths, infarcts or hydroureter. Renal vasculature is normal.

Adrenal Glands

The left adrenal gland is normal in size measuring 0.45 cm at the cranial pole and 0.6 cm at the caudal pole. It is observed in its normal position cranial to the left renal artery. It is normal in appearance (uniformly hypoechoic) and shape with no evidence of a mass effect.

The right adrenal gland is normal in size measuring 0.7 cm at the cranial pole and 0.6 cm at the caudal pole. It is observed in its normal position between the cranial aspect of the right kidney and the caudal vena cava. It is normal in appearance (uniformly hypoechoic) and shape with no evidence of a mass effect.

Spleen

The spleen is subjectively normal in size (1.08 cm) and the echotexture is homogenous. The splenic capsule is smooth with no visible irregularities. The blood flow through the hilus and splenic parenchyma appears normal. No focal parenchymal abnormalities are visualized.

Liver

The liver is subjectively large in size, and normal in echogenicity with smooth peripheral margins. The parenchyma is mildly heterogenous in echotexture with subtle, indistinct focal mottling. The visible portions of the vasculature and biliary tract appear normal. No focal nodules or cystic lesions are observed



PATIENT

Cooper Maeda

The gall bladder lumen is significantly distended. Some areas of the wall appear mildly thickened with adherent debris. There is a large amount of primarily non-organized echogenic debris. There is no evidence of bile duct dilation.

SPECIES

Canine

Gastrointestinal

The stomach contains minimal luminal contents. It measures at a normal thickness of <0.7cm with some variability due to the presence of rugal folds. The distinction of the gastric wall layers is adequate and there is no impression of reduced peristaltic activity. No masses or focal lesions were observed.

BREED

Mini Daschund

The visualized areas of duodenum (0.5 cm), jejunum (0.3 cm) and ileum have a uniform diameter with minimal fluid distension. Wall appears subjectively, mildly increased. Bowel loops follow a typical curvilinear path with distinct wall layering. Visualized peristalsis appears appropriate. There were no focal lesions consistent with obstruction or a mass effect observed

SEX

MN

AGE

14

Sections of colon are visualized with non-formed/liquid fecal material and gas shadowing distally. There is no observed focal or generalized colon wall thickening or loss of layering.

Pancreas

WEIGHT

10.8

The pancreas is normal and isoechoic to surrounding mesentery. There is no evidence of nodules or cystic lesions. There is no evidence of regional mesenteric inflammation or fluid.

Free Abdomen

INTERPRETED BY

Kathleen Sennello DVM,
MS, Diplomate ACVIM
(Small Animal Internal
Medicine)

Evaluation of the peritoneal cavity did not reveal any evidence of effusion, or subjective lymphadenomegaly. The Medial iliac nodes appear normal and there was no evidence of a caudal aortic thrombus at the bifurcation. The omentum is of normal uniform echogenicity.

ULTRASONOGRAPHIC FINDINGS

IMAGING PERFORMED BY

Dr. Brittany Wolfe

- Large, mildly heterogenous liver. The diffuse hepatic changes are non-specific and could be consistent with vacuolar hepatopathy, nodular hyperplasia, inflammatory/immune-mediated disease, infiltrative neoplasia (less likely) or other hepatopathy.
- Large, distended gallbladder with a large amount of non-organized intraluminal material. A large amount of debris is evident in the gall bladder with no evidence of a mucocele or associated inflammation at this time. This could represent an early mucocele or cholestasis, with minimal evidence of associated inflammation at this time. Continued monitoring of lab work and ultrasound are warranted for progression of this lesion. Ursodiol therapy could be considered.
- Mildly thickened/prominent small intestine. The mild small intestinal wall changes may be a normal variant in this patient or could be consistent with an inflammatory process (e.g., inflammatory bowel disease).

HOSPITAL NAME

Home Vets

REFERRING VET

Dr. Brittany Wolfe

INVOICE

10827

INTERPRETATION OF THE FINDINGS & FURTHER RECOMMENDATIONS

DATE

11/25/2025

No focal lesions are visualized associated with the liver to explain the elevation in liver enzymes reported. There is a large amount of debris visualized in the gallbladder. There is no associated inflammation noted but mild cholecystitis is possible. Recommend starting chronic ursodiol therapy and continued monitoring of the gallbladder. Additionally, you could consider a course of antibiotics



PATIENT

Cooper Maeda

SPECIES

Canine

BREED

Mini Daschund

SEX

MN

AGE

14

WEIGHT

10.8

INTERPRETED BY

Kathleen Sennello DVM,
MS, Diplomate ACVIM
(Small Animal Internal
Medicine)

IMAGING PERFORMED BY

Dr. Brittany Wolfe

HOSPITAL NAME

Home Vets

REFERRING VET

Dr. Brittany Wolfe

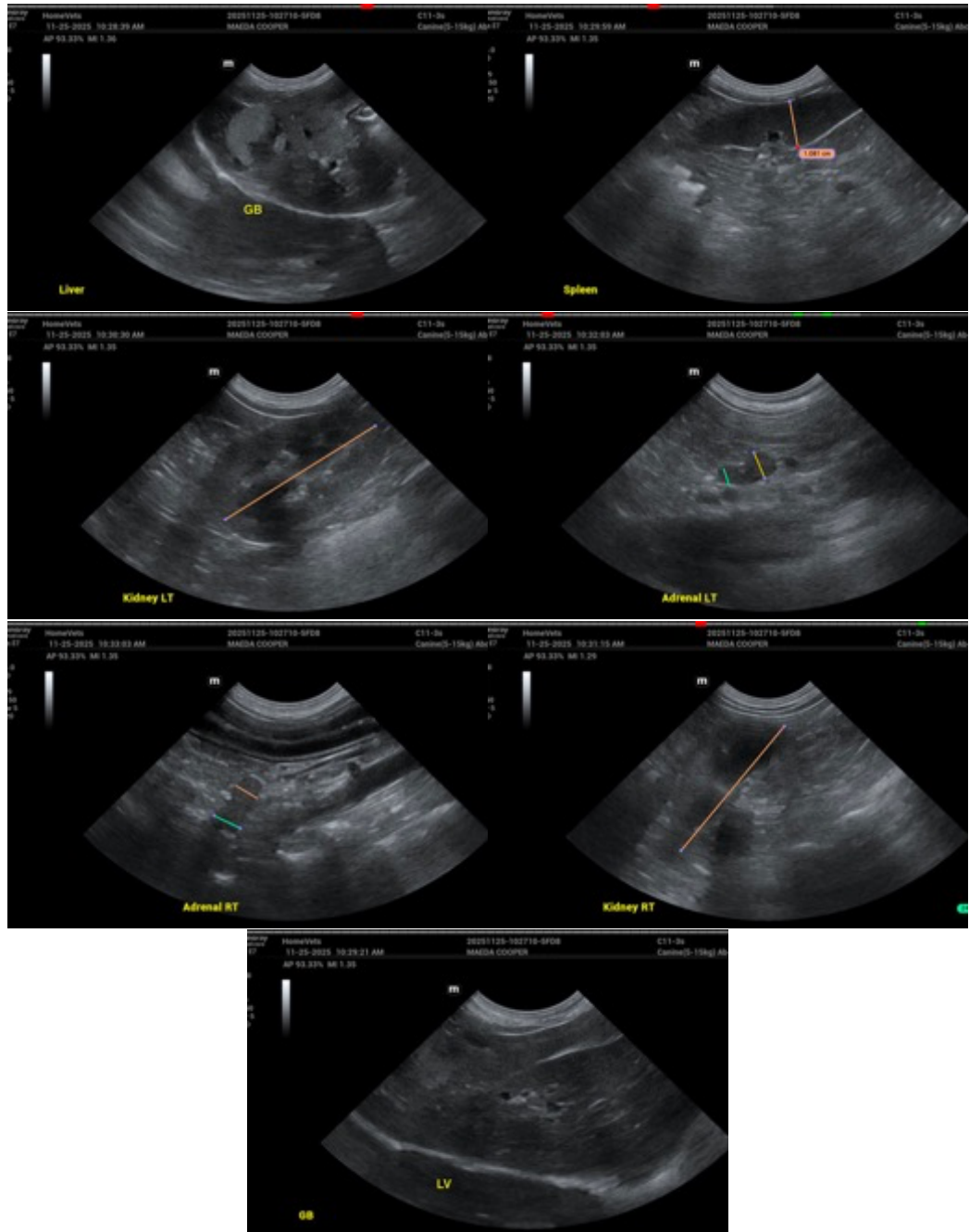
INVOICE

10827

DATE

11/25/2025

for possible cholecystitis, particularly if there's no improvement after the resolution of the diarrhea and the Denamarin therapy.



The information and recommendations provided are based on the images presented by the referring veterinarian/sonographer. No evaluation can be communicated regarding pathology that was not visible in the image/video clips provided.

Thank you for this referral. If the clinical or image interpretation does not parallel your findings or if I



PATIENT

Cooper Maeda

SPECIES

Canine

BREED

Mini Daschund

SEX

MN

AGE

14

WEIGHT

10.8

INTERPRETED BY

Kathleen Sennello DVM,
MS, Diplomate ACVIM
(Small Animal Internal
Medicine)

IMAGING PERFORMED BY

Dr. Brittany Wolfe

HOSPITAL NAME

Home Vets

REFERRING VET

Dr. Brittany Wolfe

INVOICE

10827

DATE

11/25/2025

can be of any further assistance please contact me.

Kathleen Sennello DVM,MS, Diplomate ACVIM (Small animal Internal Medicine)

info@sonopath.com