

PATIENT

Bailey Whitehead

SPECIES

Canine

BREED

Pitbull

SEX

Spayed Female

AGE

2016

WEIGHT

65.3

INTERPRETED BY

Kathleen Sennello DVM,
 MS, Diplomate ACVIM
 (Small Animal Internal
 Medicine)

IMAGING PERFORMED BY

Rebekah Jakum, CVT,
 ARDMS/RVT

HOSPITAL NAME

Alburtis AH

REFERRING VET

Dr. Smith

INVOICE

10818

DATE

11/25/2025

PRESENTING CLINICAL SIGNS

Atopic dermatitis, persistent, progressive hypoalbuminemia, hyperglobulinemia

Medication: carprofen, apoquel, cytopoint.

ULTRASONOGRAPHIC EXAMINATION OF THE ABDOMEN

Urinary System

The urinary bladder is moderately distended with anechoic urine. The Bladder wall, trigone, ureteral papillae and visible urethra (to a depth of 2cm) appear normal with no evidence of wall thickening, mucosal irregularities, masses or cystic calculi.

The left kidney has a normal shape and size (5.8 cm). Overall echogenicity is normal with adequate corticomedullary distinction and a typical 1:3 cortex:medulla ratio. There is no evidence of focal perinephric inflammation or effusion. There is no evidence of pyelectasia, nephroliths, infarcts or hydroureter. Renal vasculature is normal.

The right kidney has a normal shape and size (6.27 cm). Overall echogenicity is normal with adequate corticomedullary distinction and a typical 1:3 cortex:medulla ratio. There is no evidence of focal perinephric inflammation or effusion. There is no evidence of pyelectasia, nephroliths, infarcts or hydroureter. Renal vasculature is normal.

Adrenal Glands

The left adrenal gland is normal in size measuring 0.59 cm at the cranial pole and 0.59 cm at the caudal pole. It is observed in its normal position cranial to the left renal artery. It is normal in appearance (uniformly hypoechoic) and shape with no evidence of a mass effect.

The right adrenal gland is normal in size measuring 0.45 cm at the cranial pole and 0.48 cm at the caudal pole. It is observed in its normal position between the cranial aspect of the right kidney and the caudal vena cava. It is normal in appearance (uniformly hypoechoic) and shape with no evidence of a mass effect.

Spleen

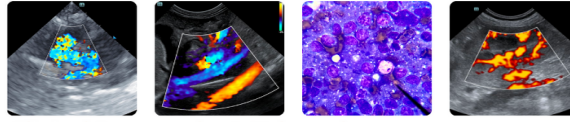
The spleen is subjectively normal in size (2.1 cm) and shape, but it is slightly folded. The echotexture is homogenous. The splenic capsule is smooth with no visible irregularities. The blood flow through the hilus and splenic parenchyma appears normal. No focal parenchymal abnormalities are visualized.

Liver

The liver is subjectively normal/borderline small in size, and echogenicity with smooth peripheral margins. The parenchyma is homogenous echotexture. The visible portions of the vasculature and biliary tract appear normal. No focal nodules or cystic lesions are observed.

The gall bladder lumen is moderately distended. The wall of the gall bladder is not thickened and has a smooth mucosal surface. Luminal contents are mild and likely incidental at this time. The cystic and common bile ducts are normal/not visible.

Gastrointestinal



PATIENT

Bailey Whitehead

SPECIES

Canine

BREED

Pitbull

SEX

Spayed Female

AGE

2016

WEIGHT

65.3

INTERPRETED BY

Kathleen Sennello DVM,
 MS, Diplomate ACVIM
 (Small Animal Internal
 Medicine)

IMAGING PERFORMED BY

Rebekah Jakum, CVT,
 ARDMS/RVT

HOSPITAL NAME

Alburtis AH

REFERRING VET

Dr. Smith

INVOICE

10818

DATE

11/25/2025

The stomach contains mild fluid and gas. It measures at a normal thickness of <0.7cm with some variability due to the presence of rugal folds. The distinction of the gastric wall layers is adequate and there is no impression of reduced peristaltic activity. No masses or focal lesions were observed.

The visualized areas of duodenum, jejunum and ileum have a relatively uniform diameter with minimal fluid distension. Wall thickness is normal. Bowel loops follow a curvilinear path with distinct wall layering maintaining the typical 1:3 muscularis:mucosa layer ratio. The duodenum measured as normal (0.36 cm in wall thickness) and the jejunum measured as normal (0.33 cm.) Visualized peristalsis appears appropriate. There were no focal lesions consistent with obstruction or a mass effect observed.

Sections of colon are visualized with formed fecal material and gas shadowing distally. There is no observed focal or generalized colon wall thickening or loss of layering.

Pancreas

The pancreas is normal and isoechoic to surrounding mesentery. There is no evidence of nodules or cystic lesions. There is no evidence of regional mesenteric inflammation or fluid.

Free Abdomen

Evaluation of the peritoneal cavity did not reveal any evidence of effusion, or subjective lymphadenomegaly. The Medial iliac nodes appear normal and there was no evidence of a caudal aortic thrombus at the bifurcation. The omentum is of normal uniform echogenicity.

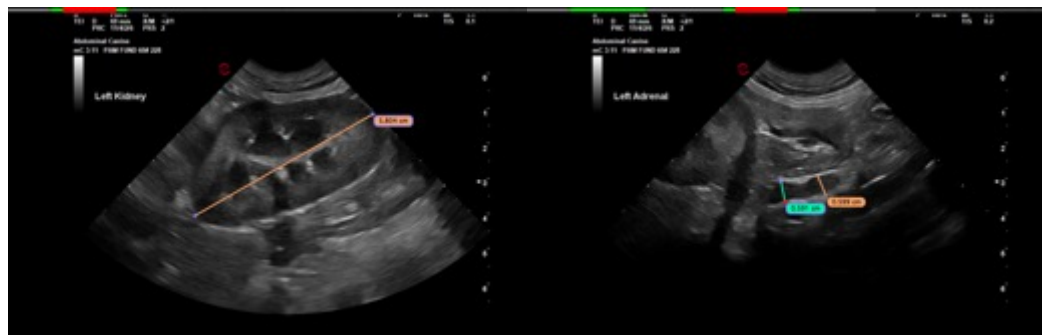ULTRASONOGRAPHIC FINDINGS

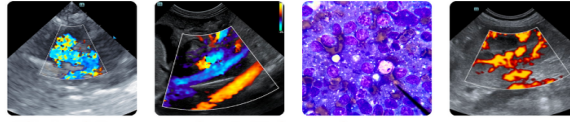
- Borderline small liver. Findings could be consistent with anatomic variation, fibrosis, a portosystemic shunt, etc.

INTERPRETATION OF THE FINDINGS & FURTHER RECOMMENDATIONS

The liver appears borderline small with no focal lesions visualized. Given the hypoalbuminemia reported. Recommend pre- and post-prandial bile acids to further evaluate. If liver function is significantly abnormal, consider a biopsy of the liver with samples for histopathology, culture, and copper levels +/- contrast CT scan looking for a small portosystemic shunt.

Based on the information provided, the normal urine protein-creatinine ratio makes a renal source very unlikely. Additionally, the normal globulin makes underlying gastrointestinal disease less likely, although, not impossible.





PATIENT

Bailey Whitehead

SPECIES

Canine

BREED

Pitbull

SEX

Spayed Female

AGE

2016

WEIGHT

65.3

INTERPRETED BY

Kathleen Sennello DVM,
MS, Diplomate ACVIM
(Small Animal Internal
Medicine)

**IMAGING
PERFORMED BY**

Rebekah Jakum, CVT,
ARDMS/RVT

HOSPITAL NAME

Alburtis AH

REFERRING VET

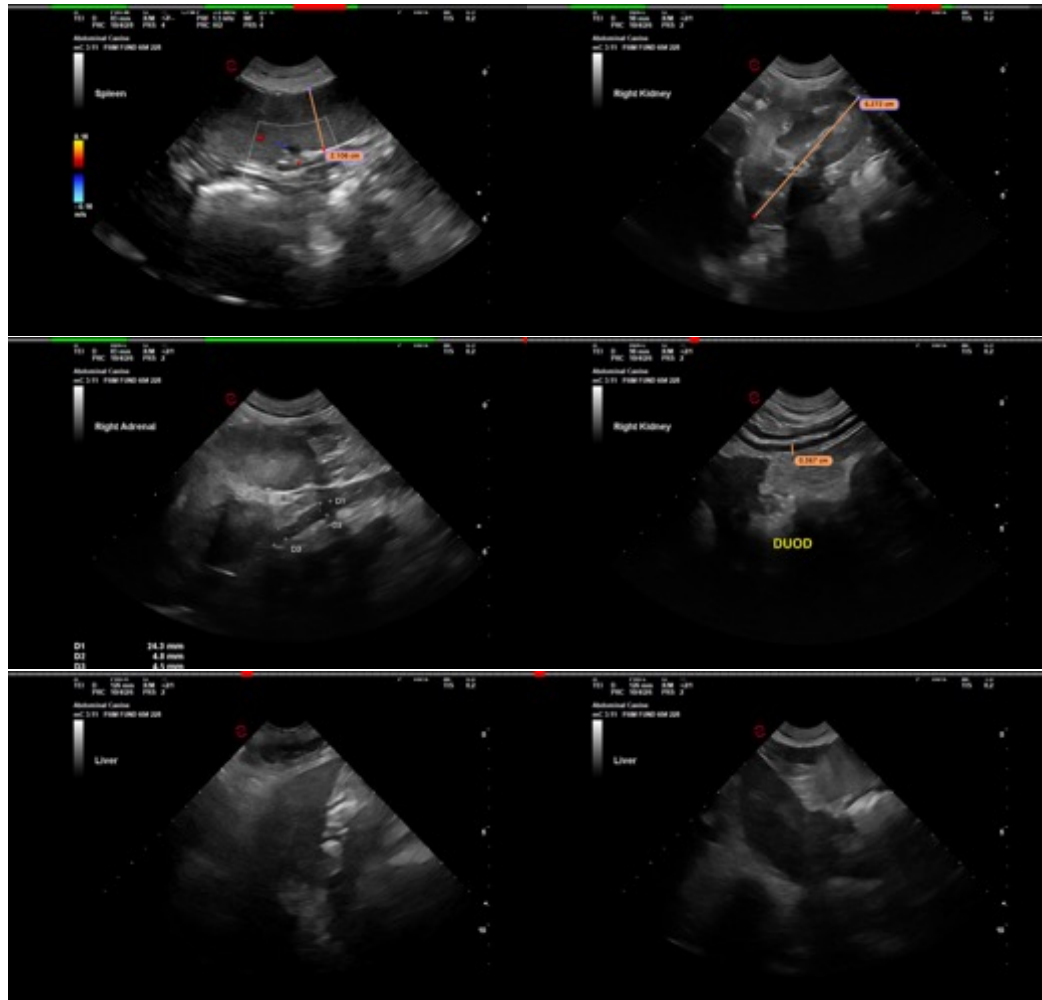
Dr. Smith

INVOICE

10818

DATE

11/25/2025



The information and recommendations provided are based on the images presented by the referring veterinarian/sonographer. No evaluation can be communicated regarding pathology that was not visible in the image/video clips provided.

Thank you for this referral. If the clinical or image interpretation does not parallel your findings or if I can be of any further assistance please contact me.

Kathleen Sennello DVM,MS, Diplomate ACVIM (Small animal Internal Medicine)

info@sonopath.com