

**DATE PRESENTING CLINICAL SIGNS**

11/25/22

Saw rDVM yesterday for diarrhea and decreased appetite. Bloodwork sent out; results back this morning and has elevated amylase/lipase and is azotemic. 4 DX negative

**PATIENT**

Roxy Spangler

Current Medications: Unasyn, Buprenorphine, Cerenia.

Lab Results: Creatinine - 4.9; BUN - 128; Amylase 2049; Lipase > 1800; SDMA - 32

Radiographs: Stomach full of ingesta; large amount stool in colon containing opaque materials

Date of Previous IntraPet Ultrasound: No previous.

**SPECIES**

Canine

Sedation: Not required to complete full diagnostic ultrasound.

Stat Report: STAT requested.

**BREED**

Pomeranian X

**ULTRASONOGRAPHIC EXAMINATION OF THE ABDOMEN****SEX**

Spayed Female

**Urinary System**

The urinary bladder is moderately distended with anechoic urine. The Bladder wall, trigone, ureteral papillae and visible urethra (to a depth of 2cm) appear normal with no evidence of wall thickening, mucosal irregularities, masses or cystic calculi.

**AGE**

10/1/10

The left kidney has a normal shape and size (3.19 cm) with a large cortical cyst measuring 0.74 cm, pyelectasia at 0.25 cm, and numerous non-obstructive nephroliths visualized. Overall echogenicity is slightly hyperechoic with poor corticomedullary distinction and a typical 1:3 cortex:medulla ratio. There is no evidence of focal perinephric inflammation or effusion. There is no evidence of infarcts or hydroureter. Renal vasculature is normal.

**WEIGHT**

9.6 Pounds

The right kidney has a normal shape and size (3.13 cm) with a cortical cyst measuring 0.64 cm and numerous non-obstructive nephroliths, the largest of which measures 0.30 cm. Overall echogenicity is slightly hyperechoic with poor corticomedullary distinction and a typical 1:3 cortex:medulla ratio. There is no evidence of focal perinephric inflammation or effusion. There is no evidence of pyelectasia, infarcts or hydroureter. Renal vasculature is normal.

**INTERPRETED BY**

Kathleen Sennello DVM,  
MS, Diplomate ACVIM  
(Small Animal Internal  
Medicine)

**Adrenal Glands**

The left adrenal gland is normal in size measuring 0.67 cm at the caudal pole. It is observed in its normal position cranial to the left renal artery. It is normal in appearance (uniformly hypoechoic) and shape with no evidence of a mass effect.

**IMAGING PERFORMED BY**

Rachel Brilhart RDMS

The right adrenal gland is normal in size measuring 0.69 cm at the caudal pole. It is observed in its normal position between the cranial aspect of the right kidney and the caudal vena cava. It is normal in appearance (uniformly hypoechoic) and shape with no evidence of a mass effect.

**HOSPITAL NAME**

Animal Emergency  
Hospital

**Spleen**

The spleen is subjectively normal in size, echotexture is homogenous, and the splenic capsule is smooth with no irregularities. The blood flow through the hilus and splenic parenchyma appears normal. No focal parenchymal abnormalities are visualized.

**REFERRING VET**

Dr. Martinoli

**Liver**

The liver is subjectively normal in size, and echogenicity with smooth peripheral margins. The parenchyma is heterogenous in echotexture with subtle, indistinct focal mottling. The visible portions of the vasculature and biliary tract appear normal. No focal nodules or cystic lesions are observed.

**INVOICE**

42957

The gall bladder lumen is moderately distended. The wall of the gall bladder is thickened and has a smooth mucosal surface, measuring 0.30 cm. There is a moderate amount of non-organized echogenic debris. The cystic and common bile ducts are normal/not visible.

### ***Gastrointestinal***

The stomach is moderately dilated with fluid and irregular shadowing material most consistent with normal ingesta and gas. It measures at a normal thickness of <0.7cm with some variability due to the presence of rugal folds. The distinction of the gastric wall layering is adequate and there is no impression of reduced peristaltic activity. No masses or focal lesions were observed.

The visualized areas of duodenum, jejunum and ileum have a relatively uniform diameter with minimal fluid distension. Wall thickness is normal. Bowel loops follow a curvilinear path with distinct wall layering maintaining the typical 1:3 muscularis:mucosa layer ratio. The duodenum measured as normal (between 0.3-0.5cm in wall thickness) and the jejunum measured as normal (between 0.2-0.47cm.) Visualized peristalsis appears appropriate. There were no focal lesions consistent with obstruction or a mass effect observed.

The ileocecal junction was visualized and exhibited normal intact wall layering and is subjectively of normal thickness. Sections of colon are visualized with formed fecal material and gas shadowing distally. There is no observed focal or generalized colon wall thickening or loss of layering.

### ***Pancreas***

The pancreas is prominent and mottled compared to the surrounding isoechoic mesentery. The parenchyma has numerous ill-defined hypoechoic regions, almost consistent with ill-defined nodules. The pancreatic duct is prominent at 0.28 cm. There is no evidence of regional mesenteric inflammation or fluid.

### ***Free Abdomen***

Evaluation of the peritoneal cavity did not reveal any evidence of effusion, or subjective lymphadenomegaly. The Medial iliac nodes appear normal and there was no evidence of a caudal aortic thrombus at the bifurcation. The omentum is of normal uniform echogenicity.

### ***Other***

Occasional ringdown artifact is visualized at the level of the diaphragm. Recommend 3-view thoracic radiographs.

## **ULTRASONOGRAPHIC FINDINGS**

- Decreased corticomedullary distinction in both kidneys with non-obstructive nephroliths, cortical cysts, and mild left-sided pyelectasia – Mild loss of corticomedullary distinction in both kidneys could be consistent with chronic degenerative disease or interstitial nephrosis. Pyelectasia of the kidney(s) could be consistent with pyelonephritis, chronic renal disease, secondary to PU/PD or fluid therapy (if applicable), other.
- Prominent, mottled pancreas with ill-defined nodules and a prominent pancreatic duct – The pancreatic changes are most consistent with mild pancreatitis or a recent episode of pancreatic inflammation. These do not appear to be discrete nodules or masses, but if symptoms persist consider a fine needle aspirate of the pancreas.
- Heterogeneous liver – The diffuse hepatic changes are non-specific and could be consistent with vacuolar hepatopathy, nodular hyperplasia, inflammatory/immune-mediated disease, fibrosis, extramedullary hematopoiesis, toxic hepatopathy (e.g., copper), infiltrative neoplasia (less likely) or other hepatopathy.
- Thickened gallbladder wall with a moderate amount of gallbladder debris – Findings could be consistent with inflammation, edema, etc. Recommend starting chronic Ursodiol therapy and continuing to monitor the gallbladder with ultrasound for progression of this lesion.

- Ringdown artifact visualized at the level of the diaphragm – This can be seen with pulmonary parenchymal disease. Recommend 3-view thoracic radiographs.

## INTERPRETATION OF THE FINDINGS & FURTHER RECOMMENDATIONS

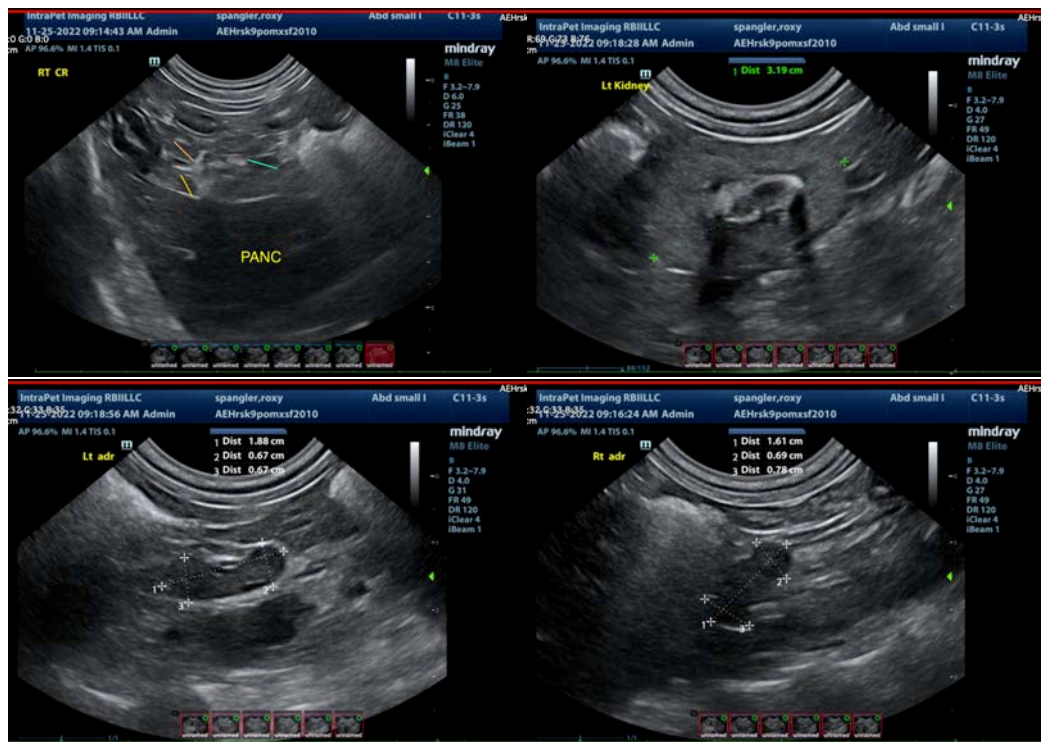
The changes in the kidneys are consistent with progressive chronic renal disease. Recommend a blood pressure, urinalysis and culture as a baseline. The current azotemia could be due to chronic progression of the renal disease or could be due to an acute on chronic crisis. Evaluate for any inciting causes such as nephrotoxic medications, infection, etc., and consider diuresis with treatment for uremia.

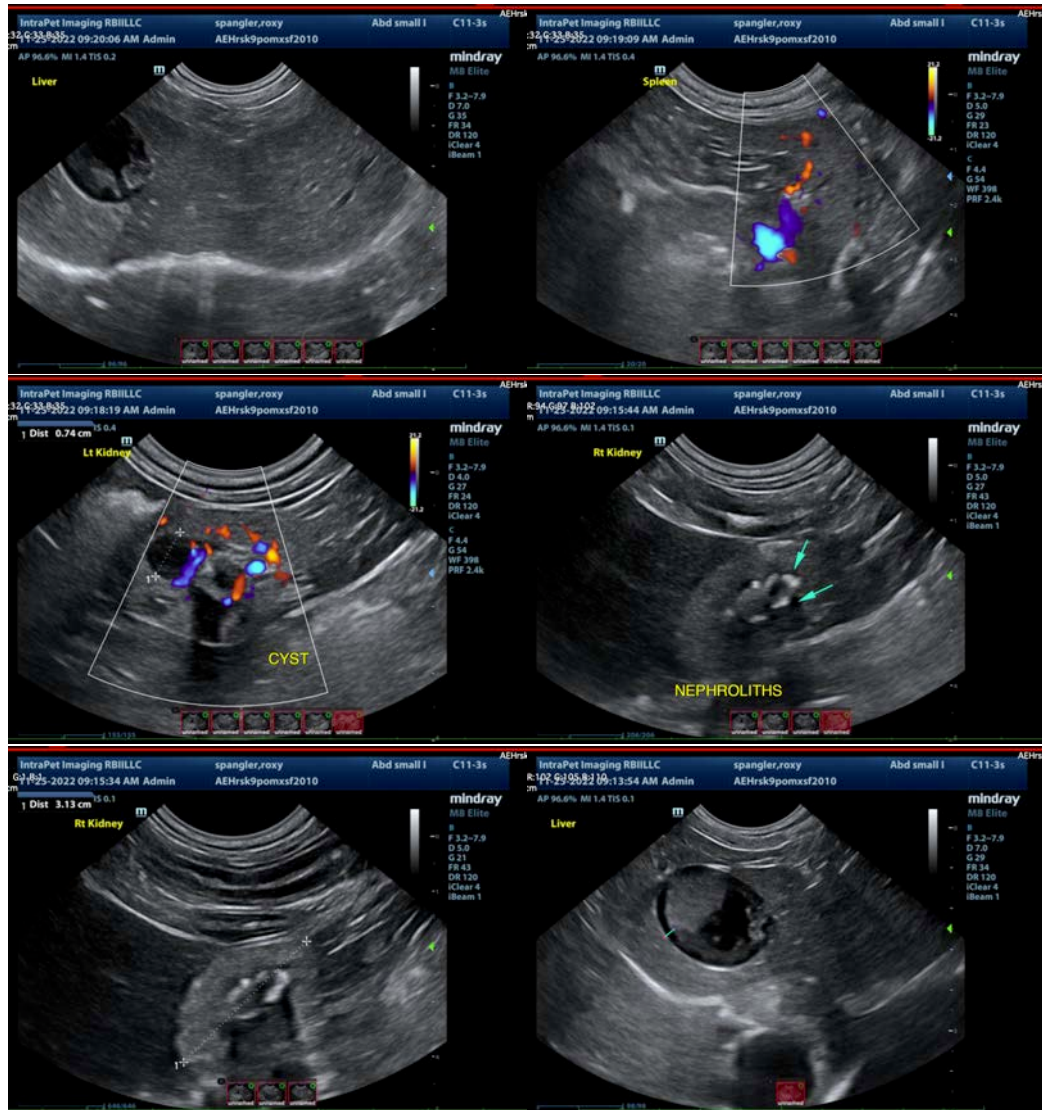
The pancreas is somewhat prominent and almost nodular in appearance, but there is minimal surrounding inflammation. Recommend continued monitoring of this lesion and a fine needle aspirate of the pancreas if symptoms persist.

The liver is mildly heterogeneous. This is a non-specific finding and can be seen in some older pets. No focal hepatic lesions were observed. Further evaluation could involve a liver function test and a fine needle aspirate of the liver.

The gallbladder wall appears slightly hypoechoic and thickened. This could be secondary to inflammation (cholecystitis) or could be edema, etc. Consider chronic Ursodiol therapy and continued monitoring of the gallbladder for progression of this lesion to a mucocele, etc.

Recommend three view thoracic radiographs to evaluate for possible concurrent thoracic disease/involvement.





The information and recommendations provided are based on the images presented by the referring veterinarian/sonographer. No evaluation can be communicated regarding pathology that was not visible in the image/video clips provided.

Thank you for this referral. If the clinical or image interpretation does not parallel your findings or if I can be of any further assistance please contact me.

Kathleen Sennello DVM,MS, Diplomate ACVIM (Small animal Internal Medicine)  
 kathleen.sennello@sonopath.com