

PATIENT

Winston Shaw

SPECIES

Canine

BREED

English Bulldog

SEX

Neutered Male

AGE

10 Years

WEIGHT

24.7 kg

INTERPRETED BY

Kathleen Sennello
DVM, MS, Diplomate
ACVIM (Small Animal
Internal Medicine)

**IMAGING
PERFORMED BY**

Kelly Reschny

HOSPITAL NAME

Buck Animal Hospital

REFERRING VET

Dr. Galbrath

INVOICE

33100

DATE

11/25/21

PRESENTING CLINICAL SIGNS

Lethargic, hunched, trembling - pendulous belly with fluid wave - possible arrhythmia - abdominal tap: not frank blood, serosanguinous with a hint of blood. spin down and saw possible neoplastic cells.
Abnormal PE/Chem/CBC/UA Results: anemia

ULTRASONOGRAPHIC EXAMINATION OF THE ABDOMEN

Urinary System

The urinary bladder is moderately distended with anechoic urine. The bladder wall is largely normal, but in the apical portion there is mild thickening and irregularity, measuring at a thickness of 0.56 cm. The area of the trigone, ureteral papillae, and proximal urethral to a depth of 2.0 cm appear normal in thickness with no significant mucosal irregularities, mass effects, or cystic calculi. Findings are mild and most consistent with either cystitis or lack of full urine distention.

The prostate is normal in size (0.87 cm) and shape for this neutered male dog. The parenchyma is homogenous and the external margins are smooth. The prostatic urethra appears normal with no evidence of irregularity, invasion, mass effect or calculi.

The right kidney has a normal shape and size (4.82 cm). Overall echogenicity is normal with adequate corticomedullary distinction and a typical 1:3 cortex:medulla ratio. There is no evidence of pyelectasia, nephroliths, infarcts or hydronephrosis. Renal vasculature is normal.

The left kidney has a normal shape and size (4.66 cm). Overall echogenicity is normal with adequate corticomedullary distinction and a typical 1:3 cortex:medulla ratio. There is no evidence of pyelectasia, nephroliths, infarcts or hydronephrosis. Renal vasculature is normal.

Adrenal Glands

The left adrenal gland is normal in size measuring 0.77 cm. It is observed in its normal position cranial to the left renal artery. It is normal in appearance (uniformly hypoechoic) and shape with no evidence of a mass effect.

The region of the right adrenal (between right cranial kidney and vena cava) is unremarkable, but the adrenal is not distinctly visualized. No evidence of a mass effect.

Spleen

The spleen echotexture is homogenous, and the splenic capsule is smooth with no irregularities. The spleen is subjectively normal in size with no focal parenchymal abnormalities. The blood flow through the hilus and splenic parenchyma appears normal.

Liver

The liver is large in size and irregular. The parenchyma is heterogenous in echotexture with subtle, indistinct focal mottling. The visible portions of the vasculature and biliary tract appear normal. No focal nodules or cystic lesions are observed.

The gall bladder lumen is moderately distended. The wall of the gall bladder is not thickened and has a smooth mucosal surface. Luminal contents are primarily anechoic. The cystic and common bile ducts are normal/not visible.


PATIENT

Winston Shaw

SPECIES

Canine

BREED

English Bulldog

SEX

Neutered Male

AGE

10 Years

WEIGHT

24.7 kg

INTERPRETED BY

 Kathleen Sennello
 DVM, MS, Diplomate
 ACVIM (Small Animal
 Internal Medicine)

**IMAGING
 PERFORMED BY**

Kelly Reschny

HOSPITAL NAME

Buck Animal Hospital

REFERRING VET

Dr. Galbrath

INVOICE

33100

DATE

11/25/21

Gastrointestinal

The stomach appears contains minimal luminal contents. It measures slightly thickened in some areas at 0.73 cm (normal is <0.7 cm) with some variability due to the presence of rugal folds. The distinction of the gastric wall layers is largely normal. there is no evidence of reduced peristaltic activity. No focal lesions are observed. Findings are most consistent with gastritis or infiltrative disease, but could be normal in this individual.

The visualized areas of duodenum, jejunum and ileum have a relatively uniform diameter with minimal fluid distension. Wall thickness is normal. Bowel loops follow a curvilinear path with distinct wall layering maintaining the typical 1:3 muscularis:mucosa layer ratio. Visualized peristalsis appears appropriate. There were no focal lesions consistent with obstruction or a mass effect observed.

The ileocecal junction was visualized and exhibited normal intact wall layering and is subjectively of normal thickness. Sections of colon are visualized with formed fecal material and gas shadowing distally. There is no observed focal or generalized colon wall thickening or loss of layering.

Pancreas

The area of the pancreas is normal and isoechoic to surrounding mesentery. There is no evidence of nodules or cystic lesions. There is no evidence of regional mesenteric inflammation or fluid.

Free Abdomen

There is a large amount of hypoechoic free abdominal fluid. No lymphadenopathy noted. The omentum is of normal echogenicity.

PRIMARY FINDINGS

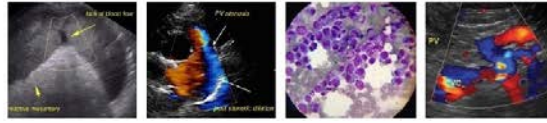
- Large, heterogeneous liver – The diffuse hepatic changes are non-specific and could be consistent with vacuolar hepatopathy, nodular hyperplasia, inflammatory/immune-mediated disease, fibrosis, extramedullary hematopoiesis, toxic hepatopathy (e.g., copper), infiltrative neoplasia (less likely) or other hepatopathy.
- Large volume free abdominal fluid – This could be consistent with hypoalbuminemia and neoplastic effusion, liver disease, heart disease, peritonitis, etc. Recommend sampling and fluid analysis, cytology +/- culture.

SECONDARY FINDINGS

- Questionable apical thickening of the urinary bladder wall – The bladder mucosal changes could be consistent with cystitis or artifactual due to lack of adequate luminal distension. Bladder neoplasia cannot be ruled out but is considered unlikely in this patient.
- Questionable gastric wall thickening – The stomach wall thickening could be consistent with inflammation, edema, infiltrative neoplasia, imaging artifact due to rugal folds, other.

INTERPRETATION OF THE FINDINGS & FURTHER RECOMMENDATIONS

An obvious source for the free fluid in the abdomen is not noted. Recommend fluid analysis, cytology +/- culture to obtain more details on the type of effusion present. Recommend baseline bloodwork and thoracic radiographs. Consider cardiac ultrasound to the historical information of a possible arrhythmia present. If the heart is normal, then consider a fine needle aspirate of the liver and liver function test.



PATIENT

Winston Shaw

SPECIES

Canine

BREED

English Bulldog

SEX

Neutered Male

AGE

10 Years

WEIGHT

24.7 kg

INTERPRETED BY

Kathleen Sennello
DVM, MS, Diplomate
ACVIM (Small Animal
Internal Medicine)

**IMAGING
PERFORMED BY**

Kelly Reschny

HOSPITAL NAME

Buck Animal Hospital

REFERRING VET

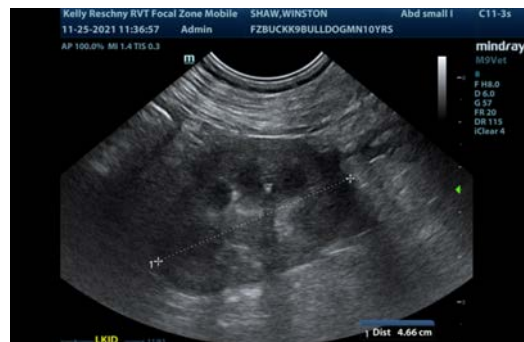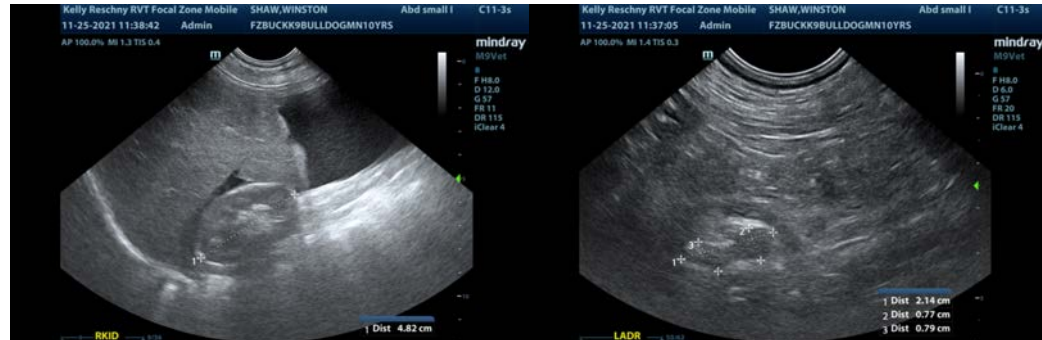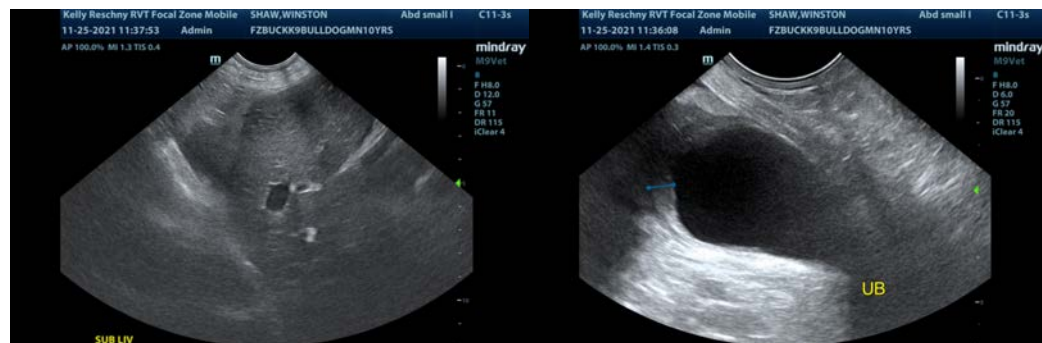
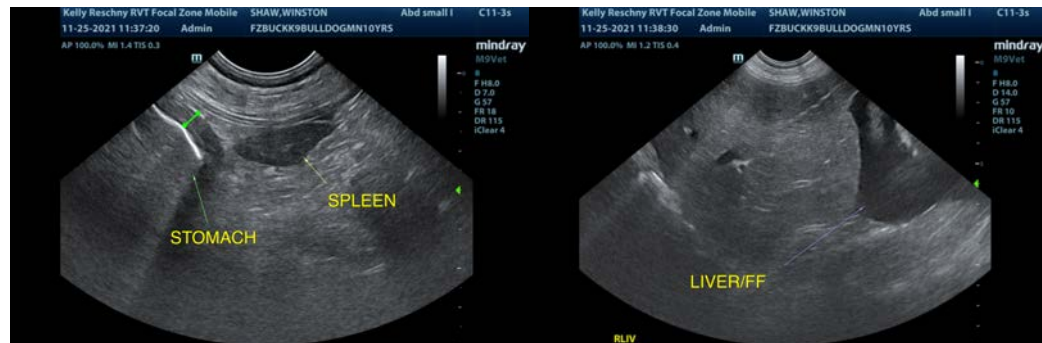Dr. Galbrath

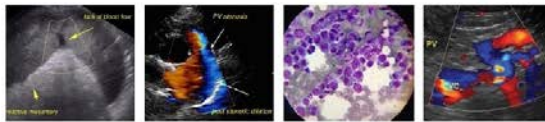
INVOICE

33100

DATE

11/25/21





PATIENT

Winston Shaw

The information and recommendations provided are based on the images presented by the referring veterinarian. No evaluation can be communicated regarding pathology that was not visible in the image/video clips provided.

SPECIES

Canine

Thank you for this referral. If the clinical or image interpretation does not parallel your findings or if I can be of any further assistance please contact me.

BREED

English Bulldog

Kathleen Sennello DVM, MS, Diplomate ACVIM (Small Animal Internal Medicine)
info@sonopath.com

SEX

Neutered Male

AGE

10 Years

WEIGHT

24.7 kg

INTERPRETED BY

Kathleen Sennello
DVM, MS, Diplomate
ACVIM (Small Animal
Internal Medicine)

**IMAGING
PERFORMED BY**

Kelly Reschny

HOSPITAL NAME

Buck Animal Hospital

REFERRING VET

Dr. Galbrath

INVOICE

33100

DATE

11/25/21