



**PATIENT**

Puca Brownson

**SPECIES**

Canine

**BREED**

Pomeranian

**SEX**

Spayed Female

**AGE**

14 Years

**WEIGHT**

5.18 Pounds

**INTERPRETED BY**

Kathleen Sennello DVM,  
MS, Diplomate ACVIM  
(Small Animal Internal  
Medicine)

**IMAGING  
PERFORMED BY**

Carissa Rhoades

**HOSPITAL NAME**

Elizabeth AH

**REFERRING VET**

Dr. Leon Anderson

**INVOICE**

30052

**DATE**

11/24/21

**PRESENTING CLINICAL SIGNS**

Normal Sunday and Monday, low energy and weaker Monday night into Tuesday. Stands with hunched back, not walking, not eating.

Abnormal PE/Chem/CBC/UA Results: PE: Quiet, slightly tacky mm, T 104.8, Hunched posture, mild proprioceptive loss in back limbs, painful to spinal palpation. Stage II dental disease. Lenticular Sclerosis normal for age. CBC: RBC: 5.78 M/uL Chem: ALP 1045 U/L, GGT 43 U/L, ALT not reading- suspect high.

**ULTRASONOGRAPHIC EXAMINATION OF THE ABDOMEN**

**Urinary System**

The urinary bladder is moderately distended with anechoic urine. The Bladder wall, trigone, ureteral papillae and visible urethra (to a depth of 2cm) appear normal with no evidence of wall thickening, mucosal irregularities, masses or cystic calculi.

The left kidney has a normal shape and size (2.79 cm) with pinpoint non-obstructive nephroliths. Overall echogenicity is normal with adequate corticomedullary distinction and a typical 1:3 cortex:medulla ratio. There is no evidence of perinephric inflammation or effusion. There is no evidence of pyelectasia, infarcts or hydroureter. Renal vasculature is normal.

The right kidney has a normal shape and size (2.49 cm) with pinpoint non-obstructive nephroliths. Overall echogenicity is normal with adequate corticomedullary distinction and a typical 1:3 cortex:medulla ratio. There is no evidence of perinephric inflammation or effusion. There is no evidence of pyelectasia, infarcts or hydroureter. Renal vasculature is normal.

**Adrenal Glands**

The left adrenal gland is normal in size measuring 0.50 cm at the caudal pole. It is observed in its normal position cranial to the left renal artery. It is normal in appearance (uniformly hypoechoic) and shape with no evidence of a mass effect.

The right adrenal gland is normal in size measuring 0.56 cm at the caudal pole. It is observed in its normal position between the cranial aspect of the right kidney and the caudal vena cava. It is normal in appearance (uniformly hypoechoic) and shape with no evidence of a mass effect.

**Spleen**

The spleen is subjectively normal in size, echotexture is homogenous, and the splenic capsule is smooth with no irregularities. The blood flow through the hilus and splenic parenchyma appears normal. No focal parenchymal abnormalities are visualized.

**Liver**

The liver is subjectively normal in size, and echogenicity with smooth peripheral margins. The parenchyma is heterogenous in echotexture with subtle, indistinct focal mottling. The visible portions of the vasculature and biliary tract appear normal. No focal nodules or cystic lesions are observed.

The gall bladder lumen is moderately distended. The wall of the gall bladder is not thickened and has a smooth mucosal surface. There is a moderate amount of non-organized echogenic debris. The cystic and common bile ducts are normal/not visible.

**Gastrointestinal**

The stomach contains minimal luminal contents. It measures at a normal thickness of <0.7cm with some variability due to the presence of rugal folds. The distinction of the gastric wall layers is adequate and there is no impression of reduced peristaltic activity. No masses or focal lesions were observed.



**PATIENT**

Puca Brownson

The visualized areas of duodenum, jejunum and ileum have a relatively uniform diameter with minimal fluid distension. Wall thickness is normal. Bowel loops follow a curvilinear path with distinct wall layering maintaining the typical 1:3 muscularis:mucosa layer ratio. The duodenum measured as normal (between 0.3-0.5cm in wall thickness) and the jejunum measured as normal (between 0.2-0.47cm.)

**SPECIES**

Canine

Visualized peristalsis appears appropriate. There were no focal lesions consistent with obstruction or a mass effect observed.

**BREED**

Pomeranian

The ileocecal junction was visualized and exhibited normal intact wall layering and is subjectively of normal thickness. Sections of colon are visualized with formed fecal material and gas shadowing distally. There is no observed focal or generalized colon wall thickening or loss of layering.

**Pancreas**

**SEX**

Spayed Female

The pancreas is normal and isoechoic to surrounding mesentery. There is no evidence of nodules or cystic lesions. There is no evidence of regional mesenteric inflammation or fluid.

**Free Abdomen**

**AGE**

14 Years

Evaluation of the peritoneal cavity did not reveal any evidence of effusion, or subjective lymphadenomegaly. The Medial iliac nodes appear normal and there was no evidence of a caudal aortic thrombus at the bifurcation. The omentum is of normal uniform echogenicity.

**ULTRASONOGRAPHIC FINDINGS**

**WEIGHT**

5.18 Pounds

- Large, heterogeneous liver – The diffuse hepatic changes are non-specific and could be consistent with vacuolar hepatopathy, nodular hyperplasia, inflammatory/immune-mediated disease, fibrosis, extramedullary hematopoiesis, toxic hepatopathy (e.g., copper), infiltrative neoplasia (less likely) or other hepatopathy.

**INTERPRETED BY**

Kathleen Sennello DVM,  
MS, Diplomate ACVIM  
(Small Animal Internal  
Medicine)

- Moderate gallbladder debris – The significance of the aggregated gallbladder sludge is unclear. This could represent an early mucocele, cholestasis, or may be secondary to fasting.

**INTERPRETATION OF THE FINDINGS & FURTHER RECOMMENDATIONS**

The liver is heterogeneous. This is a non-specific finding and is consistent with the ALP elevation reported. These are my recommendations for a patient with a chronic ALP elevation:

**IMAGING PERFORMED BY**

Carissa Rhoades

- Induction phenomena are the most common cause for an elevated ALP. These are systemic illnesses that 'turn on' the liver enzyme. Causes of this include Cushing's disease, dental disease, arthritis, and numerous others. In many cases the exact cause is unclear but as long as ultrasound and bile acids tests are normal most patients do not have progressive changes in their liver. While liver biopsy is not routinely performed, vacuolar hepatopathy, is noted on most biopsies. This is often non-progressive but in rare cases can be more severe and lead to liver failure.

**HOSPITAL NAME**

Elizabeth AH

**REFERRING VET**

Dr. Leon Anderson

- If signs of cushings disease are present recommend endocrine function testing to evaluate for cushings disease.

**INVOICE**

30052

- Consider fine needle aspirate to rule out round cell neoplasia -if this is a concern.

**DATE**

11/24/21

- If a cause for the ALP elevation is not identified: I recommend recheck general blood work every 6 months, ultrasound once per year, and bile acids test every 1-2 years based on other results. If the ALP continues to climb a biopsy could be considered.

- Consider long term use of denamarin, and monitoring for the signs of cushings developing.



**PATIENT**

Puca Brownson

- A primary vacuolar hepatopathy can be breed related and is seen in Scottish Terriers, Schnauzers, Cocker spaniels etc.

**SPECIES**

Canine

With the history of the elevated body temperature and acute signs/hunched back, this makes me concerned for possible discospondylitis (recommend spinal radiographs +/- advanced imaging, urine culture and urinalysis), or possible pancreatitis. Consider a quantitative PLI, TLI, cobalamin and folate to Texas A&M University. I suspect the liver enzyme elevations may be chronic and incidental, but further workup is indicated. No focal hepatic or abdominal lesions are noted.

**BREED**

Pomeranian

**SEX**

Spayed Female

**AGE**

14 Years

**WEIGHT**

5.18 Pounds

**INTERPRETED BY**

Kathleen Sennello DVM, MS, Diplomate ACVIM (Small Animal Internal Medicine)

**IMAGING PERFORMED BY**

Carissa Rhoades

**HOSPITAL NAME**

Elizabeth AH

**REFERRING VET**

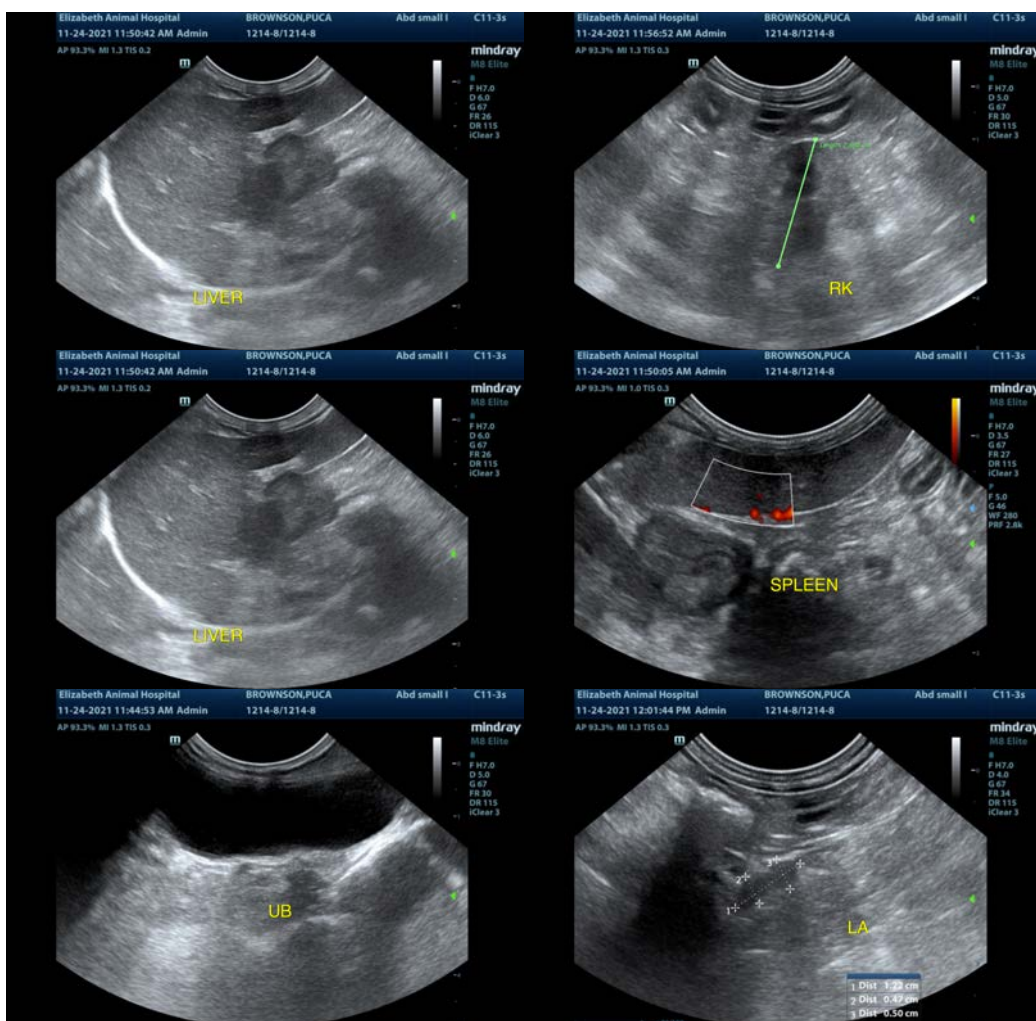
Dr. Leon Anderson

**INVOICE**

30052

**DATE**

11/24/21





**PATIENT**

Puca Brownson

**SPECIES**

Canine

**BREED**

Pomeranian

**SEX**

Spayed Female

**AGE**

14 Years

**WEIGHT**

5.18 Pounds

**INTERPRETED BY**

Kathleen Sennello DVM,  
MS, Diplomate ACVIM  
(Small Animal Internal  
Medicine)

**IMAGING  
PERFORMED BY**

Carissa Rhoades

**HOSPITAL NAME**

Elizabeth AH

**REFERRING VET**

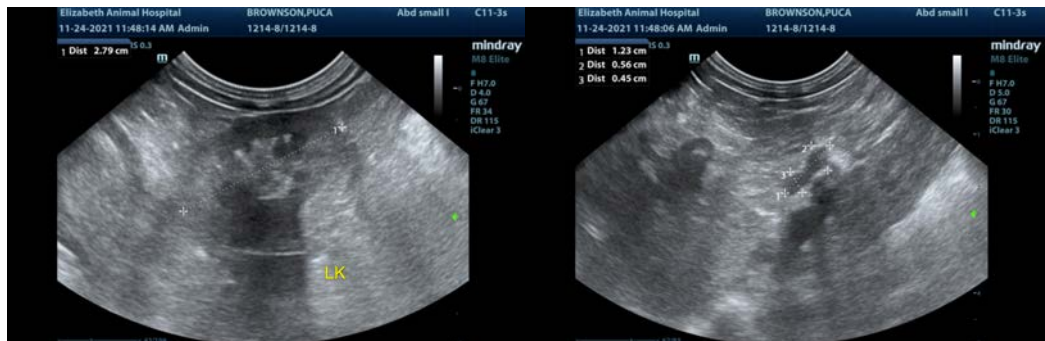
Dr. Leon Anderson

**INVOICE**

30052

**DATE**

11/24/21



The information and recommendations provided are based on the images presented by the referring veterinarian. No evaluation can be communicated regarding pathology that was not visible in the image/video clips provided.

Thank you for this referral. If the clinical or image interpretation does not parallel your findings or if I can be of any further assistance please contact me.

Kathleen Sennello DVM,MS, Diplomate ACVIM (Small animal Internal Medicine)  
kathleen.sennello@sonopath.com