



PATIENT PRESENTING CLINICAL SIGNS

PATIENT
Kirby Taylor

SPECIES
Canine

BREED
Beagle

SEX
Neutered Male

AGE
7 Years

WEIGHT
13 Pounds

7 year old male neutered beagle. Trazodone PRN for anxiety. 11/23/21 Ate dinner, was doing well. Yelled out in pain at home. Started having hematuria 11/23 and it happened twice. Large amount of urine was produced. Had two episodes of accidents in the house in the last month but that was only after pet sitter came after 8 hours. VEG findings 11/24/21 (early morning ~3 AM): Patient is slightly painful in the mid- abdomen. Rectal wnl. urine on cystocentesis was slightly cloudy but not grossly hematuric. Blood present in the urinalysis. VEG sending out urine for culture. USG is 1.010. Radiographs (CxR and AxR) wnl. Started on Clavamox 250 mg PO BID and Gabapentin 100 mg SID ~4 AM 11/24/21. Non-painful palpation as of 11/24 @ 1 pm. prostate palpates wnl. Abnormal PE/Chem/CBC/UA Results: USG 1.010, hematuria,

ULTRASONOGRAPHIC EXAMINATION OF THE ABDOMEN

Urinary System

The urinary bladder is moderately distended with mildly echogenic urine. The Bladder wall appears mildly thickened and slightly irregular. The area of the trigone and ureteral papillae appear normal, and the visible urethra (to a depth of 2cm) appears mildly thickened, measuring 0.86 cm in diameter and 0.39 cm in wall thickness. No focal masses or cystic calculi observed.

It is difficult to clearly visualize the prostate, likely due to an intrapelvic location. Based on imaging, suspected size is approximately 1.2 cm, which seems large for a patient of this size unless neutered later in life. Detailed evaluation of the prostate is not possible.

The left kidney has a normal shape and size (5.64 cm). Overall echogenicity is normal with adequate corticomedullary distinction and a typical 1:3 cortex:medulla ratio. There is no evidence of perinephric inflammation or effusion. There is no evidence of pyelectasia, nephroliths, infarcts or hydroureter. Renal vasculature is normal.

The right kidney has a normal shape and size (6.21 cm). Overall echogenicity is normal with adequate corticomedullary distinction and a typical 1:3 cortex:medulla ratio. There is no evidence of perinephric inflammation or effusion. There is no evidence of pyelectasia, nephroliths, infarcts or hydroureter. Renal vasculature is normal.

INTERPRETED BY

Kathleen Sennello DVM,
MS, Diplomate ACVIM
(Small Animal Internal
Medicine)

IMAGING PERFORMED BY

Sorbo

HOSPITAL NAME

Back Bay VC

REFERRING VET

Dr. Sager-Gellerman

INVOICE

30055

DATE

11/24/21

Adrenal Glands

The left adrenal gland is normal in size measuring 0.52 cm at the caudal pole. It is observed in its normal position cranial to the left renal artery. It is normal in appearance (uniformly hypoechoic) and shape with no evidence of a mass effect.

The region of the right adrenal (between right cranial kidney and vena cava) is unremarkable, but the adrenal is not distinctly visualized. No evidence of a mass effect.

Spleen

The spleen is subjectively normal in size, echotexture is homogenous, and the splenic capsule is smooth with no irregularities. The blood flow through the hilus and splenic parenchyma appears normal. No focal parenchymal abnormalities are visualized.

Liver

The liver is subjectively normal in size, and echogenicity with smooth peripheral margins. The parenchyma is heterogenous in echotexture with subtle, indistinct focal mottling. The visible portions of the vasculature and biliary tract appear normal. No focal nodules or cystic lesions are observed.



PATIENT

Kirby Taylor

The gallbladder lumen is moderately distended. The wall of the gall bladder is not thickened and has a smooth mucosal surface. Luminal contents are primarily anechoic. The cystic and common bile ducts are normal/not visible.

SPECIES

Canine

Gastrointestinal

The stomach is moderately dilated with fluid and irregular shadowing material most consistent with normal ingesta and gas. It measures at a normal thickness of <0.7cm with some variability due to the presence of rugal folds. The distinction of the gastric wall layering is adequate and there is no impression of reduced peristaltic activity. No masses or focal lesions were observed.

BREED

Beagle

The visualized areas of duodenum, jejunum and ileum have a relatively uniform diameter with minimal fluid distension. Wall thickness is normal. Bowel loops follow a curvilinear path with distinct wall layering maintaining the typical 1:3 muscularis:mucosa layer ratio. The duodenum measured as normal (between 0.3-0.5cm in wall thickness) and the jejunum measured as normal (between 0.2-0.47cm.)

SEX

Neutered Male

Visualized peristalsis appears appropriate. There were no focal lesions consistent with obstruction or a mass effect observed.

AGE

7 Years

The ileocecal junction was visualized and exhibited normal intact wall layering and is subjectively of normal thickness. Sections of colon are visualized with formed fecal material and gas shadowing distally. There is no observed focal or generalized colon wall thickening or loss of layering.

Pancreas

WEIGHT

13 Pounds

The pancreas is normal and isoechoic to surrounding mesentery. There is no evidence of nodules or cystic lesions. There is no evidence of regional mesenteric inflammation or fluid.

Free Abdomen

INTERPRETED BY

Kathleen Sennello DVM,
MS, Diplomate ACVIM
(Small Animal Internal
Medicine)

Evaluation of the peritoneal cavity did not reveal any evidence of effusion, or subjective lymphadenomegaly. The Medial iliac nodes appear normal and there was no evidence of a caudal aortic thrombus at the bifurcation. The omentum is of normal uniform echogenicity.

ULTRASONOGRAPHIC FINDINGS

IMAGING PERFORMED BY

Sorbo

HOSPITAL NAME

Back Bay VC

REFERRING VET

Dr. Sager-Gellerman

- Mildly irregular urinary bladder wall with mildly echogenic urine – Recommend urinalysis and culture to look for evidence of cystitis.
- Suspect prominent prostate – correlate with the age of neutering. These findings could be normal in this individual or could be consistent with prostatic disease (in a neutered dog, concern for underlying neoplasia).
- Heterogeneous liver – The diffuse hepatic changes are non-specific and could be consistent with vacuolar hepatopathy, nodular hyperplasia, inflammatory/immune-mediated disease, fibrosis, extramedullary hematopoiesis, toxic hepatopathy (e.g., copper), infiltrative neoplasia (less likely) or other hepatopathy.
- Gastric lumen dilated with ingesta – correlate with feeding history. If the patient was adequately fasted, consider such differentials as delayed gastric emptying or partial gastric obstruction (none observed).

INVOICE

30055

INTERPRETATION OF THE FINDINGS & FURTHER RECOMMENDATIONS

DATE

11/24/21

Based on the history provided, I am concerned about possible prostatic disease. Full evaluation of the prostate is difficult likely due to its intrapelvic location. There is the suggestion that it is large.



PATIENT

Kirby Taylor

Recommend urinalysis and culture. If prostatic disease is suspected based on radiographs and rectal evaluation, consider urine BRAF test. If positive, this would increase suspicion for prostatic neoplasia. If negative, additional diagnostics would be necessary, such as a fine needle aspirate of the prostate.

SPECIES

Canine

The changes observed in the liver are non-specific and could be age related. Correlate with blood work findings. If additional imaging of the prostate is possible with heavier sedation, I am happy to review additional images.

BREED

Beagle

SEX

Neutered Male

AGE

7 Years

WEIGHT

13 Pounds

INTERPRETED BY

Kathleen Sennello DVM,
MS, Diplomate ACVIM
(Small Animal Internal
Medicine)

IMAGING PERFORMED BY

Sorbo

HOSPITAL NAME

Back Bay VC

REFERRING VET

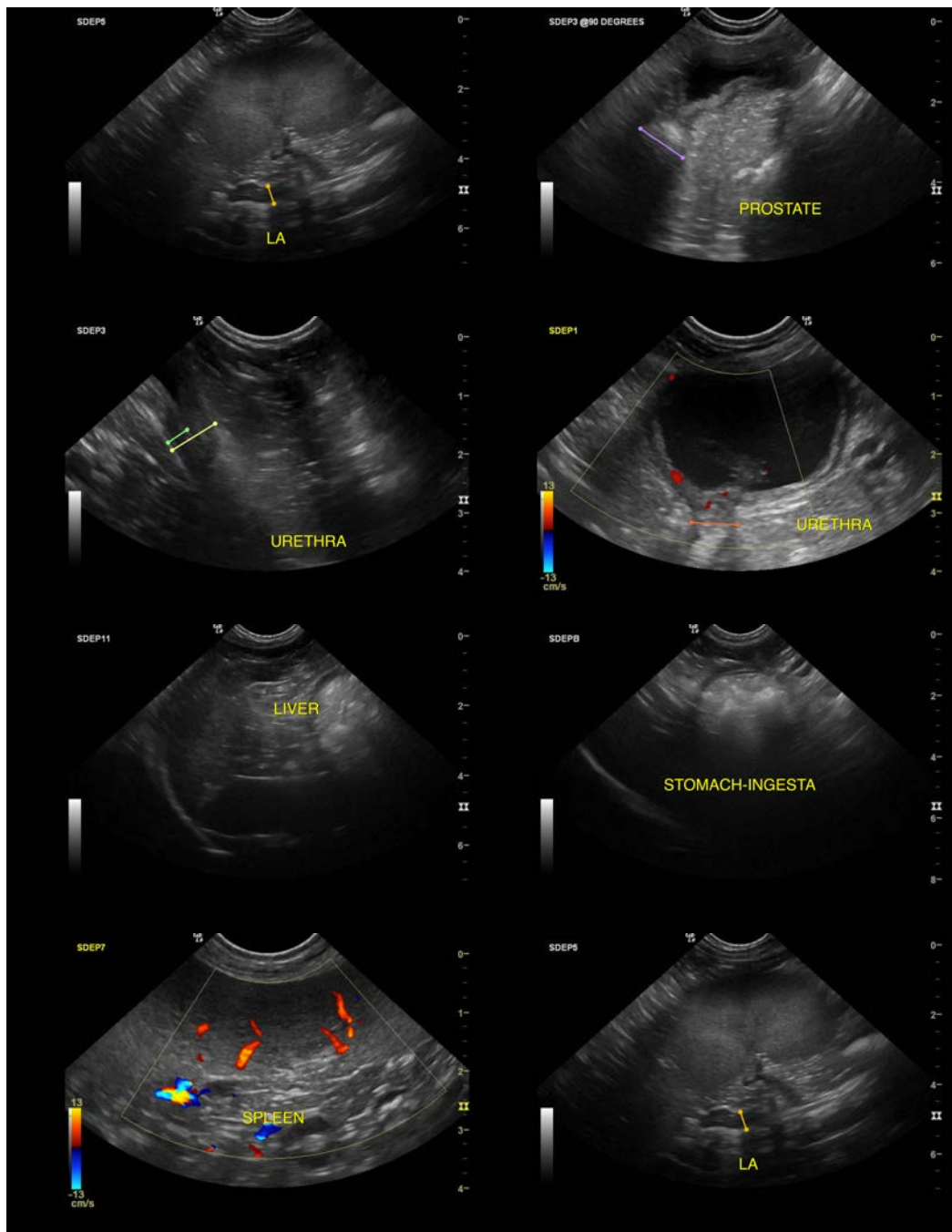
Dr. Sager-Gellerman

INVOICE

30055

DATE

11/24/21





PATIENT

Kirby Taylor

SPECIES

Canine

BREED

Beagle

SEX

Neutered Male

AGE

7 Years

WEIGHT

13 Pounds

INTERPRETED BY

Kathleen Sennello DVM,
MS, Diplomate ACVIM
(Small Animal Internal
Medicine)

**IMAGING
PERFORMED BY**

Sorbo

HOSPITAL NAME

Back Bay VC

REFERRING VET

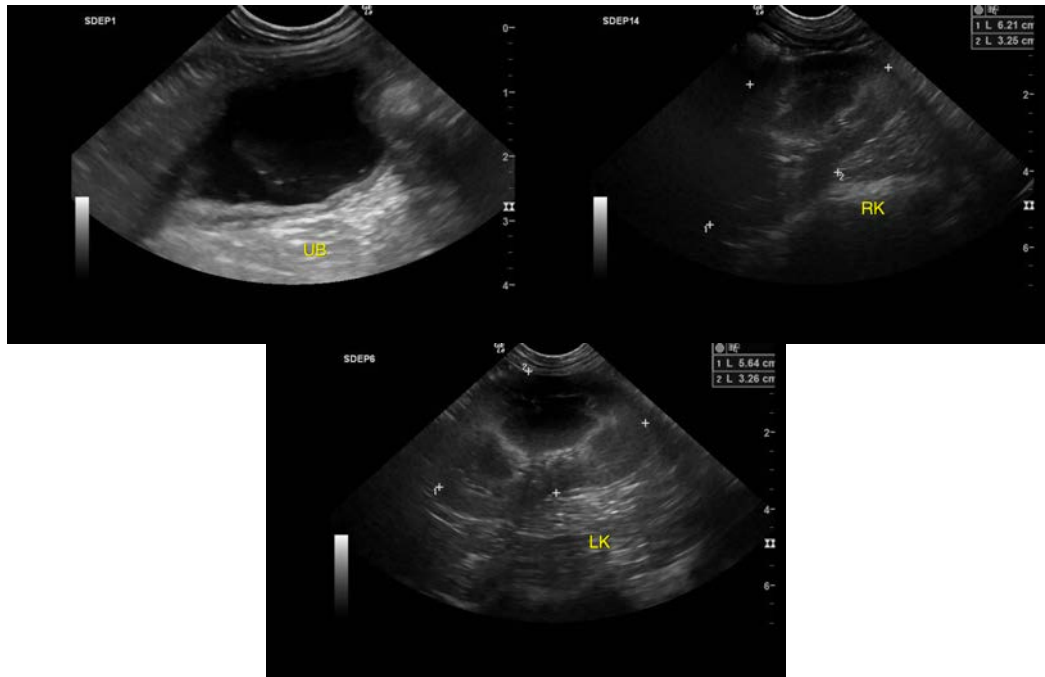
Dr. Sager-Gellerman

INVOICE

30055

DATE

11/24/21



The information and recommendations provided are based on the images presented by the referring veterinarian. No evaluation can be communicated regarding pathology that was not visible in the image/video clips provided.

Thank you for this referral. If the clinical or image interpretation does not parallel your findings or if I can be of any further assistance please contact me.

Kathleen Sennello DVM,MS, Diplomate ACVIM (Small animal Internal Medicine)
kathleen.sennello@sonopath.com