



**PATIENT**

Layla Rodriguez

**SPECIES**

Canine

**BREED**

Australian Shepherd

**SEX**

Spayed Female

**AGE**

9 Years

**WEIGHT**

89 lbs

**INTERPRETED BY**

Kathleen Sennello DVM,  
MS, Diplomate ACVIM  
(Small Animal Internal  
Medicine)

**IMAGING  
PERFORMED BY**

Meghan Morse, LVT,  
CVT

**HOSPITAL NAME**

Farview Animal Clinic

**REFERRING VET**

Dr. Mosaad

**INVOICE**

72009

**DATE**

11/20/25

**PRESENTING CLINICAL SIGNS**

D+, decreased appetite, rads WNL Current meds: Doxycycline  
Abnormal PE/Chem/CBC/UA Results: WBC 21.37, Mono 2, MPV 11.7, RDW 20.4, Neuts 18.42

**ULTRASONOGRAPHIC EXAMINATION OF THE ABDOMEN**

**Urinary System**

The urinary bladder is moderately distended with anechoic urine. The Bladder wall, trigone, ureteral papillae and visible urethra (to a depth of 2cm) appear normal with no evidence of wall thickening, mucosal irregularities, masses or cystic calculi.

The left kidney has a normal shape and size (6.08 cm). Overall echogenicity is normal with adequate corticomedullary distinction and a typical 1:3 cortex:medulla ratio. There is no evidence of focal perinephric inflammation or effusion. There is no evidence of pyelectasia, nephroliths, infarcts or hydroureter. Renal vasculature is normal.

The right kidney has a normal shape and size (6.82 cm). Overall echogenicity is normal with adequate corticomedullary distinction and a typical 1:3 cortex:medulla ratio. There is no evidence of focal perinephric inflammation or effusion. There is no evidence of pyelectasia, nephroliths, infarcts or hydroureter. Renal vasculature is normal.

**Adrenal Glands**

The left adrenal gland is normal in size measuring 0.68 cm at the cranial pole and 0.67 cm at the caudal pole. It is observed in its normal position cranial to the left renal artery. It is normal in appearance (uniformly hypoechoic) and shape with no evidence of a mass effect.

The right adrenal gland is normal in size measuring 1.16 cm at the cranial pole and 0.75 cm at the caudal pole. It is observed in its normal position between the cranial aspect of the right kidney and the caudal vena cava. It is normal in appearance (uniformly hypoechoic) and shape with no evidence of a mass effect.

**Spleen**

The spleen is subjectively normal in size (1.64 cm), echotexture is homogenous, and the splenic capsule is smooth with no irregularities. The blood flow through the hilus and splenic parenchyma appears normal. No focal parenchymal abnormalities are visualized.

**Liver**

The liver is subjectively normal in size, and echogenicity with smooth peripheral margins. The parenchyma is mildly heterogenous in echotexture with subtle, indistinct focal mottling. The visible portions of the vasculature and biliary tract appear normal. No focal nodules or cystic lesions are observed.

The gall bladder lumen is moderately distended. The wall of the gall bladder is not thickened and has a smooth mucosal surface. Luminal contents are mild and likely incidental at this time. The cystic and common bile ducts are normal/not visible.



**PATIENT**

Layla Rodriguez

**SPECIES**

Canine

**BREED**

Australian Shepherd

**SEX**

Spayed Female

**AGE**

9 Years

**WEIGHT**

89 lbs

**INTERPRETED BY**

Kathleen Sennello DVM,  
MS, Diplomate ACVIM  
(Small Animal Internal  
Medicine)

**IMAGING PERFORMED BY**

Meghan Morse, LVT,  
CVT

**HOSPITAL NAME**

Farview Animal Clinic

**REFERRING VET**

Dr. Mosaad

**INVOICE**

72009

**DATE**

11/20/25

***Gastrointestinal***

The stomach contains mild shadowing ingesta/gas. It measures at a normal thickness of <0.7cm with some variability due to the presence of rugal folds. The distinction of the gastric wall layers is adequate and there is no impression of reduced peristaltic activity. No masses or focal lesions were observed.

The visualized areas of duodenum, jejunum and ileum have a relatively uniform diameter with minimal fluid distension. Wall thickness is normal. Bowel loops follow a curvilinear path with distinct wall layering maintaining the typical 1:3 muscularis:mucosa layer ratio. Duodenum wall measures 0.43 cm. Jejunum wall measures 0.24 cm. Visualized peristalsis appears appropriate. There are occasional focal fluid distended bowel loops with no associated lesion visualized.

Sections of colon are visualized with non-formed fecal material and gas shadowing distally. There is no observed focal or generalized colon wall thickening or loss of layering.

***Pancreas***

The pancreas is normal and isoechoic to surrounding mesentery. There is no evidence of nodules or cystic lesions. There is no evidence of regional mesenteric inflammation or fluid.

***Free Abdomen***

Evaluation of the peritoneal cavity did not reveal any evidence of effusion, or subjective lymphadenomegaly. The Medial iliac nodes appear normal and there was no evidence of a caudal aortic thrombus at the bifurcation. The omentum is of normal uniform echogenicity.

**ULTRASONOGRAPHIC FINDINGS**

- Mildly heterogeneous, rounded liver – The significance of this is uncertain in the absence of liver enzyme elevations.
- Fluid distended colon and rare areas of mild fluid distended small intestine.

**INTERPRETATION OF THE FINDINGS & FURTHER RECOMMENDATIONS**

The changes observed on today's scan are very mild. No focal lesions are visualized associated with the GI tract to explain the diarrhea reported. Unfortunately, there are many causes for diarrhea that cannot be definitively diagnosed by ultrasound alone. Consider the following:

- Consider a novel protein/hydrolyzed protein diet (exclusively at least 4-6 weeks)
- Consider a GI panel to Texas A&M for evaluation of B12 levels, folate, PLI/TLI etc.. to further evaluate for pancreatic/small intestinal disease.
- Recommend chronic probiotic therapy.
- If not already done, recommend parasite screening and empirical deworming.
- Consider a panel to screen for infectious causes of diarrhea.

If symptoms are persistent despite taking these measures, biopsies of the GI tract may need to be considered. Additionally, you could consider repeat imaging in the future, looking for the development of new lesions or the progression of today's lesions.



**PATIENT**

Layla Rodriguez

**SPECIES**

Canine

**BREED**

Australian Shepherd

**SEX**

Spayed Female

**AGE**

9 Years

**WEIGHT**

89 lbs

**INTERPRETED BY**

Kathleen Sennello DVM,  
 MS, Diplomate ACVIM  
 (Small Animal Internal  
 Medicine)

**IMAGING  
 PERFORMED BY**

Meghan Morse, LVT,  
 CVT

**HOSPITAL NAME**

Farview Animal Clinic

**REFERRING VET**

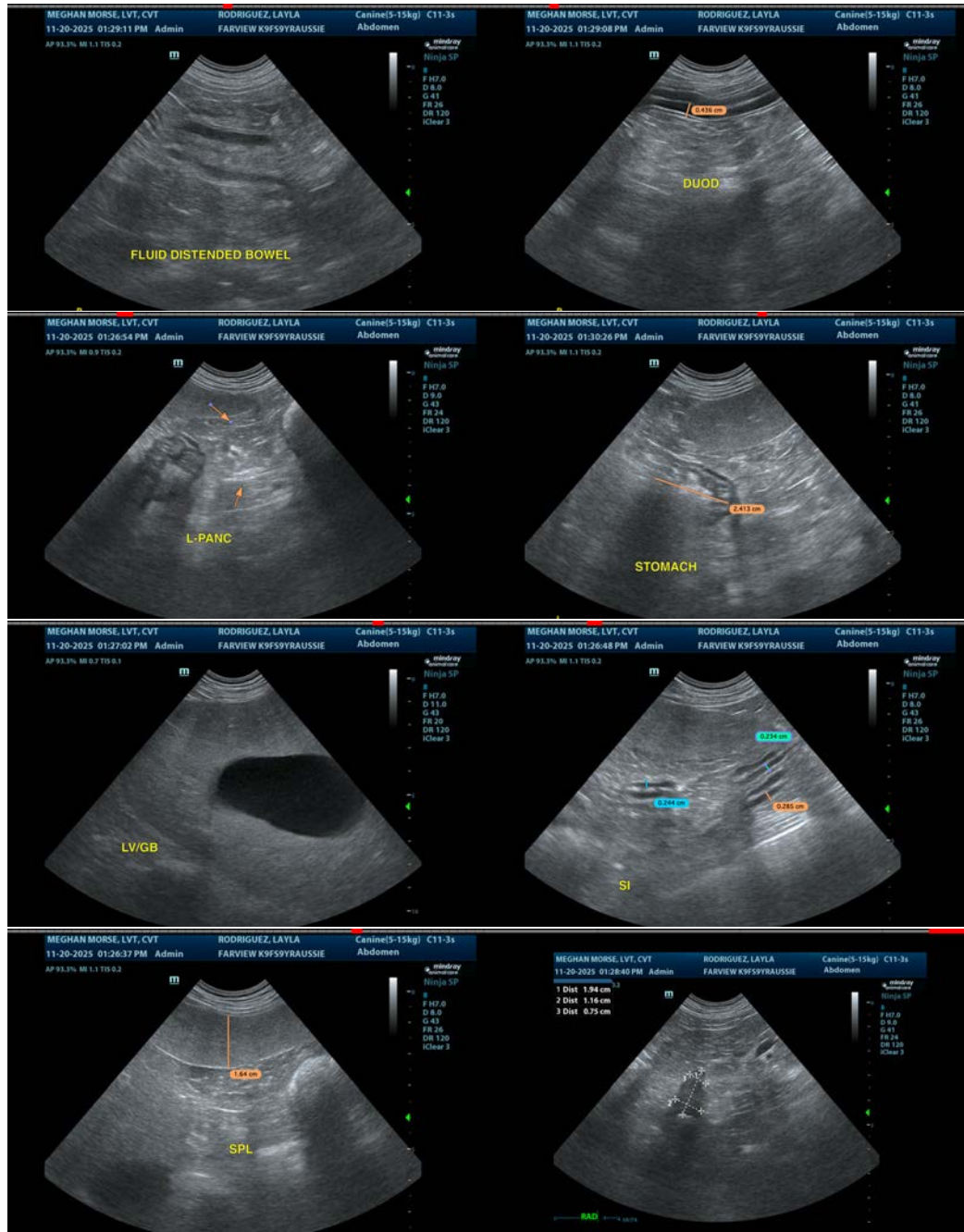
Dr. Mosaad

**INVOICE**

72009

**DATE**

11/20/25





**PATIENT**

Layla Rodriguez

**SPECIES**

Canine

**BREED**

Australian Shepherd

**SEX**

Spayed Female

**AGE**

9 Years

**WEIGHT**

89 lbs

**INTERPRETED BY**

Kathleen Sennello DVM,  
 MS, Diplomate ACVIM  
 (Small Animal Internal  
 Medicine)

**IMAGING PERFORMED BY**

Meghan Morse, LVT,  
 CVT

**HOSPITAL NAME**

Farview Animal Clinic

**REFERRING VET**

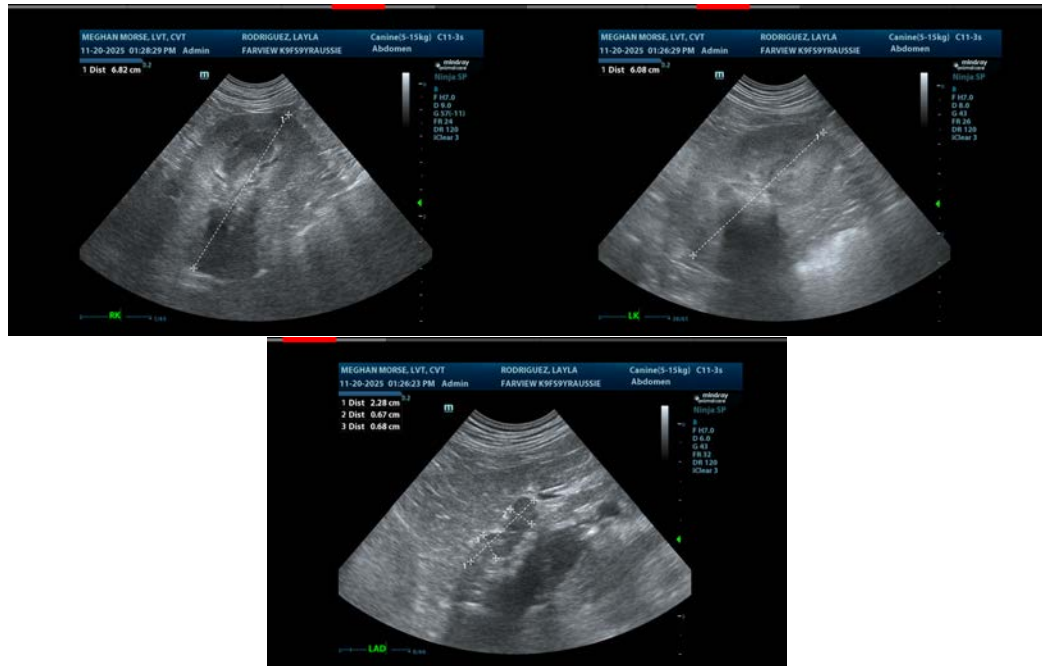
Dr. Mosaad

**INVOICE**

72009

**DATE**

11/20/25



The information and recommendations provided are based on the images presented by the referring veterinarian/sonographer. No evaluation can be communicated regarding pathology that was not visible in the image/video clips provided.

Thank you for this referral. If the clinical or image interpretation does not parallel your findings or if I can be of any further assistance please contact me.

Kathleen Sennello DVM,MS, Diplomate ACVIM (Small animal Internal Medicine)

info@sonopath.com