

PATIENT

Kali Russell

SPECIES

Canine

BREED

Aus Min Shepherd

SEX

Spayed Female

AGE

11 Years 10 Months

WEIGHT

47.9 lbs

INTERPRETED BY

Kathleen Sennello DVM,
 MS, Diplomate ACVIM
 (Small Animal Internal
 Medicine)

IMAGING PERFORMED BY

Kathleen Byrnes

HOSPITAL NAME

Stoney Creek
 Veterinary Hospital

REFERRING VET

Dr. Eldred

INVOICE

71985

DATE

11/20/25

PRESENTING CLINICAL SIGNS

P presented for ultrasound due to elevated liver enzymes, currently on Ursodiol, Liver values remain elevated.

ULTRASONOGRAPHIC EXAMINATION OF THE ABDOMEN

Urinary System

The urinary bladder is moderately distended with anechoic urine. The Bladder wall, trigone, ureteral papillae and visible urethra (to a depth of 2cm) appear normal with no evidence of wall thickening, mucosal irregularities, masses or cystic calculi.

The left kidney has a normal shape and size (6.36 cm). Overall echogenicity is slightly hyperechoic with poor corticomedullary distinction and a typical 1:3 cortex:medulla ratio. There is no evidence of focal perinephric inflammation or effusion. There is no evidence of pyelectasia, nephroliths, infarcts or hydroureter. Renal vasculature is normal.

The right kidney has a normal shape and size (6.19 cm). Overall echogenicity is slightly hyperechoic with poor corticomedullary distinction and a typical 1:3 cortex:medulla ratio. There is no evidence of focal perinephric inflammation or effusion. There is no evidence of pyelectasia, nephroliths, infarcts or hydroureter. Renal vasculature is normal.

Adrenal Glands

The left adrenal gland is normal in size measuring 0.53 cm at the cranial pole 0.60 cm at the caudal pole. It is observed in its normal position cranial to the left renal artery. It is normal in appearance (uniformly hypoechoic) and shape with no evidence of a mass effect.

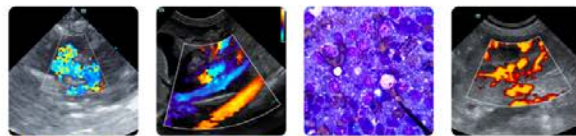
The right adrenal gland slightly irregular in appearance in that the cranial pole is enlarged and slightly irregular measuring 1.3 cm. Caudal pole measures 0.64 cm. It is observed in its normal position between the cranial aspect of the right kidney and the caudal vena cava. No evidence of vascular invasion clearly visualized.

Spleen

The spleen is normal in size and shape. The blood flow through the hilus and splenic parenchyma appears normal. There is a small, hypoechoic, cavitated nodule visualized in the tail of the spleen, which does not disrupt the splenic margins, measuring 1.04 cm x 0.76 cm.

Liver

The liver is large in size and irregular with rounded margins. The parenchyma is heterogenous in echotexture with subtle, indistinct focal mottling. The visible portions of the vasculature and biliary tract appear normal. There are numerous iso- to slightly hypoechoic mass effects and nodules throughout the liver. In the mid caudal liver, there is a poorly defined mass effect measuring 4.63 cm x 6.03 cm. There are numerous small hypoechoic nodules, and there is a larger irregular area with hypoechoic nodules visualized on the right side measuring 4.18 cm x 5.41 cm, as well as a mid caudal area of abnormal liver with a small cystic/cavitated region measuring 2.29 cm x 3.56 cm.



PATIENT

Kali Russell

The gall bladder lumen is moderately distended. The wall of the gall bladder is not thickened and has a smooth mucosal surface. Luminal contents are mild and likely incidental at this time. The cystic and common bile ducts are normal/not visible.

SPECIES

Canine

Gastrointestinal

The stomach contains minimal luminal contents. It measures at a normal thickness of <0.7cm with some variability due to the presence of rugal folds. The distinction of the gastric wall layers is adequate and there is no impression of reduced peristaltic activity. No masses or focal lesions were observed.

BREED

Aus Min Shepherd

The visualized areas of duodenum, jejunum and ileum have a relatively uniform diameter with minimal fluid distension. Wall thickness is normal. Bowel loops follow a curvilinear path with distinct wall layering maintaining the typical 1:3 muscularis:mucosa layer ratio. Duodenum wall measures 0.45 cm. Jejunum wall measures 0.31 cm. Visualized peristalsis appears appropriate. There were no focal lesions consistent with obstruction or a mass effect observed.

SEX

Spayed Female

AGE

11 Years 10 Months

Sections of colon are visualized with formed fecal material and gas shadowing distally. There is no observed focal or generalized colon wall thickening or loss of layering.

Pancreas

WEIGHT

47.9 lbs

The area of the pancreas is normal and isoechoic to surrounding mesentery. There is no evidence of nodules or cystic lesions. There is no evidence of regional mesenteric inflammation or fluid.

Free Abdomen

INTERPRETED BY

Kathleen Sennello DVM,
 MS, Diplomate ACVIM
 (Small Animal Internal
 Medicine)

Evaluation of the peritoneal cavity did not reveal any evidence of effusion, or subjective lymphadenomegaly. The Medial iliac nodes appear normal and there was no evidence of a caudal aortic thrombus at the bifurcation. The omentum is of normal uniform echogenicity.

Other

IMAGING PERFORMED BY

Kathleen Byrnes

The right auricle and pericardium were visualized and were unremarkable. No obvious pathology is visualized. If cardiac function evaluation is desired a full echocardiogram is warranted.

ULTRASONOGRAPHIC FINDINGS

HOSPITAL NAME

Stoney Creek
 Veterinary Hospital

- Small, hypoechoic, cavitated lesion in the spleen – There is a non-cavitated, hypoechoic splenic nodule visualized. Differentials include lymphoid hyperplasia, extramedullary hematopoiesis, infiltrative neoplasia, inflammation, other. Cytology or histopathology would be necessary to get a definitive diagnosis.

REFERRING VET

Dr. Eldred

- Age related changes visualized associated with both kidneys.

INVOICE

71985

- Large, rounded, irregular, heterogeneous liver with numerous irregular mass effects – Some of the small nodules have the appearance most consistent with regenerative nodules, although early neoplastic lesions cannot be ruled out. The largest mass effects have the appearance most consistent with primary hepatic mass lesions (adenoma, carcinoma, other), although other differentials are possible.

DATE

11/20/25



PATIENT

Kali Russell

SPECIES

Canine

BREED

Aus Min Shepherd

SEX

Spayed Female

AGE

11 Years 10 Months

WEIGHT

47.9 lbs

INTERPRETED BY

Kathleen Sennello DVM,
 MS, Diplomate ACVIM
 (Small Animal Internal
 Medicine)

**IMAGING
 PERFORMED BY**

Kathleen Byrnes

HOSPITAL NAME

Stoney Creek
 Veterinary Hospital

REFERRING VET

Dr. Eldred

INVOICE

71985

DATE

11/20/25

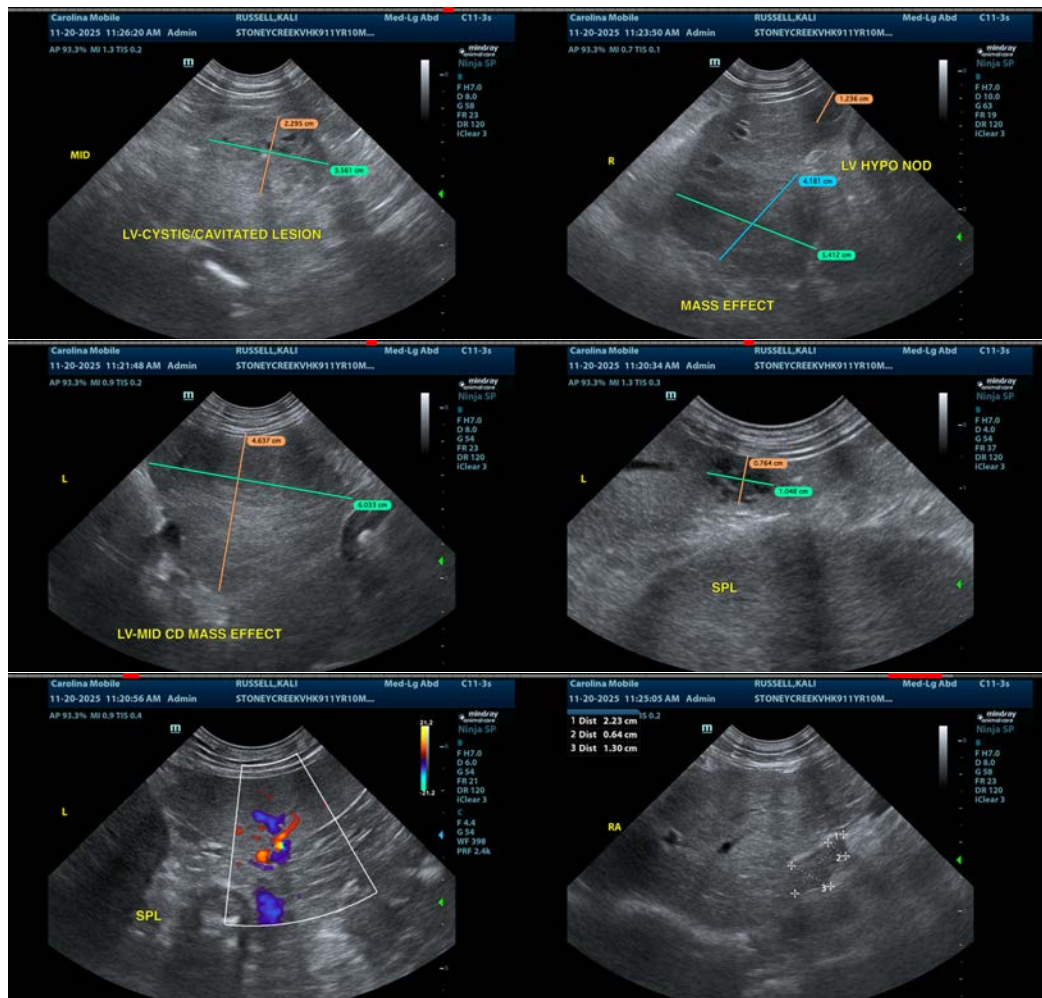
INTERPRETATION OF THE FINDINGS & FURTHER RECOMMENDATIONS

The liver is very large and irregular with numerous irregular, poorly differentiated mass lesions. These generally have the appearance most consistent with primary hepatic mass lesions (adenomas, carcinomas, other), although other differentials are possible. Additionally, there is a small cavitated lesion in the tail of the spleen. Recommend a fine needle aspirate of one of the liver mass lesions and the splenic lesion. Ideally a contrast CT scan would be performed to get a more global view of the liver to better ascertain the nature and extent of the mass lesions.

Additionally, the right adrenal appears large and slightly irregular. If a contrast CT scan is performed of the liver, the adrenal can be evaluated for any evidence of vascular invasion, etc.

If this patient has signs consistent with Cushing's you could consider adrenal function testing to further evaluate. Additionally, if hypertension is present, consider measuring catecholamine levels, looking for an early pheochromocytoma.

Recommend three view thoracic radiographs to evaluate for possible concurrent thoracic disease/involvement (disregard if this has already been done).





PATIENT

Kali Russell

SPECIES

Canine

BREED

Aus Min Shepherd

SEX

Spayed Female

AGE

11 Years 10 Months

WEIGHT

47.9 lbs

INTERPRETED BY

Kathleen Sennello DVM,
MS, Diplomate ACVIM
(Small Animal Internal
Medicine)

IMAGING PERFORMED BY

Kathleen Byrnes

HOSPITAL NAME

Stoney Creek
Veterinary Hospital

REFERRING VET

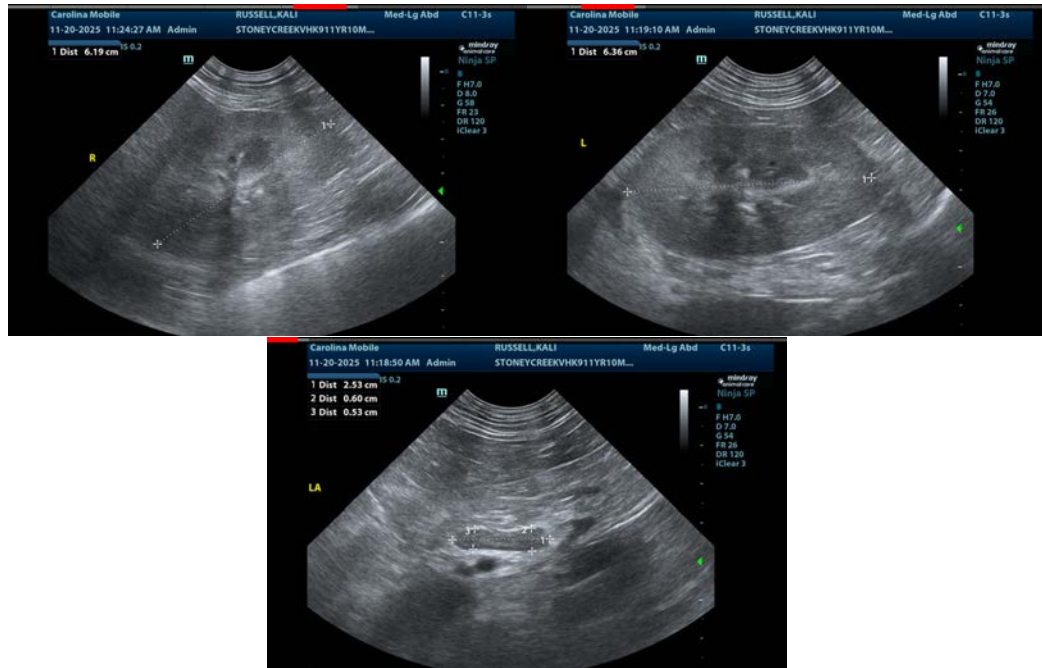
Dr. Eldred

INVOICE

71985

DATE

11/20/25



The information and recommendations provided are based on the images presented by the referring veterinarian/sonographer. No evaluation can be communicated regarding pathology that was not visible in the image/video clips provided.

Thank you for this referral. If the clinical or image interpretation does not parallel your findings or if I can be of any further assistance please contact me.

Kathleen Sennello DVM,MS, Diplomate ACVIM (Small animal Internal Medicine)

info@sonopath.com