



PATIENT

Hemi Anderson

SPECIES

Canine

BREED

Pit x

SEX

Neutered Male

AGE

8 Years 10 Months

WEIGHT

82.4 lbs

INTERPRETED BY

Kathleen Sennello DVM,
MS, Diplomate ACVIM
(Small Animal Internal
Medicine)

IMAGING PERFORMED BY

Dr. Megan Bray

HOSPITAL NAME

Taylorville Veterinary
Clinic

REFERRING VET

Dr. Megan Bray

INVOICE

72014

DATE

11/20/25

PRESENTING CLINICAL SIGNS

Initially presented for shifting leg lameness affecting multiple limbs 4Dx Negative, labs showed non-regenerative anemia that is stable. A 2 week course of Doxycycline lead to no improvement in either lameness or labwork. Showed improvement on Carprofen but was discontinued due to liver values being mildly elevated after a trial of Carprofen.

Abnormal PE/Chem/CBC/UA Results: See attached labwork results

ULTRASONOGRAPHIC EXAMINATION OF THE ABDOMEN

Urinary System

The urinary bladder is moderately distended with anechoic urine. The Bladder wall, trigone, ureteral papillae and visible urethra (to a depth of 2cm) appear normal with no evidence of wall thickening, mucosal irregularities, masses or cystic calculi.

The prostate is normal in size (0.90 cm) and shape for this neutered male dog. The parenchyma is homogenous and the external margins are smooth. The prostatic urethra appears normal with no evidence of irregularity, invasion, mass effect or calculi.

The left kidney has a normal shape and size (7.79 cm). Overall echogenicity is normal with adequate corticomedullary distinction and a typical 1:3 cortex:medulla ratio. There is no evidence of focal perinephric inflammation or effusion. There is no evidence of pyelectasia, nephroliths, infarcts or hydroureter. Renal vasculature is normal.

The right kidney has a normal shape and size (7.89 cm). Overall echogenicity is normal with adequate corticomedullary distinction and a typical 1:3 cortex:medulla ratio. There is no evidence of focal perinephric inflammation or effusion. There is no evidence of pyelectasia, nephroliths, infarcts or hydroureter. Renal vasculature is normal.

Adrenal Glands

The left adrenal gland is normal in size measuring 0.63 cm at the cranial pole and 0.68 cm at the caudal pole. It is observed in its normal position cranial to the left renal artery. It is normal in appearance (uniformly hypoechoic) and shape with no evidence of a mass effect.

The right adrenal gland is normal in size measuring 0.49 cm at the cranial pole and 0.49 cm at the caudal pole. It is observed in its normal position between the cranial aspect of the right kidney and the caudal vena cava. It is normal in appearance (uniformly hypoechoic) and shape with no evidence of a mass effect.

Spleen

The spleen is subjectively normal in size (2.21 cm), echotexture is homogenous, and the splenic capsule is smooth with no irregularities. The blood flow through the hilus and splenic parenchyma appears normal. No focal parenchymal abnormalities are visualized.

Liver

The liver is subjectively normal in size, and echogenicity with smooth peripheral margins. The parenchyma is heterogenous in echotexture with subtle, indistinct focal mottling. The visible portions of



PATIENT

Hemi Anderson

SPECIES

Canine

BREED

Pit x

SEX

Neutered Male

AGE

8 Years 10 Months

WEIGHT

82.4 lbs

INTERPRETED BY

Kathleen Sennello DVM,
MS, Diplomate ACVIM
(Small Animal Internal
Medicine)

IMAGING PERFORMED BY

Dr. Megan Bray

HOSPITAL NAME

Taylorville Veterinary
Clinic

REFERRING VET

Dr. Megan Bray

INVOICE

72014

DATE

11/20/25

the vasculature and biliary tract appear normal. No focal nodules or cystic lesions are observed. Full evaluation of the liver is difficult due to lack of ultrasound penetration in this large dog.

The gall bladder lumen is moderately distended. The wall of the gall bladder is not thickened and has a smooth mucosal surface. Luminal contents are mild and likely incidental at this time. The cystic and common bile ducts are normal/not visible.

Gastrointestinal

The stomach contains moderate shadowing ingesta. It measures at a normal thickness of <0.7cm with some variability due to the presence of rugal folds. The distinction of the gastric wall layers is adequate and there is no impression of reduced peristaltic activity. No masses or focal lesions were observed.

The visualized areas of duodenum, jejunum and ileum have a relatively uniform diameter with minimal fluid distension. Wall thickness is normal. Bowel loops follow a curvilinear path with distinct wall layering maintaining the typical 1:3 muscularis:mucosa layer ratio. The duodenum measured as normal (between 0.3-0.5cm in wall thickness) and the jejunum measured as normal (between 0.2-0.47cm.) Visualized peristalsis appears appropriate. There were no focal lesions consistent with obstruction or a mass effect observed.

Sections of colon are visualized with formed fecal material and gas shadowing distally. There is no observed focal or generalized colon wall thickening or loss of layering.

Pancreas

The area of the pancreas is normal and isoechoic to surrounding mesentery. There is no evidence of nodules or cystic lesions. There is no evidence of regional mesenteric inflammation or fluid.

Free Abdomen

Evaluation of the peritoneal cavity did not reveal any evidence of effusion, or subjective lymphadenomegaly. The Medial iliac nodes appear normal and there was no evidence of a caudal aortic thrombus at the bifurcation. The omentum is of normal uniform echogenicity.

ULTRASONOGRAPHIC FINDINGS

- Heterogeneous liver – The diffuse hepatic changes are non-specific and could be consistent with vacuolar hepatopathy, nodular hyperplasia, inflammatory/immune-mediated disease, fibrosis, extramedullary hematopoiesis, toxic hepatopathy (e.g., copper), infiltrative neoplasia (less likely) or other hepatopathy.
- Moderate shadowing ingesta visualized within the gastric lumen – Correlate with feeding history. Findings are most consistent with a non-fasted patient.

INTERPRETATION OF THE FINDINGS & FURTHER RECOMMENDATIONS

The liver appears mildly heterogeneous. The significance of this is uncertain. No focal lesions were observed, but visualization of the entirety of the liver is challenging in this large dog. If further evaluation is desired, a liver function test and a fine needle aspirate could be considered.

Consider multiple joint taps (fluid analysis, cytology and culture), looking for possible polyarthritis, ideally off anti-inflammatories and antibiotics for a few days prior to sampling.



PATIENT

Hemi Anderson

SPECIES

Canine

BREED

Pit x

SEX

Neutered Male

AGE

8 Years 10 Months

WEIGHT

82.4 lbs

INTERPRETED BY

Kathleen Sennello DVM,
MS, Diplomate ACVIM
(Small Animal Internal
Medicine)

**IMAGING
PERFORMED BY**

Dr. Megan Bray

HOSPITAL NAME

Taylorville Veterinary
Clinic

REFERRING VET

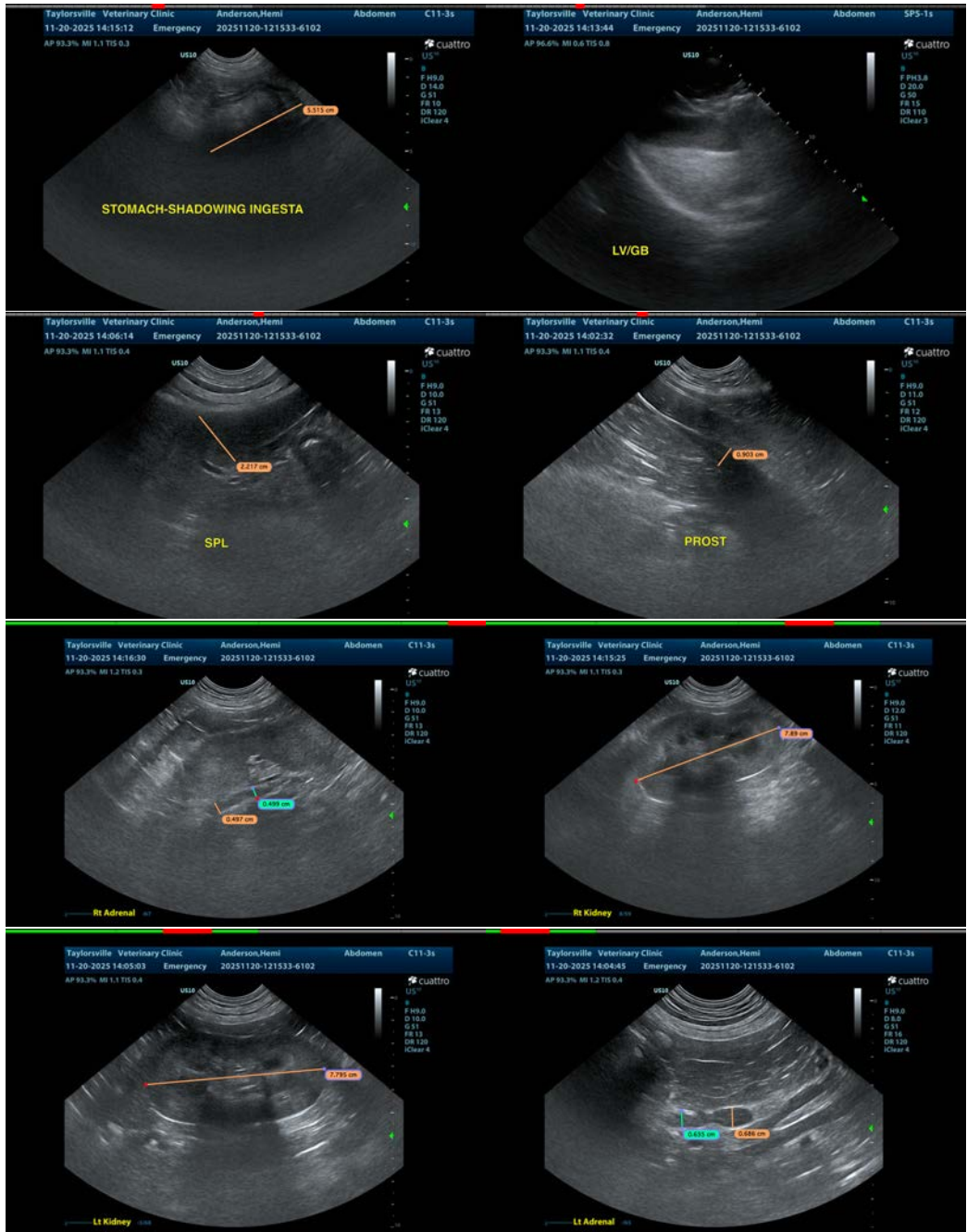
Dr. Megan Bray

INVOICE

72014

DATE

11/20/25



The information and recommendations provided are based on the images presented by the referring veterinarian/sonographer. No evaluation can be communicated regarding pathology that was not visible in the image/video clips provided.

Thank you for this referral. If the clinical or image interpretation does not parallel your findings or if I can be of any further assistance please contact me.

Kathleen Sennello DVM,MS, Diplomate ACVIM (Small animal Internal Medicine) info@sonopath.com