



DATE PRESENTING CLINICAL SIGNS

11/20/25

PATIENT

Falana O'Lone

SPECIES

Feline

BREED

Tonkinese

SEX

Spayed Female

AGE

12/29/10

WEIGHT

6.9 lbs

INTERPRETED BY

Kathleen Sennello DVM,
MS, Diplomate ACVIM
(Small Animal Internal
Medicine)

HOSPITAL NAME

Animal Emergency
Hospital

REFERRING VET

Dr. Willer

INVOICE

72012

Patient History: Seen at RDVM on 11/17 - decreased appetite bloodwork- normal BUN; mild elevation in CRE (2.4- high normal is 2.3) elevated WBC, neutro K- 3.5 BNP- normal T4- normal (2.1) treated outpatient- given cerenia seen on 11/18 for not improving and abnormal breathing- got chest xrays- per notes- NSF got SQ fluids, cerenia, elura, B12 injection presented this morning for continuing not to eat and urinated over owner history from owner - Chronic elevated kidney values (high end of normal for 7 years) - History of UTI last year (first occurrence) - History of variable urine concentration - Seen by regular veterinarian 3 times in past 2 days (twice Monday, once Tuesday) - Medications administered at previous visits: - Cerenia (no improvement noted) - B12 injection (short-lived improvement) - Elura (mirtazapine appetite stimulant) - started Tuesday - Caloric intake: - Normal baseline: 130-140 calories/day - Saturday-Sunday: Within normal range - Monday: 70 calories - Tuesday: 60 calories - Post-Elura: 35-40 calories (not considered clinically significant improvement) - Client reports visible signs of discomfort/pain, worsening from previous day - Persistent cough

Current Medications: Gabapentin, buprenorphine, ondansetron, famotidine

Labwork Results: Labwork attached. Previous US images from 2024 attached.

Date of Previous IntraPet Ultrasound: No previous.

Sedation: Not required to complete full diagnostic ultrasound.

Stat Report: Not requested.

Imaging Performed by: Rachel Brillhart, RDMS.

ULTRASONOGRAPHIC EXAMINATION OF THE ABDOMEN

Urinary System

The urinary bladder is moderately distended with anechoic urine. The Bladder wall, trigone, ureteral papillae and visible urethra (to a depth of 2cm) appear normal with no evidence of wall thickening, mucosal irregularities, masses or cystic calculi.

The left kidney has a normal shape and size (3.34 cm) with pyelectasia at 0.19 cm. Overall echogenicity is slightly hyperechoic with poor corticomedullary distinction and a typical 1:3 cortex:medulla ratio. There is no evidence of focal perinephric inflammation or effusion. There is no evidence of nephroliths, infarcts or hydroureter. Renal vasculature is normal.

The right kidney has a normal shape and size (3.39 cm) with pyelectasia at 0.35 cm. Overall echogenicity is slightly hyperechoic with poor corticomedullary distinction and a typical 1:3 cortex:medulla ratio. There is no evidence of focal perinephric inflammation or effusion. There is no evidence of nephroliths, infarcts or hydroureter. Renal vasculature is normal.

Adrenal Glands

The left adrenal gland is normal in size measuring 0.34 cm at the caudal pole. It is observed in its normal position cranial to the left renal artery. It is normal in appearance (uniformly hypoechoic) and shape with no evidence of a mass effect.

The right adrenal gland is normal in size measuring 0.51 cm at the caudal pole. It is observed in its normal position between the cranial aspect of the right kidney and the caudal vena cava. It is normal in appearance (uniformly hypoechoic) and shape with no evidence of a mass effect.

Spleen

The spleen is subjectively normal in size (0.99 cm), echotexture is homogenous, and the splenic capsule is smooth with no irregularities. The blood flow through the hilus and splenic parenchyma appears normal. No focal parenchymal abnormalities are visualized.

Liver

The liver is subjectively normal in size, and echogenicity with smooth peripheral margins. The parenchyma is homogenous echotexture. The visible portions of the vasculature and biliary tract appear normal. There is a hypoechoic nodule in the right side of the liver measuring 1.07 cm x 0.84 cm.

The gall bladder lumen is moderately distended. The wall of the gall bladder is not thickened and has a smooth mucosal surface. There is a moderate amount of non-organized echogenic debris. The cystic and common bile ducts are normal/not visible.

Gastrointestinal

The stomach contains minimal luminal contents. It measures at a normal thickness of <0.36cm with some variability due to the presence of rugal folds. The distinction of the gastric wall layers is adequate and there is no impression of reduced peristaltic activity. No masses or focal lesions were observed.

The visualized areas of duodenum, jejunum and ileum have a uniform diameter with minimal fluid distension. Wall appears subjectively, mildly increased. Bowel loops follow a typical curvilinear path with distinct wall layering. Duodenum wall measures 0.31 cm. Jejunum wall measures 0.26 cm. Visualized peristalsis appears appropriate. The duodenum is prominent and mildly corrugated, possibly consistent with mild enteritis.

The ileocecal junction was visualized and exhibited normal intact wall layering and is subjectively of normal thickness. Sections of colon are visualized with formed fecal material and gas shadowing distally. There is no observed focal or generalized colon wall thickening or loss of layering.

Pancreas

The pancreas is large, hypoechoic and mottled. There is no evidence of nodules or cystic lesions. There is no evidence of regional mesenteric inflammation or fluid.

Free Abdomen

Evaluation of the peritoneal cavity did not reveal any evidence of effusion. There is no significant lymphadenopathy. The omentum is of normal echogenicity.

ULTRASONOGRAPHIC FINDINGS

- Decreased corticomedullary distinction visualized associated with both kidneys with bilateral pyelectasia – Pyelectasia of the kidney(s) could be consistent with pyelonephritis, chronic renal disease, secondary to PU/PD or fluid therapy (if applicable), other.
- Prominent, hypoechoic, mottled pancreas – Findings are most consistent with chronic pancreatic remodeling +/- chronic pancreatitis.
- Hypoechoic nodule in the liver – This could represent a benign or early neoplastic lesion.
- Moderate gallbladder debris – The significance of the aggregated gallbladder debris is unclear. This could represent an early mucocele, cholestasis, or may be secondary to fasting. Incidental gall bladder debris is less common in cats.

- Mildly thickened small intestine with mild duodenal corrugation – Findings could be consistent with mild enteritis.

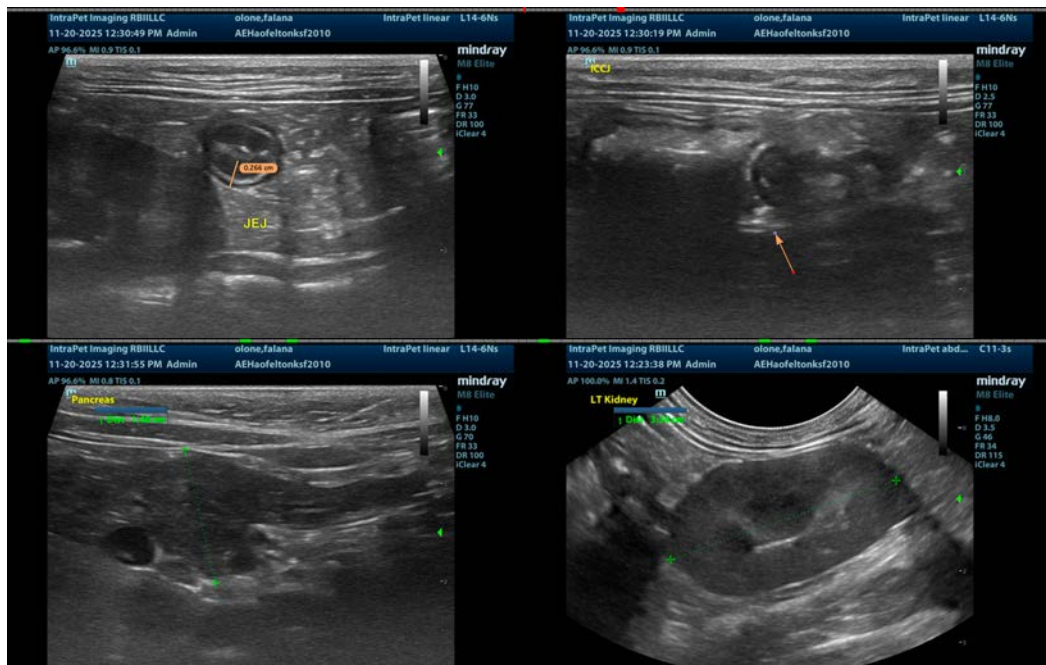
INTERPRETATION OF THE FINDINGS & FURTHER RECOMMENDATIONS

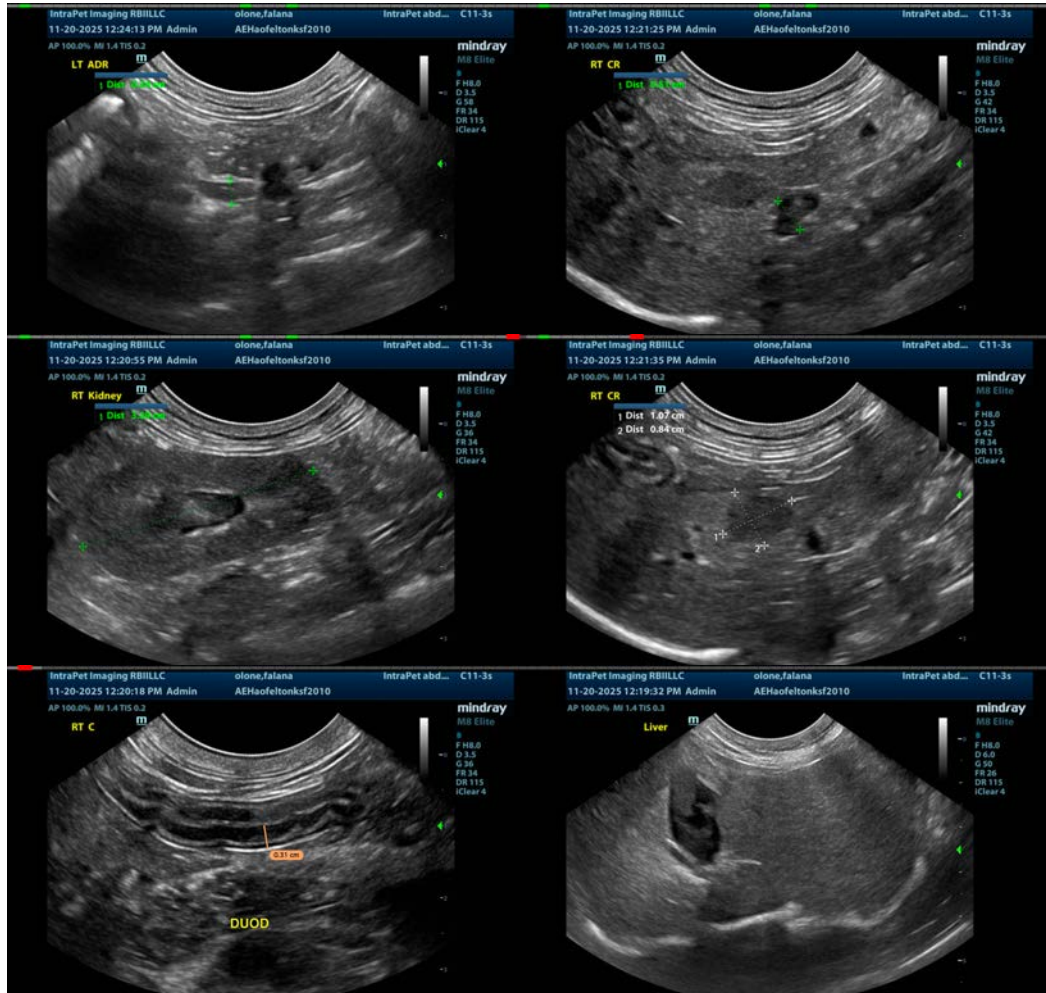
Both kidneys have decreased corticomedullary distinction and mild pyelectasia. Recommend a urinalysis, culture and a blood pressure evaluation (+/- urine protein to creatinine ratio) as a baseline.

The pancreas is large, hypoechoic and mottled, with minimal appreciable surrounding inflammation. Findings are most consistent with pancreatic remodeling. Correlate with a PLI level, as chronic active pancreatitis may be present. A neoplastic process is thought less likely.

There is a small hypoechoic nodule in the liver. If a safe window for sampling is available, consider a fine needle aspirate. Otherwise, recommend continued monitoring.

The small intestine appears subjectively mildly thickened and the duodenum is slightly corrugated. These changes are very mild and could be normal for this individual. Ultimately, mild enteritis could be a factor. If there is concern for underlying gastrointestinal disease, consider a GI panel to Texas A&M for a qualitative PLI, TLI, cobalamin and folate, looking for additional evidence of an enteropathy, which may require further evaluation.





The information and recommendations provided are based on the images presented by the referring veterinarian/sonographer. No evaluation can be communicated regarding pathology that was not visible in the image/video clips provided.

Thank you for this referral. If the clinical or image interpretation does not parallel your findings or if I can be of any further assistance please contact me.

Kathleen Sennello DVM,MS, Diplomate ACVIM (Small animal Internal Medicine)
 info@sonopath.com