

**DATE PRESENTING CLINICAL SIGNS**

11/2/22 Suspect acute hemoabdomen one week ago - 10/20/22 HCT 24% WBC 33K, elev. alt & alkphos; recovered within a week on prednisone 10mg tapering dose - 10/27/22 HCT 39%. Kojak is very aggressive, need full sedation to examine, etc.

**PATIENT**

Kojak Roby Current Medications: 10mg Prednisone tapered dose.  
Date of Previous IntraPet Ultrasound: No previous.

**SPECIES**

Sedation: Ace & DKT IM.  
Stat Report: Not requested.

Canine

**ULTRASONOGRAPHIC EXAMINATION OF THE ABDOMEN****BREED****Urinary System**

Pit Bull

The urinary bladder is moderately distended with anechoic urine. The Bladder wall, trigone, ureteral papillae and visible urethra (to a depth of 2cm) appear normal with no evidence of wall thickening, mucosal irregularities, masses or cystic calculi.

**SEX**

Neutered Male

The prostate is normal in size (1.16 cm) and shape for this neutered male dog. The parenchyma is homogenous and the external margins are smooth. The prostatic urethra appears normal with no evidence of irregularity, invasion, mass effect or calculi.

**AGE**

4/15/12

The left kidney has a normal shape and size (7.34 cm). Overall echogenicity is normal with adequate corticomedullary distinction and a typical 1:3 cortex:medulla ratio. There is no evidence of focal perinephric inflammation or effusion. There is no evidence of pyelectasia, nephroliths, infarcts or hydroureter. Renal vasculature is normal.

**WEIGHT**

67 Pounds

The right kidney has a normal shape and size (7.19 cm). Overall echogenicity is normal with adequate corticomedullary distinction and a typical 1:3 cortex:medulla ratio. There is no evidence of focal perinephric inflammation or effusion. There is no evidence of pyelectasia, nephroliths, infarcts or hydroureter. Renal vasculature is normal.

**INTERPRETED BY**

Kathleen Sennello DVM,  
MS, Diplomate ACVIM  
(Small Animal Internal  
Medicine)

**Adrenal Glands**

The left adrenal gland is normal in size measuring 0.57 cm at the caudal pole. It is observed in its normal position cranial to the left renal artery. It is normal in appearance (uniformly hypoechoic) and shape with no evidence of a mass effect.

**IMAGING PERFORMED BY**

Stephanie Warga  
RDMS, RVT

The right adrenal gland is normal in size measuring 0.63 cm at the caudal pole. It is observed in its normal position between the cranial aspect of the right kidney and the caudal vena cava. It is normal in appearance (uniformly hypoechoic) and shape with no evidence of a mass effect.

**HOSPITAL NAME**

Essex Middle River VC

**Spleen**

The spleen is subjectively normal in size, echotexture is homogenous, and the splenic capsule is smooth with no irregularities. The blood flow through the hilus and splenic parenchyma appears normal. No focal parenchymal abnormalities are visualized.

**REFERRING VET**

Dr. Zulty

**Liver**

The liver is large in size, and normal in echogenicity with smooth peripheral margins. The parenchyma is mildly heterogenous in echotexture with subtle, indistinct focal mottling. The visible portions of the vasculature and biliary tract appear normal. No focal nodules or cystic lesions are observed.

**INVOICE**

42483

The gall bladder lumen is moderately distended. The wall of the gall bladder is not thickened and has a smooth mucosal surface. There is a moderate amount of non-organized echogenic debris. The cystic and common bile ducts are normal/not visible.

### ***Gastrointestinal***

The stomach contains minimal luminal contents. It measures at a normal thickness of <0.7cm with some variability due to the presence of rugal folds. The distinction of the gastric wall layers is adequate and there is no impression of reduced peristaltic activity. No masses or focal lesions were observed.

The visualized areas of duodenum, jejunum and ileum have a relatively uniform diameter with minimal fluid distension. Wall thickness is normal. Bowel loops follow a curvilinear path with distinct wall layering maintaining the typical 1:3 muscularis:mucosa layer ratio. Duodenum wall measures 0.64 cm. Jejunum wall measures 0.47 cm. Visualized peristalsis appears appropriate. There were no focal lesions consistent with obstruction or a mass effect observed.

The ileocecal junction was visualized and exhibited normal intact wall layering and is subjectively of normal thickness. Sections of colon are visualized with formed fecal material and gas shadowing distally. There is no observed focal or generalized colon wall thickening or loss of layering.

### ***Pancreas***

The pancreas is prominent and mottled compared to the surrounding isoechoic mesentery. There is no evidence of nodules or cystic lesions. There is no evidence of regional mesenteric inflammation or fluid.

### ***Free Abdomen***

Evaluation of the peritoneal cavity did not reveal any evidence of effusion, or subjective lymphadenomegaly. The Medial iliac nodes appear normal and there was no evidence of a caudal aortic thrombus at the bifurcation. The omentum is of normal uniform echogenicity.

### ***Other***

A brief view of the heart was submitted. No significant pericardial effusion was seen.

## **ULTRASONOGRAPHIC FINDINGS**

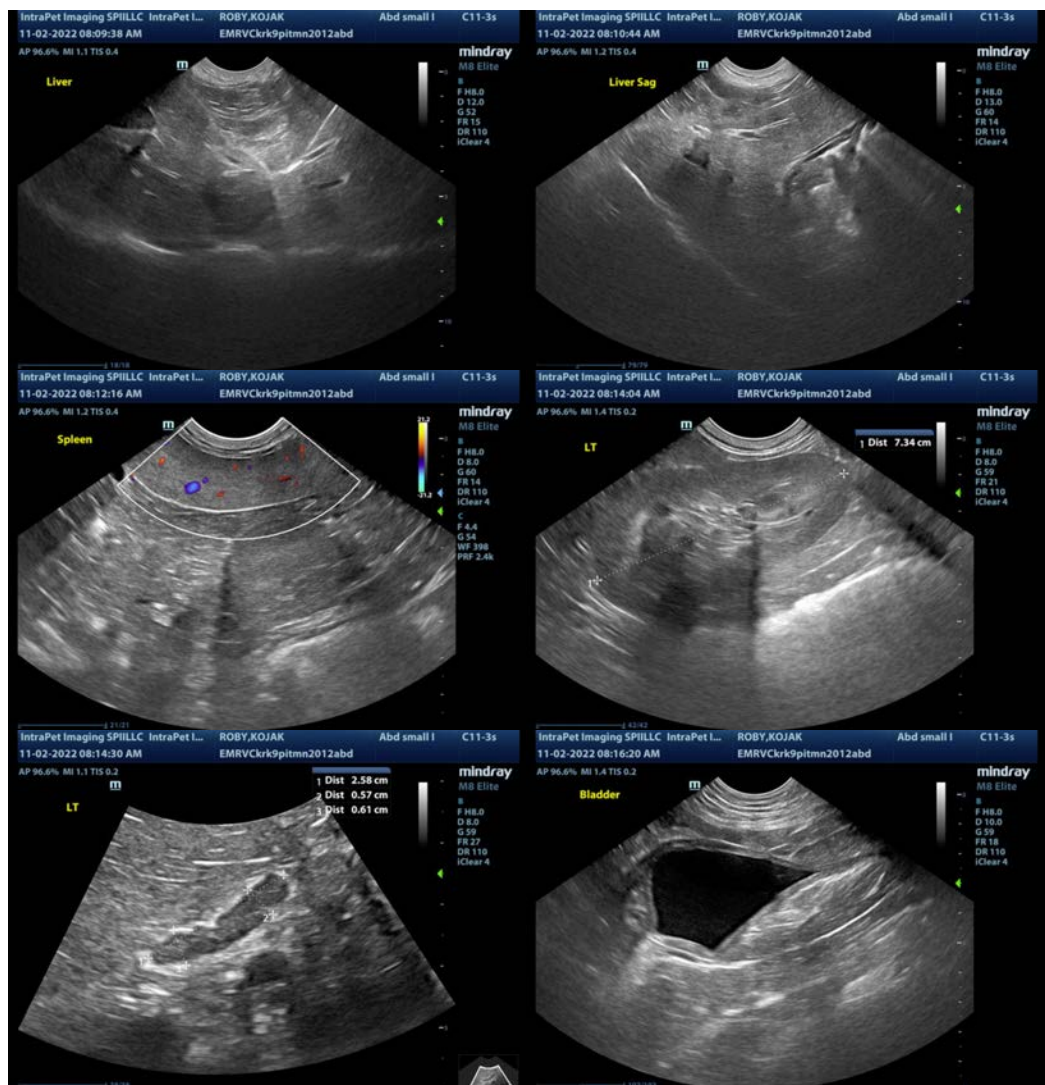
- Prominent, mottled pancreas – The pancreatic changes are most consistent with age-related parenchymal remodeling, potentially secondary to a prior inflammatory episode, early fibrosis or chronic pancreatitis.
- Large, slightly irregular, mildly heterogeneous liver – The diffuse hepatic changes are non-specific and could be consistent with vacuolar hepatopathy, nodular hyperplasia, inflammatory/immune-mediated disease, fibrosis, extramedullary hematopoiesis, toxic hepatopathy (e.g., copper), infiltrative neoplasia (less likely) or other hepatopathy.
- Moderate gallbladder debris – The significance of the aggregated gallbladder debris is unclear. This could represent an early mucocele, cholestasis, or may be secondary to fasting but seems unlikely to be causing a current issue. Recommend continued monitoring.

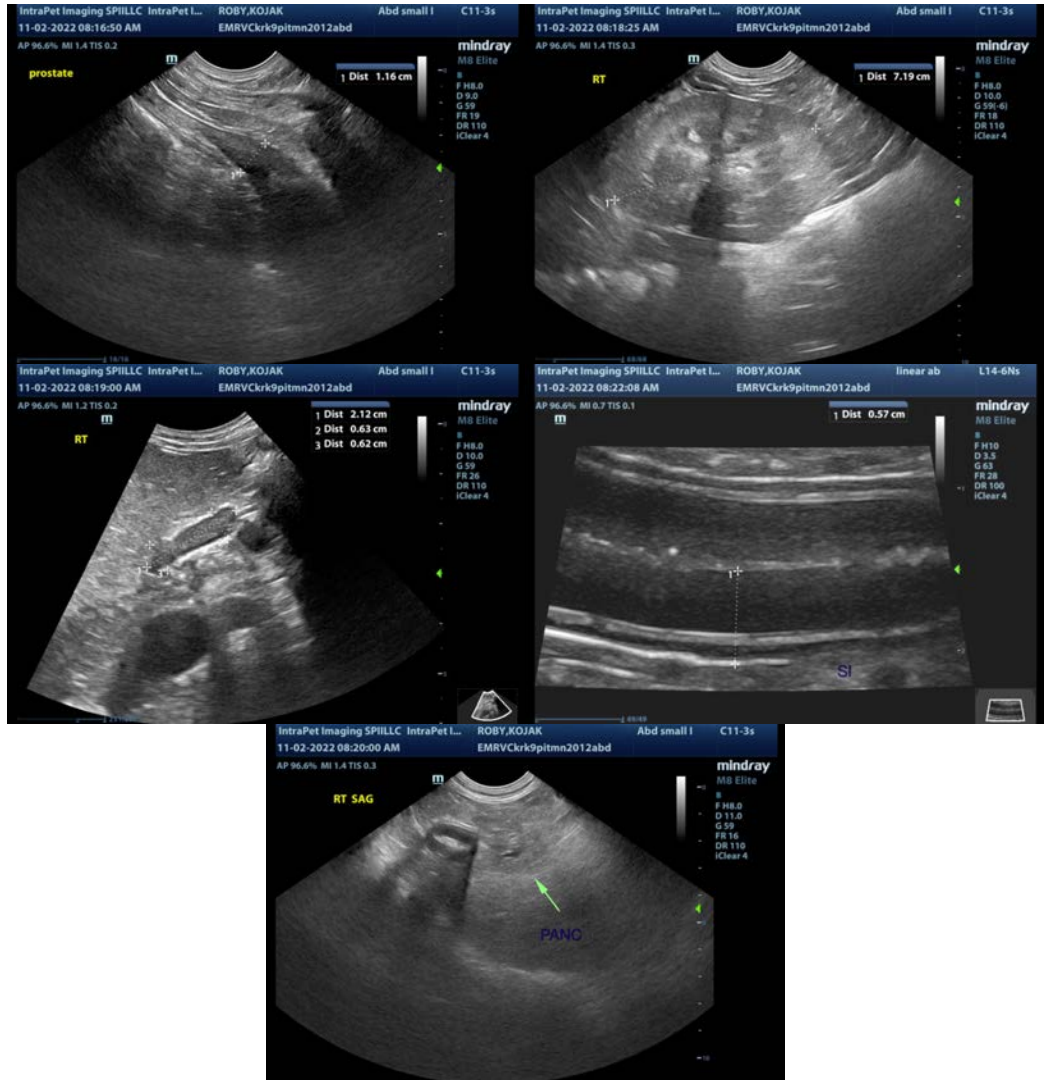
## **INTERPRETATION OF THE FINDINGS & FURTHER RECOMMENDATIONS**

No large cavitated masses are visualized and there is no evidence of free fluid in the abdomen. This does not definitively rule out the possibility of a ruptured/collapsed nodule and resorbed free fluid, but a large lesion seems unlikely. Consider the possibility of hemolysis, in particular babesia in a pit bull, and/or the possibility of a GI bleed, autoimmune disease, etc.

No focal lesions are visualized to explain the reported elevation in liver enzymes. The liver appears somewhat large and irregular and very mildly heterogeneous. The significance of this is unclear. If liver enzyme elevations persist after cessation of the Prednisone, then consider:

- A liver function test (pre- and post-prandial bile acids).
- Testing for Leptospirosis.
- Consider a fine needle aspirate of the liver if coagulation parameters permit.
- Recommend three view thoracic radiographs to evaluate for possible concurrent thoracic disease/involvement.





The information and recommendations provided are based on the images presented by the referring veterinarian/sonographer. No evaluation can be communicated regarding pathology that was not visible in the image/video clips provided.

Thank you for this referral. If the clinical or image interpretation does not parallel your findings or if I can be of any further assistance please contact me.

Kathleen Sennello DVM,MS, Diplomate ACVIM (Small animal Internal Medicine)  
 kathleen.sennello@sonopath.com