

**DATE PRESENTING CLINICAL SIGNS**

11/2/22

O states patient has/is being treated monthly for sudden episodes of lethargy, hyperthermia, inappetance, rDVM is treating with 100mg sid doxy and that resolves the issue. As soon as going off episodes come back.

PATIENT

Bailey Glorioso

Current Medications: Doxycycline 100mg SID

Lab Results: See attached.

Date of Previous IntraPet Ultrasound: No previous.

Sedation: Not required to complete full diagnostic ultrasound.

Stat Report: Offered and declined.

SPECIES

Canine

ULTRASONOGRAPHIC EXAMINATION OF THE ABDOMEN**BREED**

Puggle

Urinary System

The urinary bladder is moderately distended with mild primarily suspended echogenic debris present. The Bladder wall, trigone, ureteral papillae and visible urethra (to a depth of 2cm) appear normal with no evidence of wall thickening, mucosal irregularities, masses or calculi. Echogenic debris of this type can be associated with small crystals, cellular debris and proteinaceous debris.

SEX

Spayed Female

The left kidney has a normal shape and size (5.53 cm). Overall echogenicity is normal with adequate corticomedullary distinction and a typical 1:3 cortex:medulla ratio. There is no evidence of focal perinephric inflammation or effusion. There is no evidence of pyelectasia, nephroliths, infarcts or hydroureter. Renal vasculature is normal.

AGE

1/9/21

WEIGHT

26.6 Pounds

The right kidney has a normal shape and size (4.89 cm). Overall echogenicity is normal with adequate corticomedullary distinction and a typical 1:3 cortex:medulla ratio. There is no evidence of focal perinephric inflammation or effusion. There is no evidence of pyelectasia, nephroliths, infarcts or hydroureter. Renal vasculature is normal.

INTERPRETED BY

Kathleen Sennello DVM,
MS, Diplomate ACVIM
(Small Animal Internal
Medicine)

Adrenal Glands

The left adrenal gland is normal in size measuring 0.48 cm at the caudal pole. It is observed in its normal position cranial to the left renal artery. It is normal in appearance (uniformly hypoechoic) and shape with no evidence of a mass effect.

IMAGING PERFORMED BY

Stephanie Warga
RDMS, RVT

The right adrenal gland is normal in size measuring 0.36 cm at the caudal pole. It is observed in its normal position between the cranial aspect of the right kidney and the caudal vena cava. It is normal in appearance (uniformly hypoechoic) and shape with no evidence of a mass effect.

Spleen

The spleen is subjectively normal in size, echotexture is homogenous, and the splenic capsule is smooth with no irregularities. The blood flow through the hilus and splenic parenchyma appears normal. No focal parenchymal abnormalities are visualized.

HOSPITAL NAME

Northwind AH

Liver

The liver is subjectively normal in size, and echogenicity with smooth peripheral margins. The parenchyma is homogenous echotexture. The visible portions of the vasculature and biliary tract appear normal. No focal nodules or cystic lesions are observed.

REFERRING VET

Dr. Joes

INVOICE

42493

The gallbladder lumen is moderately distended. The wall of the gall bladder is not thickened and has a smooth mucosal surface. Luminal contents are mild and primarily anechoic. The cystic and common bile ducts are normal/not visible.

Gastrointestinal

The stomach contains minimal luminal contents. It measures at a normal thickness of <0.7cm with some variability due to the presence of rugal folds. The distinction of the gastric wall layers is adequate and there is no impression of reduced peristaltic activity. No masses or focal lesions were observed.

The visualized areas of duodenum, jejunum and ileum have a relatively uniform diameter with minimal fluid distension. Wall thickness is normal. Bowel loops follow a curvilinear path with distinct wall layering maintaining the typical 1:3 muscularis:mucosa layer ratio. The duodenum measured as normal (between 0.3-0.5cm in wall thickness) and the jejunum measured as normal (between 0.2-0.47cm.) Visualized peristalsis appears appropriate. There is a focal area of hypoechoic tissue visualized in the caudal abdomen, ventral to the urinary bladder. This tissue is surrounded by hyperechoic mesentery and fluid and is intimately associated with small bowel, where there is some corrugation, and some focal loops of bowel that appear severely thickened with diminished layering. In these regions, the small intestine measures approximately 0.58 cm in thickness.

The ileocecal junction was visualized and exhibited normal intact wall layering and is subjectively of normal thickness. Sections of colon are visualized with formed fecal material and gas shadowing distally. There is no observed focal or generalized colon wall thickening or loss of layering.

Pancreas

The pancreas is large and hypoechoic to surrounding mesentery. There is no evidence of nodules or cystic lesions. There is evidence of regional mesenteric inflammation. Consistent with mild pancreatitis.

Free Abdomen

There is a small to moderate amount of free fluid. A moderate mesenteric lymphadenopathy is present with diffusely enlarged lymph nodes at the trifurcation. Two measure 0.45 cm and 0.93 cm in width. A splenic lymph node is visualized measuring 0.96 cm. The omentum is significantly increased in echogenicity in the caudal abdomen around the abnormal tissue.

PRIMARY FINDINGS

- Abnormal area of inflamed tissue in the caudal abdomen associated with thickened irregular bowel - concerning for infiltrative disease of the bowel.
- Hypoechoic, prominent pancreas with surrounding inflammation – The pancreatic changes are most consistent with mild pancreatitis/pancreatic inflammation. Recommend fPLI testing and continued monitoring for improvement or possible development of a pancreatic abscess. Consider fine needle aspirate if not improving.
- Small to moderate volume free abdominal fluid – Recommend sampling for fluid analysis, cytology, +/- aerobic and anaerobic culture.
- Moderate lymphadenopathy – The moderate mesenteric lymphadenopathy could be concerning for a neoplastic process, although you can see significant lymphadenopathy in some cases of autoimmune/inflammatory disease, infectious disease (tick born disease - such as bartonella, fungal infections, FIP (cats)) etc. A fine needle aspirate with cytology is recommended for further evaluation.

SECONDARY FINDINGS

- Mildly echogenic urine – The echogenic debris in the bladder lumen could be consistent with cells, crystals, and/or mucus.

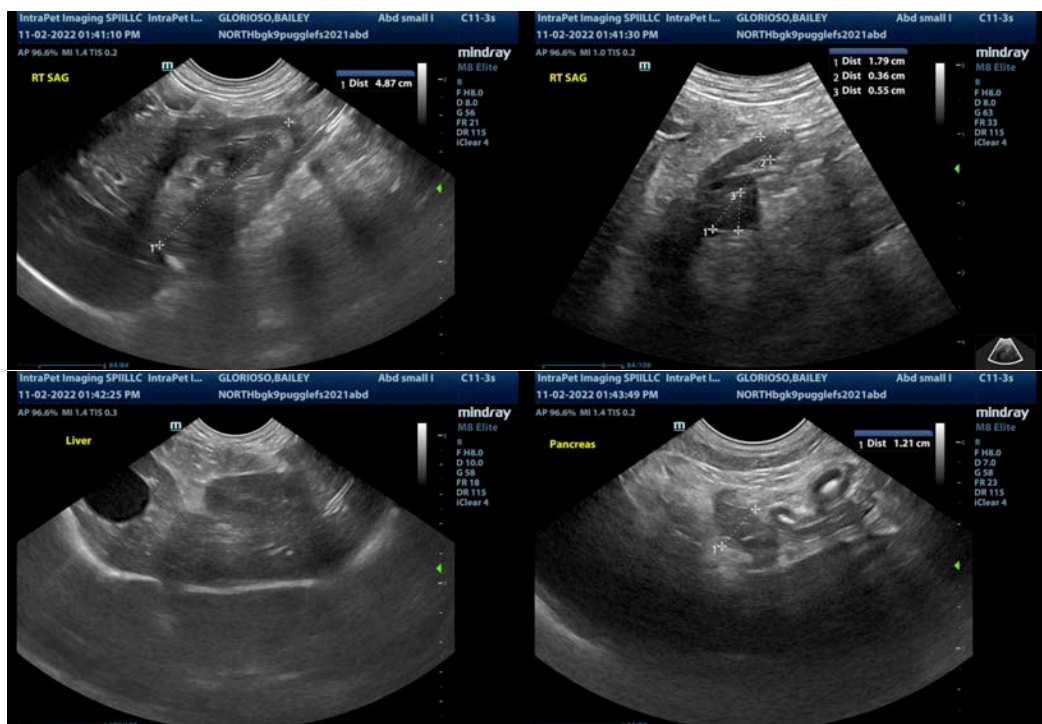
INTERPRETATION OF THE FINDINGS & FURTHER RECOMMENDATIONS

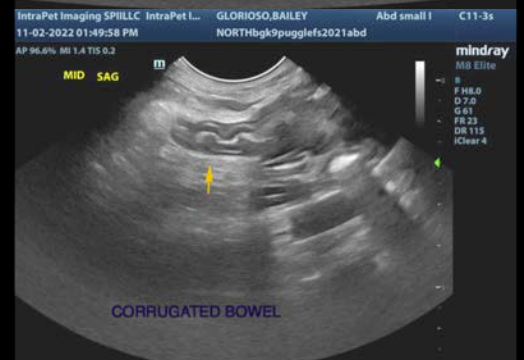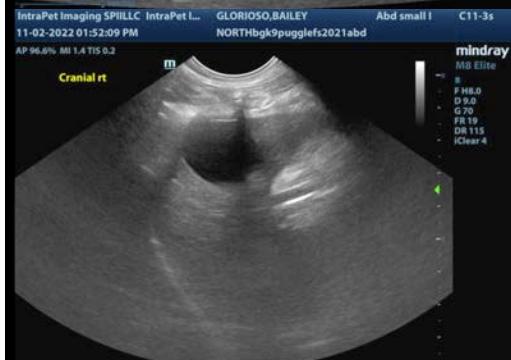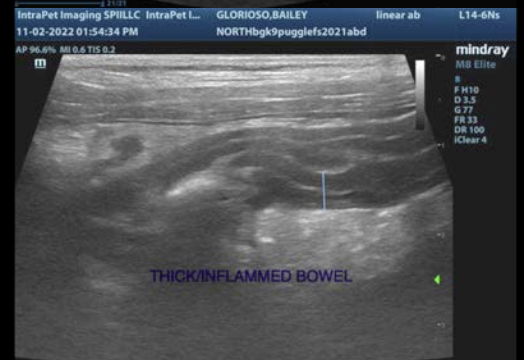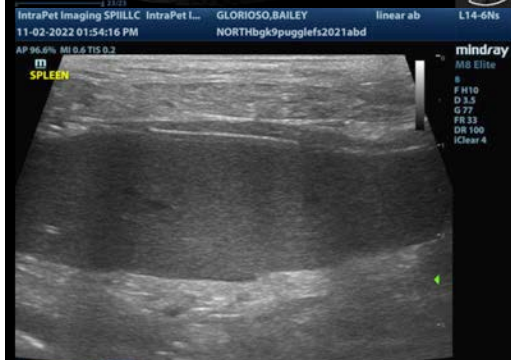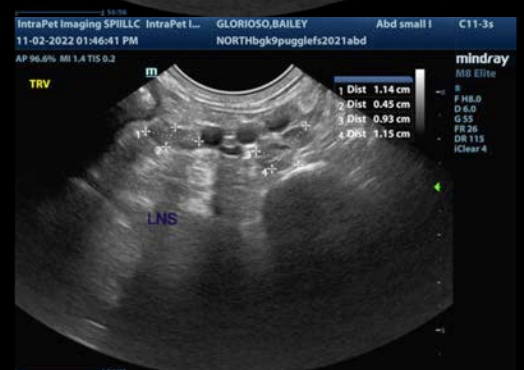
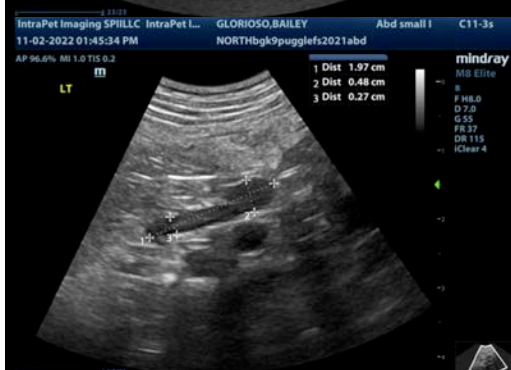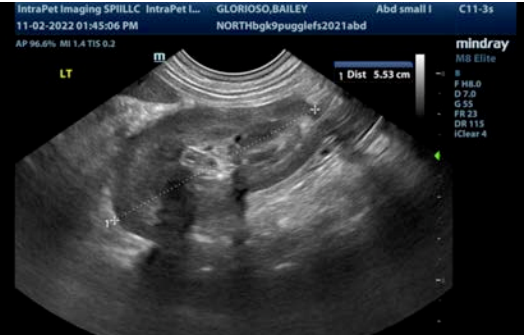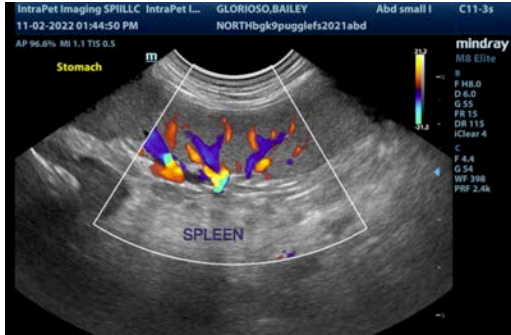There is a focal area of abnormal, hypoechoic, irregular tissue in the caudal abdomen, ventral to the urinary bladder. This area is surrounded by hyperechoic mesentery and a small amount of fluid. Additionally, it appears associated with several loops of bowel that are thickened, somewhat irregular, and inflamed. This lesion could represent an extension of the abnormal bowel due to infiltrative disease of the bowel (lymphoma, etc.), or less likely could represent a focal area of inflammation with adhered/abnormal bowel in reaction to the focal inflammation.

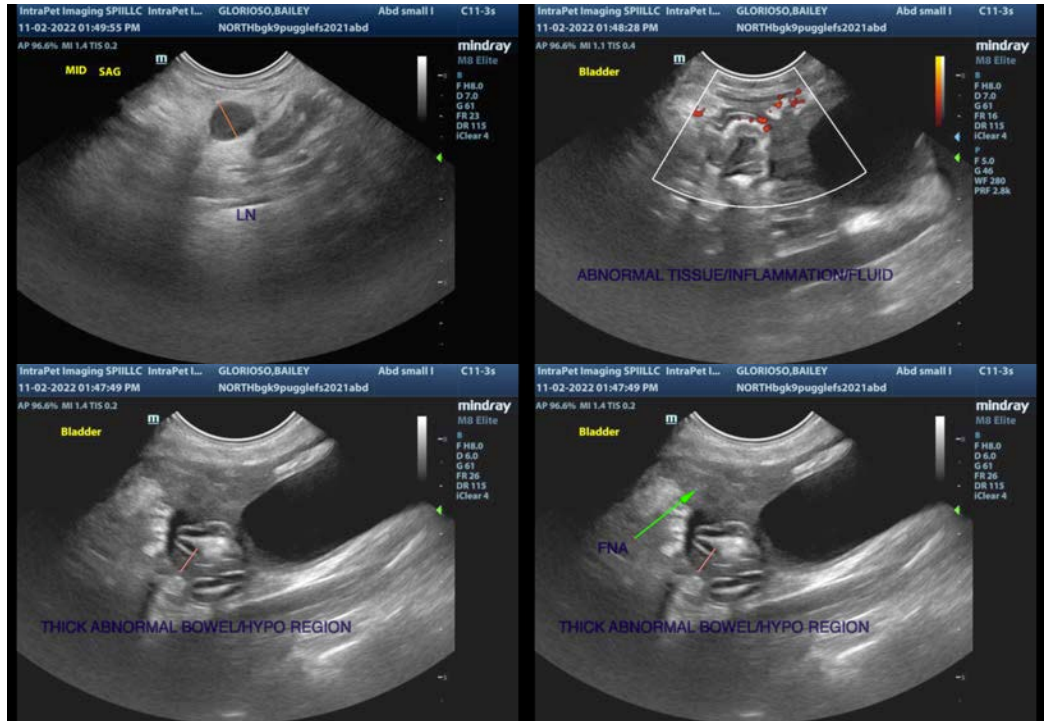
First, I would recommend a fine needle aspirate of the region, looking for possible neoplastic cells, evidence of an abscess, etc. (also consider fine needle aspirate of a mesenteric lymph node). If neoplasia is diagnosed, recommend consultation with a veterinary oncologist. If this appears inflammatory or infectious, consider referral to a veterinary surgeon for further evaluation, likely surgery with aerobic and anaerobic cultures, histopathology, and the possibility of bowel resection(?). Ideally, cultures should be done off of antibiotics for at least 5-7 days.

The pancreas appears somewhat prominent and inflamed. This could be secondary to the abdominal inflammation or could be a primary issue, but is not my primary concern.

Recommend three view thoracic radiographs to evaluate for possible concurrent thoracic disease/involvement.







The information and recommendations provided are based on the images presented by the referring veterinarian/sonographer. No evaluation can be communicated regarding pathology that was not visible in the image/video clips provided.

Thank you for this referral. If the clinical or image interpretation does not parallel your findings or if I can be of any further assistance please contact me.

Kathleen Sennello DVM,MS, Diplomate ACVIM (Small animal Internal Medicine)
kathleen.sennello@sonopath.com