



PATIENT

Burt Jennings

SPECIES

Canine

BREED

Dachshund

SEX

Neutered male

AGE

12 years

WEIGHT

16.6 lbs

INTERPRETED BY

Kathleen Sennello
DVM, MS, Diplomate
ACVIM (Small Animal
Internal Medicine)

IMAGING PERFORMED BY

Susanne Bush

HOSPITAL NAME

Great Miami VC

REFERRING VET

Dr. Bush

INVOICE

92806

DATE

11/2/21

PRESENTING CLINICAL SIGNS

History: Burt presented for rapid weight gain (4 pound gain in 3 months), mucous in stool (only the noon time bowel movement, other movements normal). He is acting hungry all the time and has increased thirst.

U/A - urine quiet, SG 1.012 CBC - mild reticulocytosis, otherwise WNL Chem - ALT 413 (18-121), AST 60 (16-55), ALP 296 (5-160), GGT 21 (0-13) . All but ALP (197) were normal in July on routine blood work.

ULTRASONOGRAPHIC EXAMINATION OF THE ABDOMEN

Urinary System

The urinary bladder is moderately distended with anechoic urine. The Bladder wall, trigone, ureteral papillae and visible urethra (to a depth of 2cm) appear normal with no evidence of wall thickening, mucosal irregularities, masses or cystic calculi.

The visualized areas of prostate and surrounding tissue appear normal. Unfortunately, the prostate is not fully visualized likely due to its intrapelvic location. Correlate with rectal exam findings.

The left kidney has a normal shape and size (4.1 cm). Overall echogenicity is normal with adequate corticomedullary distinction and a typical 1:3 cortex:medulla ratio. There is no evidence of perinephric inflammation or effusion. Small, non-obstructive nephroliths were noted. There is no evidence of pyelectasia, infarcts or hydroureter. Renal vasculature is normal.

The right kidney has a normal shape and size (4.8 cm). Overall echogenicity is normal with adequate corticomedullary distinction and a typical 1:3 cortex:medulla ratio. There is no evidence of perinephric inflammation or effusion. Small, non-obstructive nephroliths were noted. There is no evidence of pyelectasia, infarcts or hydroureter. Renal vasculature is normal.

Adrenal Glands

The left adrenal gland is normal in size measuring 0.51 cm at the caudal pole It is observed in its normal position cranial to the left renal artery. It is normal in appearance (uniformly hypoechoic) and shape with no evidence of a mass effect.

The region of the right adrenal (between right cranial kidney and vena cava) is unremarkable, but the adrenal is not distinctly visualized. No evidence of a mass effect.

Spleen

The spleen is subjectively normal in size, echotexture is homogenous, and the splenic capsule is smooth with no irregularities. The blood flow through the hilus and splenic parenchyma appears normal. No focal parenchymal abnormalities are visualized.



PATIENT *Liver*

Burt Jennings
The liver is subjectively normal in size, and echogenicity with smooth peripheral margins. The parenchyma is heterogenous in echotexture with subtle, indistinct focal mottling. The visible portions of the vasculature and biliary tract appear normal. There is an ill-defined, small, hyperechoic nodule visualized at 0.63 cm. The gallbladder revealed a large amount of sludge. The wall measured 0.35 cm.

SPECIES

Canine

BREED

Dachshund

SEX

Neutered male

AGE

12 years

WEIGHT

16.6 lbs

INTERPRETED BY

Kathleen Sennello
DVM, MS, Diplomate
ACVIM (Small Animal
Internal Medicine)

IMAGING PERFORMED BY

Susanne Bush

HOSPITAL NAME

Great Miami VC

REFERRING VET

Dr. Bush

INVOICE

92806

DATE

11/2/21

Gastrointestinal

The stomach contains minimal luminal contents. It measures at a normal thickness of <0.7cm with some variability due to the presence of rugal folds. The distinction of the gastric wall layers is adequate and there is no impression of reduced peristaltic activity. No masses or focal lesions were observed.

The visualized areas of duodenum, jejunum and ileum have a relatively uniform diameter with minimal fluid distension. Wall thickness is normal. Bowel loops follow a curvilinear path with distinct wall layering maintaining the typical 1:3 muscularis:mucosa layer ratio. The duodenum measured as normal and the jejunum measured as normal (0.29 cm). Visualized peristalsis appears appropriate. There were no focal lesions consistent with obstruction or a mass effect observed.

The ileocecal junction was visualized and exhibited normal intact wall layering and is subjectively of normal thickness. Sections of colon are visualized with formed fecal material and gas shadowing distally. There is no observed focal or generalized colon wall thickening or loss of layering.

Pancreas

The pancreas is normal and isoechoic to surrounding mesentery. There is no evidence of nodules or cystic lesions. There is no evidence of regional mesenteric inflammation or fluid.

Free Abdomen

Evaluation of the peritoneal cavity did not reveal any evidence of effusion, or subjective lymphadenomegaly. The Medial iliac nodes appear normal and there was no evidence of a caudal aortic thrombus at the bifurcation. The omentum is of normal uniform echogenicity.

ULTRASONOGRAPHIC FINDINGS

PRIMARY FINDINGS:

Large, heterogenous liver with ill-defined, hyperechoic nodule. The diffuse hepatic changes are non-specific and could be consistent with vacuolar hepatopathy, nodular hyperplasia, inflammatory/immune-mediated disease, fibrosis, extramedullary hematopoiesis, toxic hepatopathy (e.g., copper), infiltrative neoplasia (less likely) or other hepatopathy.

Large gallbladder sludge with mild gallbladder wall thickening. The findings are consistent with gallbladder disease, but the contents are not organized into a mucocele at this time.



PATIENT

Burt Jennings

SPECIES

Canine

BREED

Dachshund

SEX

Neutered male

AGE

12 years

WEIGHT

16.6 lbs

INTERPRETED BY

Kathleen Sennello
DVM, MS, Diplomate
ACVIM (Small Animal
Internal Medicine)

IMAGING PERFORMED BY

Susanne Bush

HOSPITAL NAME

Great Miami VC

REFERRING VET

Dr. Bush

INVOICE

92806

DATE

11/2/21

SECONDARY FINDINGS:

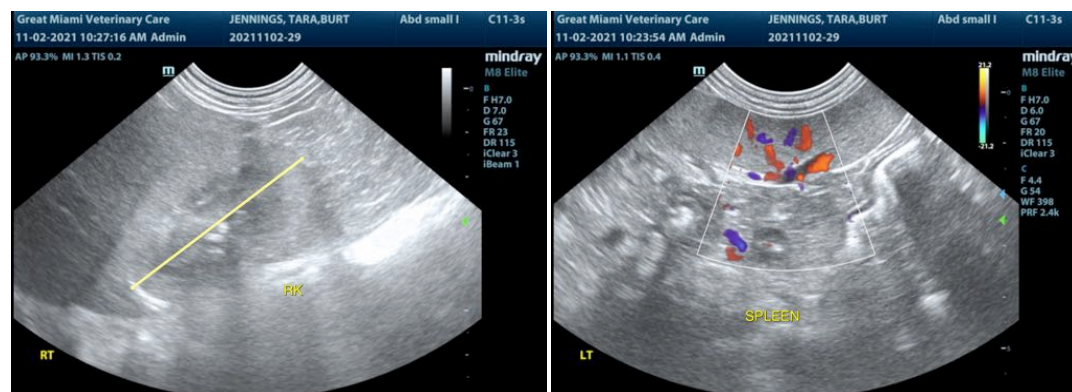
Small, non-obstructive nephroliths in both kidneys. The hyperechoic mineralized foci observed at the corticomedullary junction of the left/right kidney are consistent with small, non-obstructive nephroliths.

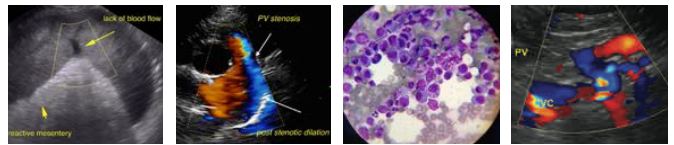
INTERPRETATION OF THE FINDINGS & FURTHER RECOMMENDATIONS

The liver appears large and heterogenous. There is an ill-defined, hyperechoic nodule visualized, but I suspect that this is less likely a significant lesion. I recommend to continue monitoring. Additionally the gallbladder has a large amount of sludge and some thickening of the gallbladder wall. There is no evidence of inflammation surrounding the gallbladder and no evidence of a mucocele. I suspect that this gallbladder is diseased and I recommend starting Ursodiol and a course of antibiotics with continued monitoring, but immediate surgical removal does not appear necessary. Ultrasound findings could be consistent with early Cushing's disease, but the left adrenal gland appears relatively normal and there is no evidence of an overtly enlarged right adrenal gland (I suspect brief visualization of the right adrenal gland, but without color flow I was not confident enough to record measurement).

Consider:

- Liver function test to confirm that the significant ALT elevation is not more concerning.
- Consider Leptospirosis testing.
- If the patient is not feeling well then consider a FNA of the liver to rule out round cell neoplasia.
- I recommend starting Ursodiol and Denamarin along with a course of antibiotics for possible bacterial cholangitis.
- I recommend to continue monitoring of liver enzymes and the appearance of the gallbladder with ultrasound. If the gallbladder disease progresses surgical removal may be indicated, but there is no indication at this time.
- Consider a low fat diet as this patient is at higher risk for developing pancreatitis and it may help with the obesity/weight gain.
- If signs of Cushing's are persistent and liver function is normal then consider adrenal function testing and possible sedation for imaging of the right adrenal gland.
- I recommend urinalysis and culture to rule out a urinary tract infection as a cause for PU/PD.





PATIENT

Burt Jennings

SPECIES

Canine

BREED

Dachshund

SEX

Neutered male

AGE

12 years

WEIGHT

16.6 lbs

INTERPRETED BY

Kathleen Sennello
DVM, MS, Diplomate
ACVIM (Small Animal
Internal Medicine)

IMAGING PERFORMED BY

Susanne Bush

HOSPITAL NAME

Great Miami VC

REFERRING VET

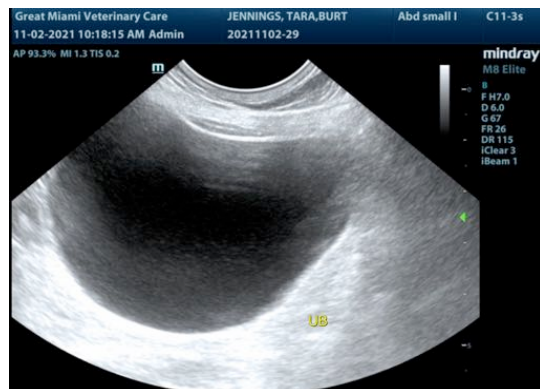
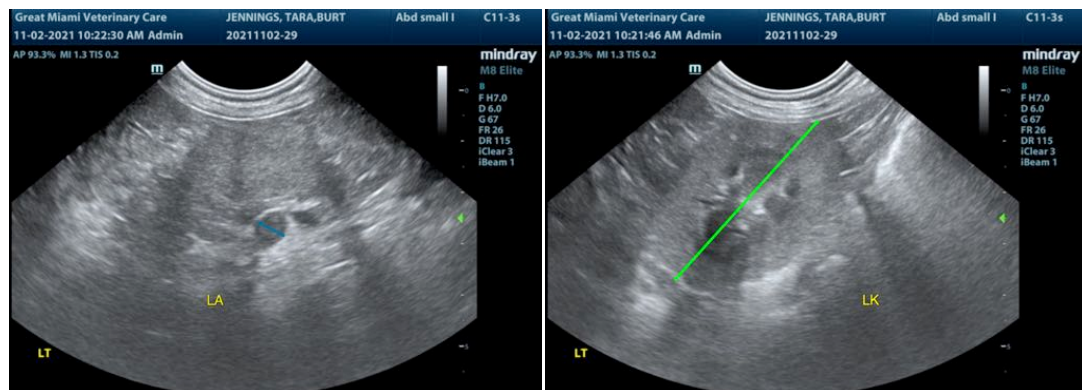
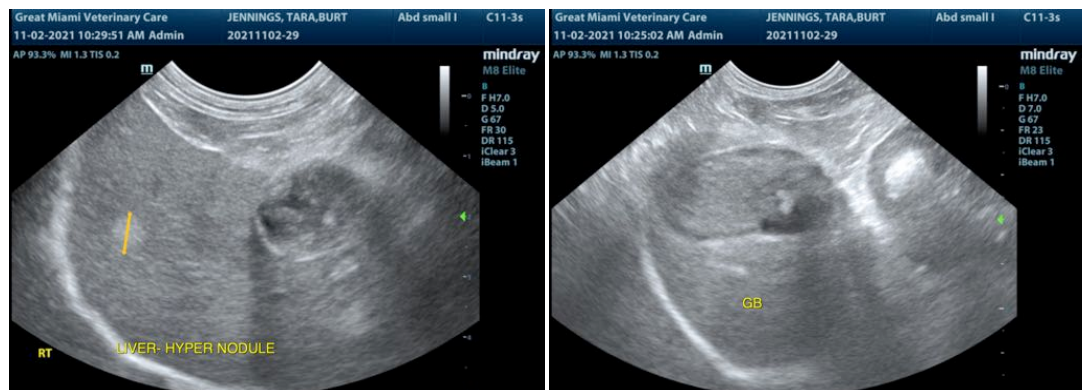
Dr. Bush

INVOICE

92806

DATE

11/2/21



The information and recommendations provided are based on the images presented by the referring veterinarian. No evaluation can be communicated regarding pathology that was not visible in the image/video clips provided.

Thank you for this referral. If the clinical or image interpretation does not parallel your findings or if I can be of any further assistance please contact me.

Kathleen Sennello DVM,MS, Diplomate ACVIM (Small animal Internal Medicine)
kathleen.sennello@sonopath.com