



## PATIENT

Maggie Belenkic

## SPECIES

Canine

## BREED

German Shepherd

## SEX

Spayed Female

## AGE

10 Years 10 Months

## WEIGHT

29.9 kg

## INTERPRETED BY

Kathleen Sennello DVM,  
MS, Diplomate ACVIM  
(Small Animal Internal  
Medicine)

## IMAGING PERFORMED BY

Mariusz Chmielinski,  
DVM

## HOSPITAL NAME

Apex Veterinary  
Services

## REFERRING VET

Alpine 24/7 ER

## INVOICE

71969

## DATE

11/19/25

## PRESENTING CLINICAL SIGNS

ADR, lethargic, marked weight loss

Abnormal PE/Chem/CBC/UA Results: Vital Signs: Temperature : 38.0, Heart Rate/min (HR):122, HR: Pulse Ratio: 1:1, Respiratory Rate/ min: panting , Respiratory Effort: 0, Mucus Membranes/ CRT: pale pink, tacky/ CRT< 2 sec ,Mentation: QAR ,Hydration: Adequate , BCS (scale 1 to 5): 2/5, CBC Mild non-regenerative anemia: Low HCT, low reticulocytes, microcytic/hypochromic RBCs. High RDW: RBC size variation (anisocytosis). Possible thrombocytopenia: Platelets  $76 \times 10^9/L$  Lymphopenia: Consistent with stress leukogram. WBC count overall normal. Chem: Severe liver injury: ALT >1000, ALP elevated. Low albumin and low cholesterol Amylase high Glucose slightly low. Kidney values (BUN/creatinine) normal; electrolytes normal. UA: USG 1.037 , Mild proteinuria, bilirubinuria, and trace hematuria. No bacteria, no crystals, no casts

## ULTRASONOGRAPHIC EXAMINATION OF THE ABDOMEN

### Urinary System

The urinary bladder is moderately distended with anechoic urine. The Bladder wall, trigone, ureteral papillae and visible urethra (to a depth of 2cm) appear normal with no evidence of wall thickening, mucosal irregularities, masses or cystic calculi.

The left kidney has a normal shape and size (8.31 cm) with a small cortical cyst measuring 0.34 cm. Overall echogenicity is normal with adequate corticomedullary distinction and a typical 1:3 cortex:medulla ratio. There is no evidence of focal perinephric inflammation or effusion. There is no evidence of pyelectasia, nephroliths, infarcts or hydroureter. Renal vasculature is normal.

The right kidney has a normal shape and size (8.57 cm). Overall echogenicity is normal with adequate corticomedullary distinction and a typical 1:3 cortex:medulla ratio. There is no evidence of focal perinephric inflammation or effusion. There is no evidence of pyelectasia, nephroliths, infarcts or hydroureter. Renal vasculature is normal.

### Adrenal Glands

The left adrenal gland is normal in size measuring 0.49 cm at the cranial pole and 0.61 cm at the caudal pole. It is observed in its normal position cranial to the left renal artery. It is normal in appearance (uniformly hypoechoic) and shape with no evidence of a mass effect.

The right adrenal gland is normal in size measuring 0.46 at the caudal pole (cranial pole not fully visualized). It is observed in its normal position between the cranial aspect of the right kidney and the caudal vena cava. It is normal in appearance (uniformly hypoechoic) and shape with no evidence of a mass effect.

### Spleen

The spleen is large and mottled. The blood flow through the hilus and splenic parenchyma appears normal. There are ill-defined hypoechoic nodules throughout the parenchyma, visualized more clearly with the high frequency probe.



## PATIENT

Maggie Belenkie

## SPECIES

Canine

## BREED

German Shepherd

## SEX

Spayed Female

## AGE

10 Years 10 Months

## WEIGHT

29.9 kg

## INTERPRETED BY

Kathleen Sennello DVM,  
MS, Diplomate ACVIM  
(Small Animal Internal  
Medicine)

## IMAGING PERFORMED BY

Mariusz Chmielinski,  
DVM

## HOSPITAL NAME

Apex Veterinary  
Services

## REFERRING VET

Alpine 24/7 ER

## INVOICE

71969

## DATE

11/19/25

## Liver

The liver is subjectively normal in size, and echogenicity with smooth peripheral margins. The parenchyma is heterogenous in echotexture with subtle, indistinct focal mottling. The visible portions of the vasculature and biliary tract appear normal. No focal nodules or cystic lesions are observed.

The gall bladder lumen is moderately distended. The gallbladder wall is prominent and hyperechoic, measuring 0.22 cm in width. There is a moderate amount of non-organized echogenic debris. The cystic and common bile ducts are normal/not visible.

## Gastrointestinal

The stomach contains mild/moderate fluid/gas. It measures at a normal thickness of 0.26 cm with some variability due to the presence of rugal folds. The distinction of the gastric wall layers is adequate and there is no impression of reduced peristaltic activity. Gas artifact interferes with full evaluation of the stomach and some areas of the cranial abdomen.

The visualized areas of duodenum, jejunum and ileum have a relatively uniform diameter with minimal fluid distension. Wall thickness is normal. Bowel loops follow a curvilinear path with distinct wall layering maintaining the typical 1:3 muscularis:mucosa layer ratio. Duodenum wall measures 0.34 cm. Jejunum wall measures 0.32 cm. Visualized peristalsis appears appropriate. There were no focal lesions consistent with obstruction or a mass effect observed.

The ileocecal junction was visualized and exhibited normal intact wall layering and is subjectively of normal thickness. Sections of colon are visualized with formed fecal material and gas shadowing distally. There is no observed focal or generalized colon wall thickening or loss of layering.

## Pancreas

The pancreas is prominent and mottled compared to the surrounding isoechoic mesentery. There is no evidence of nodules or cystic lesions. There is no evidence of regional mesenteric inflammation or fluid.

## Free Abdomen

Evaluation of the peritoneal cavity did not reveal any evidence of effusion, or subjective lymphadenomegaly. The Medial iliac nodes appear normal and there was no evidence of a caudal aortic thrombus at the bifurcation. The omentum is of normal uniform echogenicity.

## ULTRASONOGRAPHIC FINDINGS

- Large, mottled/nodular spleen – The diffuse splenic changes are non-specific and could be consistent with lymphoid hyperplasia, extramedullary hematopoiesis, infiltrative neoplasia, inflammation, other. Cytology or histopathology would be necessary to get a definitive diagnosis.
- Prominent, mottled pancreas – Findings are most consistent with chronic pancreatic remodeling +/- chronic pancreatitis.
- Moderate debris in the gallbladder with a prominent gallbladder wall – Findings could be incidental or consistent with mild cholecystitis.



## PATIENT

Maggie Belenkie

## SPECIES

Canine

## BREED

German Shepherd

## SEX

Spayed Female

## AGE

10 Years 10 Months

## WEIGHT

29.9 kg

## INTERPRETED BY

Kathleen Sennello DVM,  
MS, Diplomate ACVIM  
(Small Animal Internal  
Medicine)

## IMAGING PERFORMED BY

Mariusz Chmielinski,  
DVM

## HOSPITAL NAME

Apex Veterinary  
Services

## REFERRING VET

Alpine 24/7 ER

## INVOICE

71969

## DATE

11/19/25

## INTERPRETATION OF THE FINDINGS & FURTHER RECOMMENDATIONS

The changes observed in the liver are non-specific and diffuse. No focal lesions were observed. Based on the low albumin and blood glucose, there is concern for possible significant liver dysfunction.

Recommend pre- and post-prandial bile acids to assess further. Additionally, you could consider a fine needle aspirate (if coagulation parameters are normal) looking for any evidence of round cell neoplasia or similar.

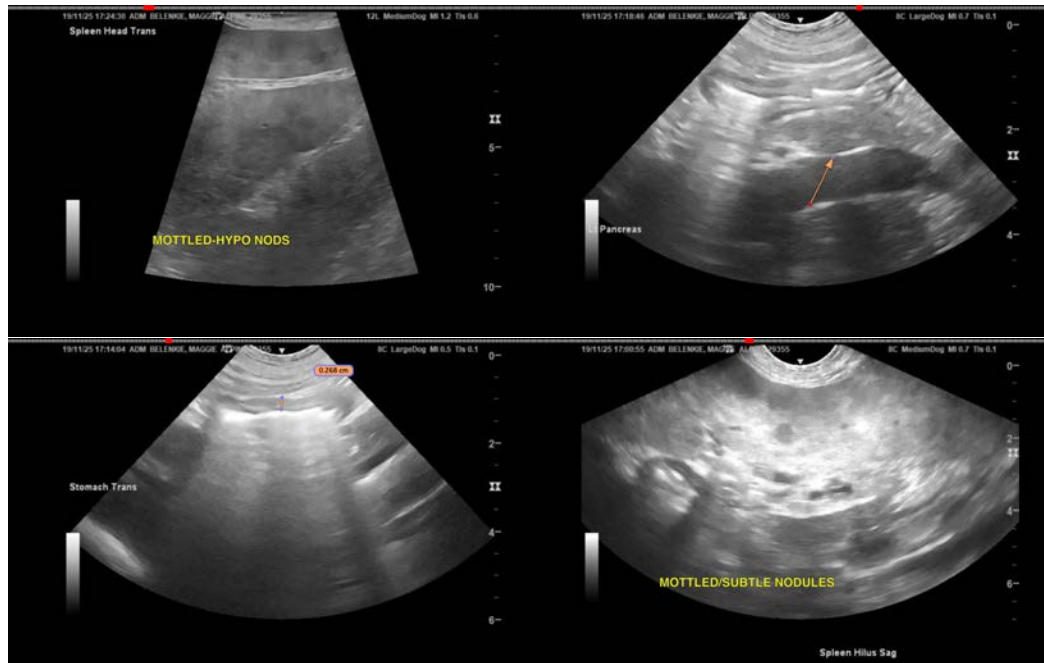
The spleen is subjectively large and mottled with some ill-defined hypoechoic nodules. This could be due to a primary pathology or regenerative changes secondary to anemia. Recommend a fine needle aspirate to further evaluate.

Both limbs of the pancreas are somewhat prominent and mottled. This is most consistent with chronic pancreatic remodeling, but mild inflammation is also possible. If clinical pancreatitis is suspected you could consider empirical treatment.

While awaiting cytologic results, recommend empirical treatment for acute liver injury with Ursodiol, Denamarin, and antibiotics.

If symptoms are worsening despite appropriate treatment, then consider repeat imaging, looking for the progression of today's lesions or the development of new lesions.

Recommend three view thoracic radiographs to evaluate for possible concurrent thoracic disease/involvement (disregard if this has already been done).





**PATIENT**

Maggie Belenkie

**SPECIES**

Canine

**BREED**

German Shepherd

**SEX**

Spayed Female

**AGE**

10 Years 10 Months

**WEIGHT**

29.9 kg

**INTERPRETED BY**

Kathleen Sennello DVM,  
MS, Diplomate ACVIM  
(Small Animal Internal  
Medicine)

**IMAGING PERFORMED BY**

Mariusz Chmielinski,  
DVM

**HOSPITAL NAME**

Apex Veterinary  
Services

**REFERRING VET**

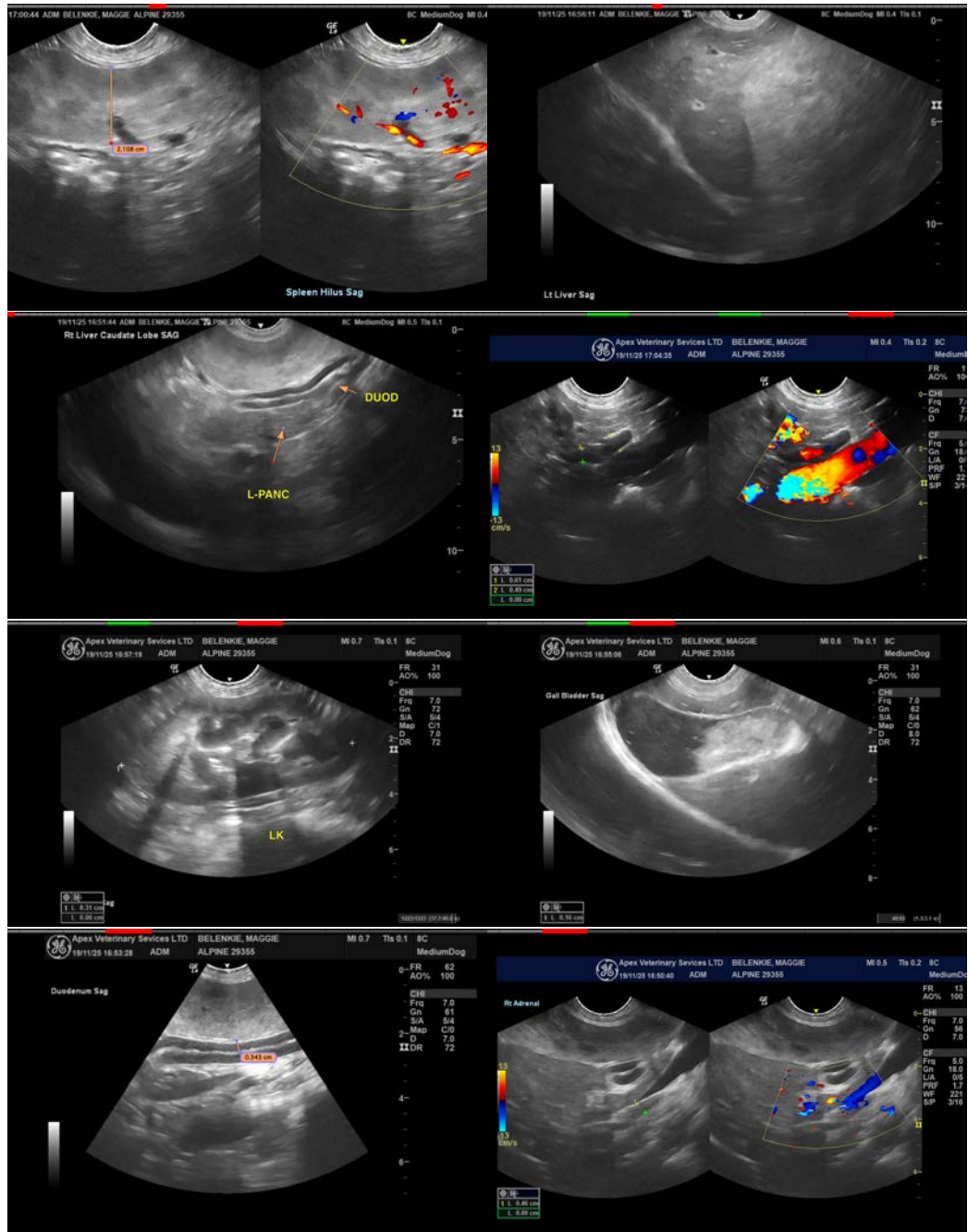
Alpine 24/7 ER

**INVOICE**

71969

**DATE**

11/19/25





## PATIENT

Maggie Belenkie

## SPECIES

Canine

## BREED

German Shepherd

## SEX

Spayed Female

## AGE

10 Years 10 Months

## WEIGHT

29.9 kg

## INTERPRETED BY

Kathleen Sennello DVM,  
MS, Diplomate ACVIM  
(Small Animal Internal  
Medicine)

## IMAGING PERFORMED BY

Mariusz Chmielinski,  
DVM

## HOSPITAL NAME

Apex Veterinary  
Services

## REFERRING VET

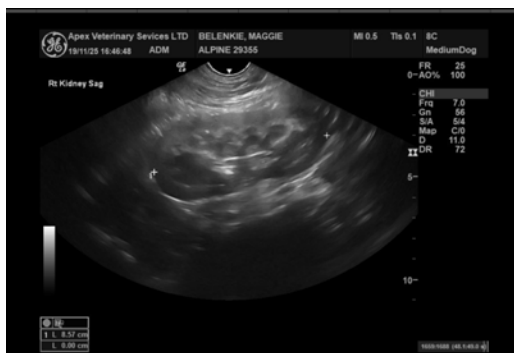Alpine 24/7 ER

## INVOICE

71969

## DATE

11/19/25



The information and recommendations provided are based on the images presented by the referring veterinarian/sonographer. No evaluation can be communicated regarding pathology that was not visible in the image/video clips provided.

Thank you for this referral. If the clinical or image interpretation does not parallel your findings or if I can be of any further assistance please contact me.

Kathleen Sennello DVM,MS, Diplomate ACVIM (Small animal Internal Medicine)

info@sonopath.com