



PATIENT

Chloe Flores

SPECIES

Canine

BREED

Shih Tzu

SEX

Intact Female

AGE

9 Years

WEIGHT

20.2 lbs

INTERPRETED BY

Kathleen Sennello DVM,
MS, Diplomate ACVIM
(Small Animal Internal
Medicine)

IMAGING PERFORMED BY

Gabriel Ferrer, DVM

HOSPITAL NAME

Pulse: Pet Ultrasound

REFERRING VET

Dr. David Munoz

INVOICE

71950

DATE

11/19/25

PRESENTING CLINICAL SIGNS

Presented as a referral for an abdominal ultrasound to evaluate elevated liver enzymes, and weight gain. Pt has been PU/PD, PP and had gained 6 #. All this started about 4 months ago. rDVM recommended u/s with emphasis on liver and adrenal glands for possible Cushing's disease.

Abnormal PE/Chem/CBC/UA Results: Bloodwork (cortisol, Bile acids and thyroid) attached as supporting documents.

ULTRASONOGRAPHIC EXAMINATION OF THE ABDOMEN

Urinary System

The urinary bladder is moderately distended with anechoic urine. The Bladder wall, trigone, ureteral papillae and visible urethra (to a depth of 2cm) appear normal with no evidence of wall thickening, mucosal irregularities, or masses. In the dependent portion of the urinary bladder there are hyperechoic shadowing foci most consistent with small stones/mineralized debris. An example measures 0.22 cm.

The left kidney has a normal shape and size (4.24 cm) with numerous pinpoint mineralizations. Overall echogenicity is normal with adequate corticomedullary distinction and a typical 1:3 cortex:medulla ratio. There is no evidence of focal perinephric inflammation or effusion. There is no evidence of pyelectasia, infarcts or hydroureter. Renal vasculature is normal.

The right kidney has a normal shape and size (4.44 cm) with numerous pinpoint mineralizations. Overall echogenicity is normal with adequate corticomedullary distinction and a typical 1:3 cortex:medulla ratio. There is no evidence of focal perinephric inflammation or effusion. There is no evidence of pyelectasia, infarcts or hydroureter. Renal vasculature is normal.

Adrenal Glands

The left adrenal gland is borderline large and slightly irregular in shape, measuring 0.65 cm at the cranial pole and 0.57 cm at the caudal pole. It is observed in its normal position cranial to the left renal artery. It is somewhat abnormal in appearance in that there is a poorly defined hyperechoic nodule in the cranial pole measuring 0.56 cm x 0.77 cm. No evidence of vascular invasion is visualized.

The right adrenal gland is normal in size measuring 0.45 cm at the cranial pole and 0.56 cm at the caudal pole. It is observed in its normal position between the cranial aspect of the right kidney and the caudal vena cava. It is normal in appearance (uniformly hypoechoic) and shape with no evidence of a mass effect.

Spleen

The spleen is subjectively normal in size, echotexture is homogenous, and the splenic capsule is smooth with no irregularities. The blood flow through the hilus and splenic parenchyma appears normal. No focal parenchymal abnormalities are visualized.

Liver

The liver is subjectively normal in size with smooth peripheral margins. The parenchyma is hyperechoic and homogenous in echotexture. The visible portions of the vasculature and biliary tract appear normal. No focal nodules or cystic lesions are observed.



PATIENT

Chloe Flores

The gall bladder lumen is moderately distended. The wall of the gall bladder is not thickened and has a smooth mucosal surface. There is a moderate amount of non-organized echogenic debris. The cystic and common bile ducts are normal/not visible.

SPECIES

Canine

Gastrointestinal

The stomach contains minimal luminal contents. It measures at a normal thickness of <0.7cm with some variability due to the presence of rugal folds. The distinction of the gastric wall layers is adequate and there is no impression of reduced peristaltic activity. No masses or focal lesions were observed.

BREED

Shih Tzu

The visualized areas of duodenum, jejunum and ileum have a relatively uniform diameter with minimal fluid distension. Wall thickness is normal. Bowel loops follow a curvilinear path with distinct wall layering maintaining the typical 1:3 muscularis:mucosa layer ratio. Duodenum wall measures 0.44 cm. Jejunum wall measures 0.37 cm. Visualized peristalsis appears appropriate. There were no focal lesions consistent with obstruction or a mass effect observed.

SEX

Intact Female

AGE

9 Years

Sections of colon are visualized with formed fecal material and gas shadowing distally. There is no observed focal or generalized colon wall thickening or loss of layering.

Pancreas

WEIGHT

20.2 lbs

The pancreas is normal and isoechoic to surrounding mesentery. There is no evidence of nodules or cystic lesions. There is no evidence of regional mesenteric inflammation or fluid.

Free Abdomen

INTERPRETED BY

Kathleen Sennello DVM,
MS, Diplomate ACVIM
(Small Animal Internal
Medicine)

Evaluation of the peritoneal cavity did not reveal any evidence of effusion, or subjective lymphadenomegaly. The Medial iliac nodes appear normal and there was no evidence of a caudal aortic thrombus at the bifurcation. The omentum is of normal uniform echogenicity.

Other

The uterine body is visualized and appears large, measuring at 1.14 cm in diameter.

IMAGING PERFORMED BY

Gabriel Ferrer, DVM

ULTRASONOGRAPHIC FINDINGS

HOSPITAL NAME

Pulse: Pet Ultrasound

- Small stones/mineralizations visualized in the dependent portion of the urinary bladder – Correlate with urinalysis, culture +/- radiographs.
- “Plump” left adrenal with a hyperechoic nodule in the cranial pole and normal right adrenal – The hyperechoic nodule currently has an appearance most consistent with a benign lesion (adenoma, focal hyperplasia). Recommend continued monitoring. Both adrenals are prominent and hypoechoic, but only the left exceeds normal size. Findings could be consistent with early hyperplasia.
- Hyperechoic liver – The diffuse hepatic changes are non-specific and can be seen with vacuolar hepatopathy, reactive change, nodular hyperplasia or, less likely, inflammatory/immune-mediated disease, infiltrative neoplasia, or other hepatopathy.
- Moderate gallbladder debris – The significance of the aggregated gallbladder debris is unclear. This could represent an early mucocele, cholestasis, or may be secondary to fasting but seems unlikely to be causing a current issue. Recommend continued monitoring.

REFERRING VET

Dr. David Munoz

INVOICE

71950

DATE

11/19/25



PATIENT

- Prominent/large uterus – Findings could be consistent with metritis or recent heat cycle.

Chloe Flores

INTERPRETATION OF THE FINDINGS & FURTHER RECOMMENDATIONS

SPECIES

The liver is hyperechoic and has an appearance most consistent with a vacuolar hepatopathy. This combined with the prominent adrenals increases concern for possible pituitary dependent hyperadrenocorticism, although the adrenals are not both officially large. Adrenal functioning is supportive of a cortisol excess. If there is concern, you could confirm this with an ACTH stimulation test.

Canine

BREED

It is difficult to definitively determine if this could be adrenal or pituitary dependent, as there is a lesion in the left adrenal, but it is very small at this time. If you feel strongly that the patient has Cushing's and want to treat medically, you can consider this and reevaluation of the left adrenal in 2-3 months, looking for further enlargement/significant change. Additionally, you could consider a contrast CT scan to further investigate.

Shih Tzu

SEX

There are small dependent mineralizations visualized in the urinary bladder. These are likely small enough to pass. Correlate with urinalysis and culture and consider dietary management if needed.

Intact Female

AGE

The uterine body appears large and prominent. This could be inflammatory, post heat cycle, or less likely neoplastic change. If there is significant concern, consider an ovariohysterectomy, as this dog is unlikely to have more litters at this age. Alternately, you could consider reevaluation in a few months to see if it has normalized in size.

9 Years

WEIGHT

20.2 lbs

INTERPRETED BY

Kathleen Sennello DVM,
MS, Diplomate ACVIM
(Small Animal Internal
Medicine)

IMAGING PERFORMED BY

Gabriel Ferrer, DVM

HOSPITAL NAME

Pulse: Pet Ultrasound

REFERRING VET

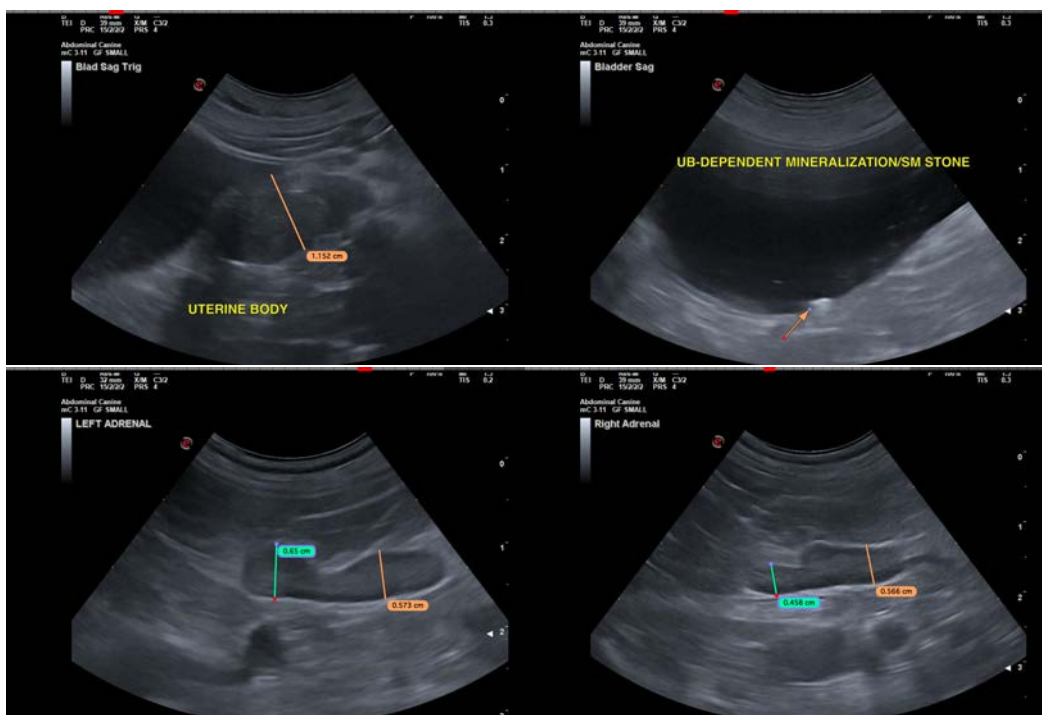
Dr. David Munoz

INVOICE

71950

DATE

11/19/25





PATIENT

Chloe Flores

SPECIES

Canine

BREED

Shih Tzu

SEX

Intact Female

AGE

9 Years

WEIGHT

20.2 lbs

INTERPRETED BY

Kathleen Sennello DVM,
MS, Diplomate ACVIM
(Small Animal Internal
Medicine)

IMAGING PERFORMED BY

Gabriel Ferrer, DVM

HOSPITAL NAME

Pulse: Pet Ultrasound

REFERRING VET

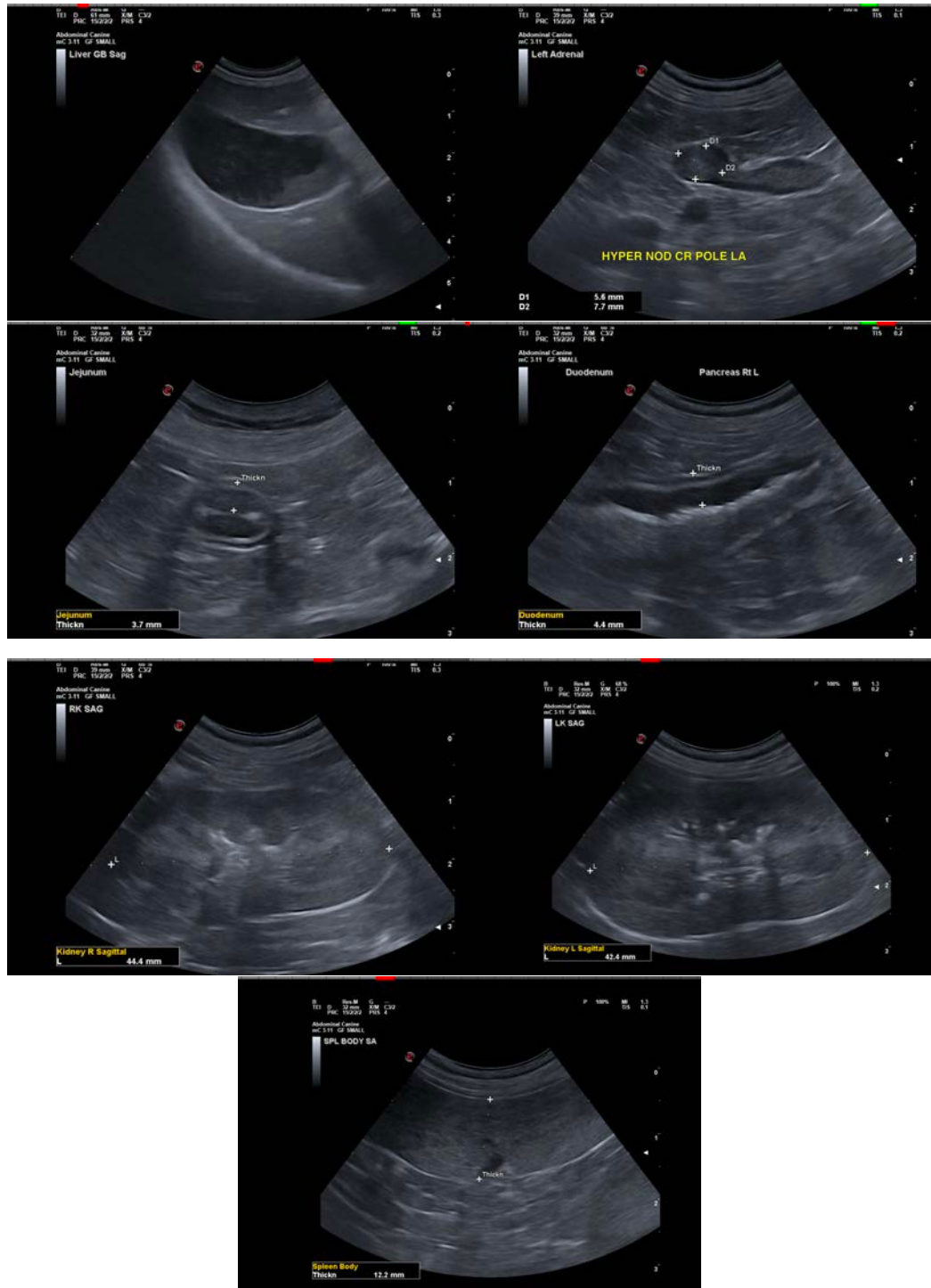
Dr. David Munoz

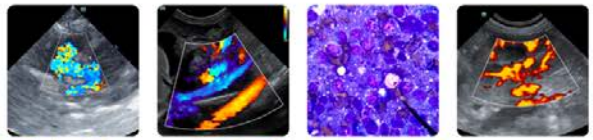
INVOICE

71950

DATE

11/19/25





PATIENT

Chloe Flores

SPECIES

Canine

BREED

Shih Tzu

SEX

Intact Female

AGE

9 Years

WEIGHT

20.2 lbs

INTERPRETED BY

Kathleen Sennello DVM,
MS, Diplomate ACVIM
(Small Animal Internal
Medicine)

IMAGING PERFORMED BY

Gabriel Ferrer, DVM

HOSPITAL NAME

Pulse: Pet Ultrasound

REFERRING VET

Dr. David Munoz

INVOICE

71950

DATE

11/19/25

The information and recommendations provided are based on the images presented by the referring veterinarian/sonographer. No evaluation can be communicated regarding pathology that was not visible in the image/video clips provided.

Thank you for this referral. If the clinical or image interpretation does not parallel your findings or if I can be of any further assistance please contact me.

Kathleen Sennello DVM,MS, Diplomate ACVIM (Small animal Internal Medicine)

info@sonopath.com