



PATIENT

Angie Rivera

SPECIES

Feline

BREED

Domestic Shorthair

SEX

Spayed Female

AGE

10 Years

WEIGHT

7.8 lbs

INTERPRETED BY

Kathleen Sennello DVM,
MS, Diplomate ACVIM
(Small Animal Internal
Medicine)

IMAGING PERFORMED BY

Gabriel Ferrer, DVM

HOSPITAL NAME

Pulse: Pet Ultrasound

REFERRING VET

Dr. Mario Roman

INVOICE

71949

DATE

11/19/25

PRESENTING CLINICAL SIGNS

Presented as a referral for an abdominal ultrasound to evaluate vomiting and constipation. Pt has a history of chronic hairballs and emesis, as well as constipation (for about 6 months). Angie improves greatly after treatment but eventually recurs. Last week vomiting had blood. rDVM discuss possibility of underlying disease including IBD, infectious vs parasitic disease, etc. Additionally on todays bloodwork Angie had markedly elevated hepatic values including ALT, ALKP, GGT and cholesterol. Currently taking: Laxatone supplementation, Lactulose: 2mL PO Q12 and Denamarin cat & small dog: 1 tablet PO Q24 Eating Hills Diet (urinary and airball control) for over 4 yrs.

Abnormal PE/Chem/CBC/UA Results: Bloodwork attached as supporting documents.

ULTRASONOGRAPHIC EXAMINATION OF THE ABDOMEN

Urinary System

The urinary bladder is moderately distended with mild primarily suspended echogenic debris present. The Bladder wall, trigone, ureteral papillae and visible urethra (to a depth of 2cm) appear normal with no evidence of wall thickening, mucosal irregularities, masses or calculi. Echogenic debris of this type can be associated with small crystals, cellular debris and proteinaceous debris.

The left kidney has a normal shape and size (3.56 cm). Overall echogenicity is normal with adequate corticomedullary distinction and a typical 1:3 cortex:medulla ratio. There is no evidence of focal perinephric inflammation or effusion. There is no evidence of pyelectasia, nephroliths, infarcts or hydroureter. Renal vasculature is normal.

The right kidney has a normal shape and size (3.64 cm). Overall echogenicity is normal with adequate corticomedullary distinction and a typical 1:3 cortex:medulla ratio. There is no evidence of focal perinephric inflammation or effusion. There is no evidence of pyelectasia, nephroliths, infarcts or hydroureter. Renal vasculature is normal.

Adrenal Glands

The left adrenal gland is normal in size measuring 0.37 cm at the caudal pole. It is observed in its normal position cranial to the left renal artery. It is normal in appearance (uniformly hypoechoic) and shape with no evidence of a mass effect.

The right adrenal gland is normal in size measuring 0.25 cm at the caudal pole. It is observed in its normal position between the cranial aspect of the right kidney and the caudal vena cava. It is normal in appearance (uniformly hypoechoic) and shape with no evidence of a mass effect.

Spleen

The spleen is subjectively normal in size (0.71 cm), echotexture is homogenous, and the splenic capsule is smooth with no irregularities. The blood flow through the hilus and splenic parenchyma appears normal. No focal parenchymal abnormalities are visualized.

Liver

The liver is subjectively normal in size, and echogenicity with smooth peripheral margins. The parenchyma is mildly heterogenous in echotexture with subtle, indistinct focal mottling. The visible



PATIENT

Angie Rivera

SPECIES

Feline

BREED

Domestic Shorthair

SEX

Spayed Female

AGE

10 Years

WEIGHT

7.8 lbs

INTERPRETED BY

Kathleen Sennello DVM,
MS, Diplomate ACVIM
(Small Animal Internal
Medicine)

IMAGING PERFORMED BY

Gabriel Ferrer, DVM

HOSPITAL NAME

Pulse: Pet Ultrasound

REFERRING VET

Dr. Mario Roman

INVOICE

71949

DATE

11/19/25

portions of the vasculature and biliary tract appear normal. No focal nodules or cystic lesions are observed.

The gall bladder lumen is moderately distended. The gallbladder wall is prominent and slightly hyperechoic, measuring at 0.11 cm. There is a moderate amount of non-organized echogenic debris. The debris appears to extend into the cystic duct, which appears mildly dilated, measuring at 0.20 cm.

Gastrointestinal

The stomach contains mild/moderate fluid. It measures at a normal thickness of <0.36cm with some variability due to the presence of rugal folds. The distinction of the gastric wall layers is adequate and there is no impression of reduced peristaltic activity. No masses or focal lesions were observed.

The visualized areas of duodenum, jejunum and ileum have a uniform diameter with minimal fluid distension. Wall thickness is normal to slightly increased. Bowel loops follow a typical curvilinear path with distinct wall layering, but some areas display a prominent muscularis layer which does not display the typical 1:3 muscularis:mucosa layer ratio. Duodenum wall measures 0.24 cm. Jejunum wall measures 0.27 cm. Visualized peristalsis appears appropriate. There are some areas of jejunum that exhibit segmental prominence of the muscularis layer.

Sections of colon are visualized with formed fecal material and gas shadowing distally. There is no observed focal or generalized colon wall thickening or loss of layering.

Pancreas

The pancreas is normal and isoechoic to surrounding mesentery. There is no evidence of nodules or cystic lesions. There is no evidence of regional mesenteric inflammation or fluid.

Free Abdomen

Evaluation of the peritoneal cavity did not reveal any evidence of effusion. There are occasional prominent mesenteric lymph nodes. There are two lymph nodes visualized near the ileocecal junction measuring 0.31 cm and 0.21 cm. The omentum is generally of normal echogenicity.

ULTRASONOGRAPHIC FINDINGS

- Suspended echogenic debris in the urinary bladder – The echogenic debris in the bladder lumen could be consistent with cells, crystals, and/or mucus.
- Mildly heterogeneous liver – Hepatic changes are non-specific and could be consistent with inflammation/infection (cholangiohepatitis), infiltrative neoplasia, lipidosis or other hepatopathy.
- Moderate debris visualized in the gallbladder with a prominent/mildly thickened, hyperechoic gallbladder wall and debris extending into the cystic duct – Findings could be consistent with mild cholecystitis
- Segmental thickening of the muscularis layer of the small intestine – The small intestinal wall changes are most consistent with an inflammatory process (i.e., inflammatory bowel disease) with a low possibility of emerging lymphoma.
- Occasional reactive mesenteric lymph nodes.



PATIENT

Angie Rivera

SPECIES

Feline

BREED

Domestic Shorthair

SEX

Spayed Female

AGE

10 Years

WEIGHT

7.8 lbs

INTERPRETED BY

Kathleen Sennello DVM,
MS, Diplomate ACVIM
(Small Animal Internal
Medicine)

IMAGING PERFORMED BY

Gabriel Ferrer, DVM

HOSPITAL NAME

Pulse: Pet Ultrasound

REFERRING VET

Dr. Mario Roman

INVOICE

71949

DATE

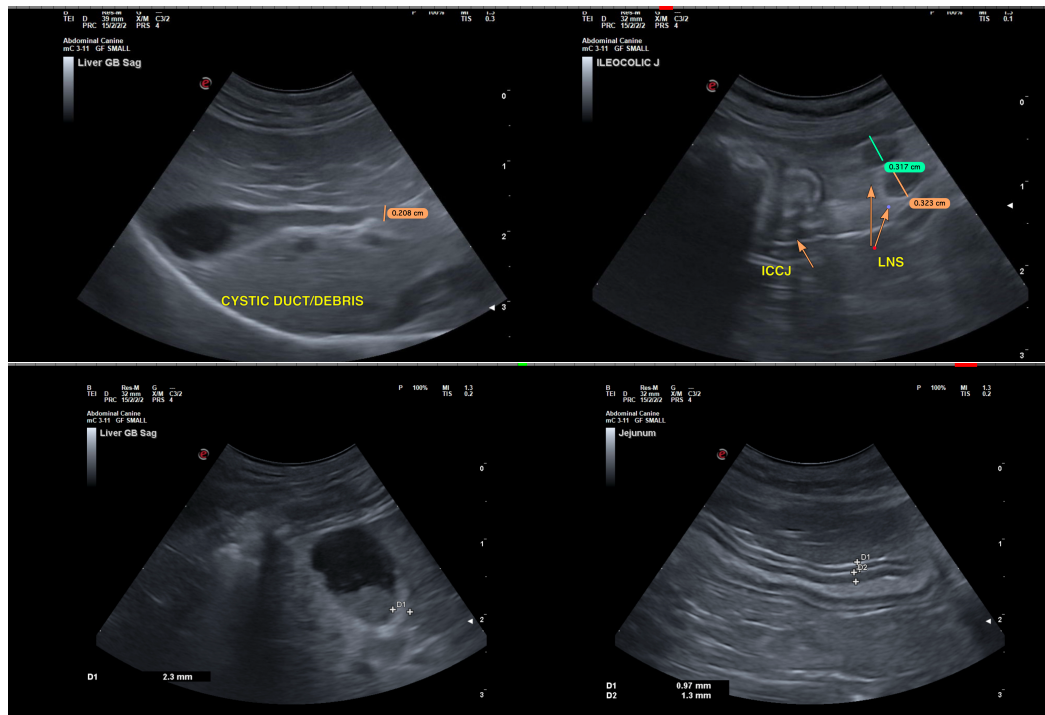
11/19/25

INTERPRETATION OF THE FINDINGS & FURTHER RECOMMENDATIONS

The liver appears mildly heterogeneous. This is a non-specific finding. Consider pre- and post-prandial bile acids to further assess liver function, and screening for toxoplasmosis if clinically appropriate.

The gallbladder has moderate debris, and the gallbladder wall appears slightly prominent. Additionally, some sections of small intestine appear somewhat “ropey” with a prominent muscularis layer. This is most consistent with inflammatory type change. Consider possible treatment for cholecystitis with Ursodiol, Denamarin, and a course of antibiotics, as well as initial treatment for possible IBD with a hypoallergenic diet. Additionally recommend a GI panel to Texas A&M for a qualitative fPLI, TLI, cobalamin and folate, and probiotic therapy. If liver values do not improve, you could consider a fine needle aspirate of the liver to rule out underlying round cell neoplasia. Additionally, a liver biopsy may be necessary to further evaluate (samples for cultures and histopathology). If liver biopsies are obtained, consider biopsies of the GI tract as well to evaluate for possible underlying inflammatory or early neoplastic disease.

Consider chronic fiber supplementation and Miralax added to the food. Titrate to a slightly soft stool to try to prevent future episodes of constipation. I suspect they are associated with mild dehydration, which may be secondary to a flare up of illness.





PATIENT

Angie Rivera

SPECIES

Feline

BREED

Domestic Shorthair

SEX

Spayed Female

AGE

10 Years

WEIGHT

7.8 lbs

INTERPRETED BY

Kathleen Sennello DVM,
MS, Diplomate ACVIM
(Small Animal Internal
Medicine)

**IMAGING
PERFORMED BY**

Gabriel Ferrer, DVM

HOSPITAL NAME

Pulse: Pet Ultrasound

REFERRING VET

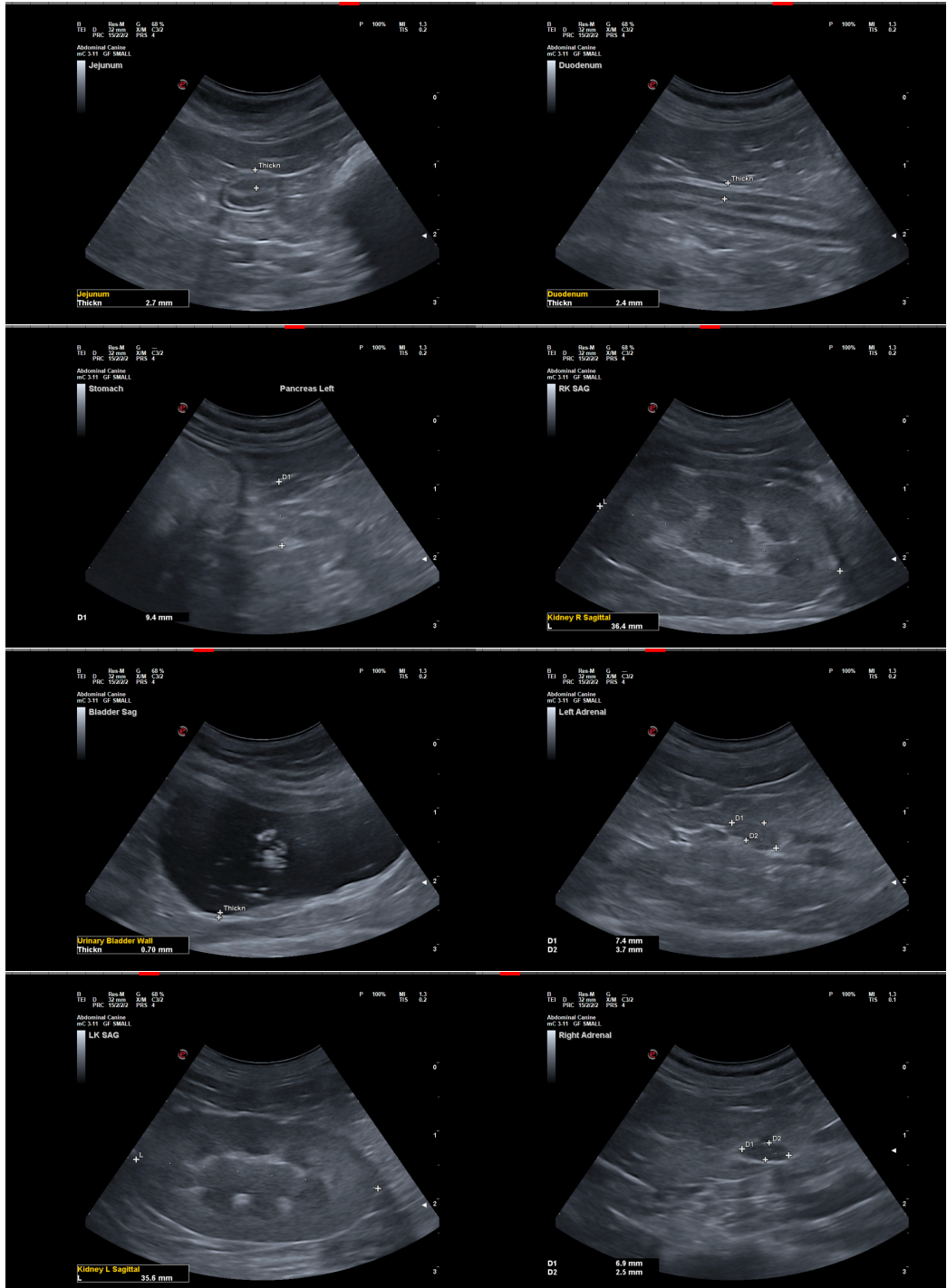
Dr. Mario Roman

INVOICE

71949

DATE

11/19/25





PATIENT

Angie Rivera

SPECIES

Feline

BREED

Domestic Shorthair

SEX

Spayed Female

AGE

10 Years

WEIGHT

7.8 lbs

INTERPRETED BY

Kathleen Sennello DVM,
MS, Diplomate ACVIM
(Small Animal Internal
Medicine)

IMAGING PERFORMED BY

Gabriel Ferrer, DVM

HOSPITAL NAME

Pulse: Pet Ultrasound

REFERRING VET

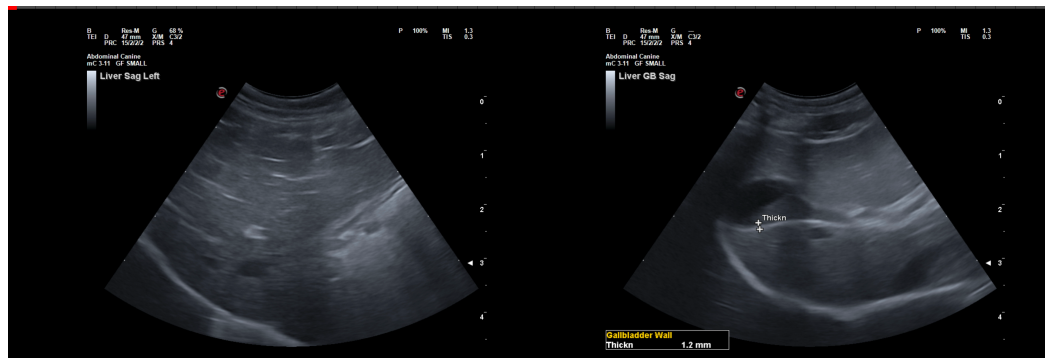
Dr. Mario Roman

INVOICE

71949

DATE

11/19/25



The information and recommendations provided are based on the images presented by the referring veterinarian/sonographer. No evaluation can be communicated regarding pathology that was not visible in the image/video clips provided.

Thank you for this referral. If the clinical or image interpretation does not parallel your findings or if I can be of any further assistance please contact me.

Kathleen Sennello DVM,MS, Diplomate ACVIM (Small animal Internal Medicine)

info@sonopath.com