



## PATIENT

Max Dey

## SPECIES

Canine

## BREED

Pitbull

## SEX

Neutered Male

## AGE

10 years old

## WEIGHT

84 lbs

## INTERPRETED BY

Kathleen Sennello DVM,  
MS, Diplomate ACVIM  
(Small Animal Internal  
Medicine)

## IMAGING PERFORMED BY

Dr. Elaina Petrone

## HOSPITAL NAME

Long Branch Animal  
Hospital

## REFERRING VET

Dr. Elaina Petrone

## INVOICE

10770

## DATE

11/18/2025

## PRESENTING CLINICAL SIGNS

Elevated ALP with no response to Denamarin. Clinically doing well.

## ULTRASONOGRAPHIC EXAMINATION OF THE ABDOMEN

### Urinary System

The urinary bladder is moderately distended with anechoic urine. The Bladder wall, trigone, ureteral papillae and visible urethra (to a depth of 2cm) appear normal with no evidence of wall thickening, mucosal irregularities, masses or cystic calculi.

The visualized areas of prostate and surrounding tissue appear normal. Unfortunately, the prostate is not fully visualized likely due to its intrapelvic location. Correlate with rectal exam findings.

The left kidney has a normal shape and size (7.49 cm). Overall echogenicity is normal with adequate corticomedullary distinction and a typical 1:3 cortex:medulla ratio. There is no evidence of focal perinephric inflammation or effusion. There is no evidence of pyelectasia, nephroliths, infarcts or hydroureter. Renal vasculature is normal.

The right kidney has a normal shape and size (5.78 cm). Overall echogenicity is normal with adequate corticomedullary distinction and a typical 1:3 cortex:medulla ratio. There is no evidence of focal perinephric inflammation or effusion. There is no evidence of pyelectasia, nephroliths, infarcts or hydroureter. Renal vasculature is normal.

### Adrenal Glands

The left adrenal gland is normal in size measuring 0.61 cm at the cranial pole and 0.6 cm at the caudal pole. It is observed in its normal position cranial to the left renal artery. It is normal in appearance (uniformly hypoechoic) and shape with no evidence of a mass effect.

In the region of the right adrenal gland there is a structure most consistent with the caudal pole of the right adrenal measuring 1.1 cm.

### Spleen

The spleen is subjectively normal in size (3.0 cm) and the echotexture is homogenous. The splenic capsule is smooth with no visible irregularities. The blood flow through the hilus and splenic parenchyma appears normal.

### Liver

The liver is normal in size, and normal in echogenicity with smooth peripheral margins. The parenchyma is mildly heterogenous in echotexture with subtle, indistinct focal mottling. The visible portions of the vasculature and biliary tract appear normal. No focal nodules or cystic lesions are observed.

The gall bladder lumen is moderately distended. The wall of the gall bladder is not thickened and has a smooth mucosal surface. Luminal contents are mild and likely incidental at this time. The cystic and common bile ducts are normal/not visible.

### Gastrointestinal



## PATIENT

Max Dey

## SPECIES

Canine

## BREED

Pitbull

## SEX

Neutered Male

## AGE

10 years old

## WEIGHT

84 lbs

## INTERPRETED BY

Kathleen Sennello DVM,  
MS, Diplomate ACVIM  
(Small Animal Internal  
Medicine)

## IMAGING PERFORMED BY

Dr. Elaina Petrone

## HOSPITAL NAME

Long Branch Animal  
Hospital

## REFERRING VET

Dr. Elaina Petrone

## INVOICE

10770

## DATE

11/18/2025

The stomach contains minimal luminal contents. It measures at a normal thickness of <0.7cm with some variability due to the presence of rugal folds. The distinction of the gastric wall layers is adequate and there is no impression of reduced peristaltic activity. No masses or focal lesions were observed.

The visualized areas of duodenum, jejunum and ileum have a relatively uniform diameter with minimal fluid distension. Wall thickness is normal. Bowel loops follow a curvilinear path with distinct wall layering maintaining the typical 1:3 muscularis:mucosa layer ratio. The duodenum measured as normal (between 0.3-0.5cm in wall thickness) and the jejunum measured as normal (0.29 cm.) Visualized peristalsis appears appropriate. There were no focal lesions consistent with obstruction or a mass effect observed.

Sections of colon are visualized with formed fecal material and gas shadowing distally. There is no observed focal or generalized colon wall thickening or loss of layering.

### **Pancreas**

The pancreas is normal and isoechoic to surrounding mesentery. There is no evidence of nodules or cystic lesions. There is no evidence of regional mesenteric inflammation or fluid.

### **Free Abdomen**

Evaluation of the peritoneal cavity did not reveal any evidence of effusion, or subjective lymphadenomegaly. The Medial iliac nodes appear normal and there was no evidence of a caudal aortic thrombus at the bifurcation. The omentum is of normal uniform echogenicity.

## **ULTRASONOGRAPHIC FINDINGS**

- Mildly heterogenous liver. Findings could be consistent with a vacuolar hepatopathy. Other hepatopathies are possible.
- Prominent caudal pole of the right adrenal. The adrenal is difficult to clearly visualize. Mild enlargement may be present.

## **INTERPRETATION OF THE FINDINGS & FURTHER RECOMMENDATIONS**

No focal lesions are visualized associated with the liver or the gallbladder to explain the elevation in ALP reported. The appearance is most consistent with a vacuolar hepatopathy, although other hepatopathies are possible. If signs of Cushing's are present, you could consider adrenal function testing. Otherwise, recommend a liver function test as a baseline and continued monitoring of the liver, with reassessment overtime if liver values continue to rise. A fine needle aspirate could be considered if there's concern for underlying round cell neoplasia or other hepatopathies.



**PATIENT**

Max Dey

**SPECIES**

Canine

**BREED**

Pitbull

**SEX**

Neutered Male

**AGE**

10 years old

**WEIGHT**

84 lbs

**INTERPRETED BY**

Kathleen Sennello DVM,  
MS, Diplomate ACVIM  
(Small Animal Internal  
Medicine)

**IMAGING  
PERFORMED BY**

Dr. Elaina Petrone

**HOSPITAL NAME**

Long Branch Animal  
Hospital

**REFERRING VET**

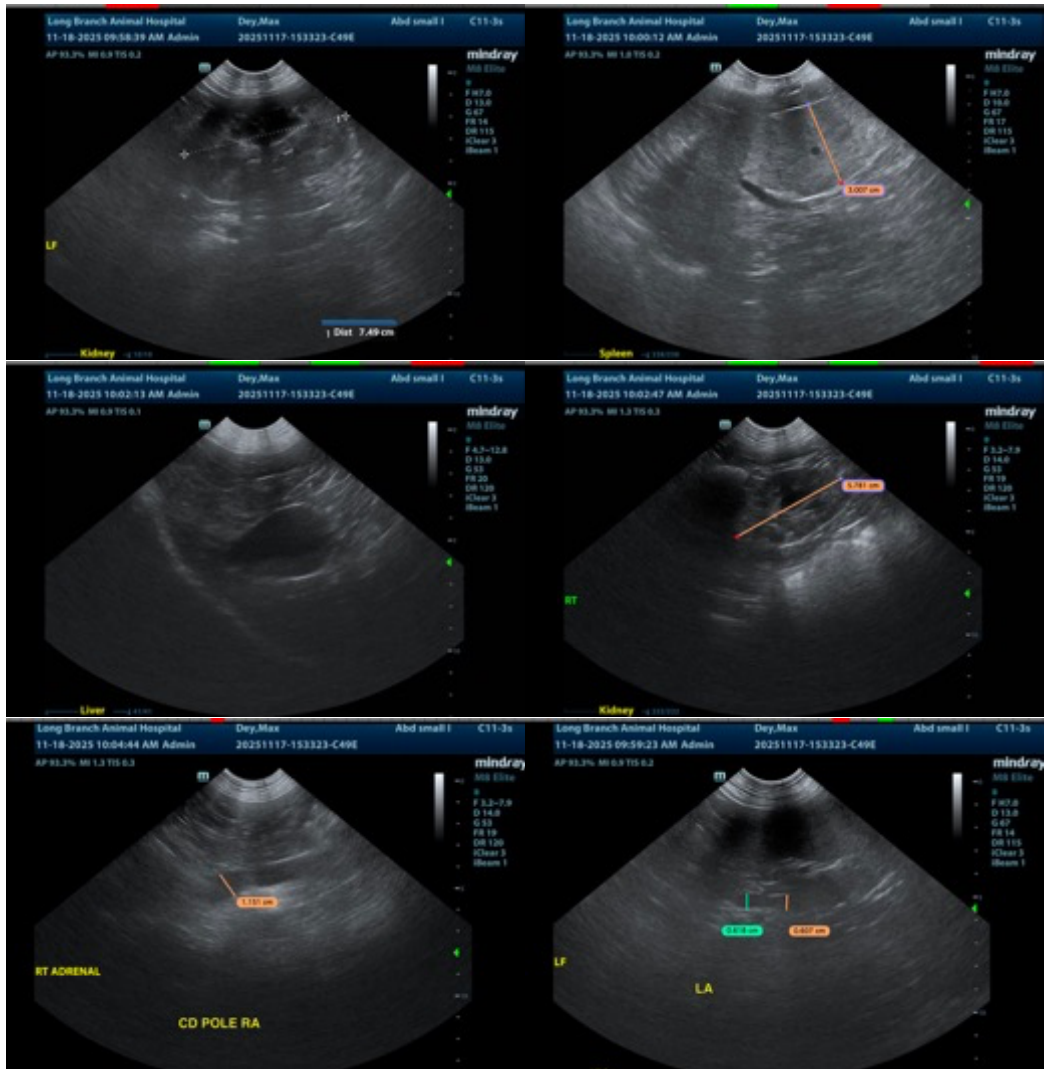
Dr. Elaina Petrone

**INVOICE**

10770

**DATE**

11/18/2025



The information and recommendations provided are based on the images presented by the referring veterinarian/sonographer. No evaluation can be communicated regarding pathology that was not visible in the image/video clips provided.

Thank you for this referral. If the clinical or image interpretation does not parallel your findings or if I can be of any further assistance please contact me.

Kathleen Sennello DVM,MS, Diplomate ACVIM (Small animal Internal Medicine)

info@sonopath.com