



**PATIENT PRESENTING CLINICAL SIGNS**

Andy Gale

Last ultrasound Nov 3/22. This is a follow up. Previous ultrasound Nov 2022 and history sent previously for that. Pancreatitis with liver and lymph node changes. Treatment with tramadol, enrofloxacin, clindamycin was completed. Andy is still on low fat diet, and has been doing very well since shortly after starting meds. No meds currently. Repeating to assess hepatic/pancreatic/lymph node change post pancreatitis

**SPECIES**

Canine

**BREED**

Cocker Spaniel

Abnormal PE/Chem/CBC/UA Results: Original blood work Nov 3rd repeated Nov 14 shows normalization of CBC, Amylase, lipase, Spec cPL but increased ALP (and ALT within the reference range).

**ULTRASONOGRAPHIC EXAMINATION OF THE ABDOMEN**

**SEX**

Neutered Male

**Urinary System**

The urinary bladder is moderately distended with anechoic urine. The Bladder wall, trigone, ureteral papillae and visible urethra (to a depth of 2cm) appear normal with no evidence of wall thickening, mucosal irregularities, masses or cystic calculi.

**AGE**

11 Years

The prostate is normal in size (0.88 cm) and shape for this neutered male dog. The parenchyma is homogenous and the external margins are smooth. The prostatic urethra appears normal with no evidence of irregularity, invasion, mass effect or calculi.

**WEIGHT**

14.7 kg

The left kidney has a normal shape and size (5.31 cm). Overall echogenicity is normal with adequate corticomedullary distinction and a typical 1:3 cortex:medulla ratio. There is no evidence of focal perinephric inflammation or effusion. There is no evidence of pyelectasia, nephroliths, infarcts or hydroureter. Renal vasculature is normal.

**INTERPRETED BY**

Kathleen Sennello DVM,  
MS, Diplomate ACVIM  
(Small Animal Internal  
Medicine)

The right kidney has a normal shape and size (6.47 cm). Overall echogenicity is normal with adequate corticomedullary distinction and a typical 1:3 cortex:medulla ratio. There is no evidence of focal perinephric inflammation or effusion. There is no evidence of pyelectasia, nephroliths, infarcts or hydroureter. Renal vasculature is normal.

**IMAGING PERFORMED BY**

Crystal Hill

**Adrenal Glands**

The left adrenal gland is normal in size measuring 0.50 cm at the caudal pole. It is observed in its normal position cranial to the left renal artery. It is normal in appearance (uniformly hypoechoic) and shape with no evidence of a mass effect.

**HOSPITAL NAME**

Chippawa AH

The right adrenal gland is normal in size measuring 0.39 cm at the caudal pole. It is observed in its normal position between the cranial aspect of the right kidney and the caudal vena cava. It is normal in appearance (uniformly hypoechoic) and shape with no evidence of a mass effect.

**REFERRING VET**

Dr. Dowell

**Spleen**

The spleen is subjectively normal in size, echotexture is homogenous, and the splenic capsule is smooth with no irregularities. The blood flow through the hilus and splenic parenchyma appears normal. No focal parenchymal abnormalities are visualized.

**INVOICE**

42835

**Liver**

The liver is large in size, and normal in echogenicity with smooth peripheral margins. The parenchyma is heterogenous in echotexture with subtle, indistinct focal mottling. The visible portions of the

**DATE**

11/17/22


**PATIENT**

Andy Gale

vasculature and biliary tract appear normal. There are numerous ill-defined hypoechoic nodules within the parenchyma of the liver. One of these nodules on the right side measures at 1.0 cm.

**SPECIES**

Canine

The gall bladder lumen is moderately distended. The wall of the gall bladder is not thickened and has a smooth mucosal surface. There is a moderate amount of non-organized echogenic debris. The cystic and common bile ducts are normal/not visible.

**BREED**

Cocker Spaniel

The stomach contains minimal luminal contents. It measures at a normal thickness of <0.7cm with some variability due to the presence of rugal folds. The distinction of the gastric wall layers is adequate and there is no impression of reduced peristaltic activity. No masses or focal lesions were observed.

**SEX**

Neutered Male

The visualized areas of duodenum, jejunum and ileum have a relatively uniform diameter with minimal fluid distension. Wall thickness is normal. Bowel loops follow a curvilinear path with distinct wall layering maintaining the typical 1:3 muscularis:mucosa layer ratio. Duodenum wall measures 0.39 cm. Jejunum wall measures 0.27 cm. Visualized peristalsis appears appropriate. There were no focal lesions consistent with obstruction or a mass effect observed.

**AGE**

11 Years

The ileocecal junction was visualized and exhibited normal intact wall layering and is subjectively of normal thickness. Sections of colon are visualized with formed fecal material and gas shadowing distally. There is no observed focal or generalized colon wall thickening or loss of layering.

**WEIGHT**

14.7 kg

**Pancreas**

Much of the left limb of the pancreas appears normal and is isoechoic to the surrounding mesentery. The right limb of the pancreas, which was previously abnormal appears persistently irregular and hypoechoic, surrounded by hyperechoic mesentery. This area appears similar to/slightly improved from the previous scan 3/22.

**INTERPRETED BY**

 Kathleen Sennello DVM,  
 MS, Diplomate ACVIM  
 (Small Animal Internal  
 Medicine)

**Free Abdomen**

Evaluation of the peritoneal cavity did not reveal any evidence of effusion. No significant lymphadenopathy noted. The omentum is hyperechoic in the right cranial abdomen.

**IMAGING PERFORMED BY**

Crystal Hill

**ULTRASONOGRAPHIC FINDINGS**
**HOSPITAL NAME**

Chippawa AH

- Prominent, irregular right limb of the pancreas with surrounding hyperechoic mesentery – Findings could be consistent with chronic pancreatic inflammation, remodeling, or possibly an extension of irregular hepatic tissue.
- Large, heterogeneous liver with ill-defined hypoechoic nodules – The diffuse hepatic changes are non-specific and could be consistent with vacuolar hepatopathy, nodular hyperplasia, inflammatory/immune-mediated disease, fibrosis, extramedullary hematopoiesis, toxic hepatopathy (e.g., copper), infiltrative neoplasia (less likely) or other hepatopathy. The nodules observed trend toward a more benign process but underlying neoplasia cannot be ruled out.
- Moderate gallbladder debris – The significance of the aggregated gallbladder debris is unclear. This could represent an early mucocele, cholestasis, or may be secondary to fasting but seems unlikely to be causing a current issue. Recommend continued monitoring.

**REFERRING VET**

Dr. Dowell

**INVOICE**

42835

**INTERPRETATION OF THE FINDINGS & FURTHER RECOMMENDATIONS**

I'm pleased that this patient is doing so much better. There is no evidence of significant lymphadenopathy on today's exam, and the changes in the liver and pancreas have not progressed. Surprisingly, the irregular area in the right cranial abdomen that has the appearance of significantly

**DATE**

11/17/22



**PATIENT**

Andy Gale

**SPECIES**

Canine

**BREED**

Cocker Spaniel

**SEX**

Neutered Male

**AGE**

11 Years

**WEIGHT**

14.7 kg

inflamed pancreatic tissue is still present. It has not progressed and may be slightly improved, so the significant of this lesion is questionable and I cannot definitively rule out the possibility of an extension of irregular hepatic tissue in the area. You could consider a fine needle aspirate in this region, although it may be challenging to reach. Alternately, you could consider a contrast CT scan, which may provide better detail to differentiate the tissues more definitively. A fast growing mass effect seems much less likely, as this does not appear to have changed significantly. These are options to consider when evaluating an elevation in liver enzymes:

- Consider close evaluation of history for possible toxic changes examine medications, diet, dietary indiscretion etc...
- Consider PCR on urine/serum for leptospirosis (if not on antibiotics)/serology if recent antibiotic history
- If not already done, consider pre and post prandial bile acids to evaluate liver function
- If the ALP is significantly elevated relative to the ALT and symptoms consistent with Cushing's are present, consider adrenal function testing (ACTH stim)
- Consider Fine needle aspirate if round cell neoplasia is on your differentia list (25 g needle, normal coags)
- If no response to supportive care (Denamarin, fluids, antibiotics, +/- ursodiol etc.) Consider liver biopsy with samples obtained for histopathology, culture, and copper levels.

Recommend continued monitoring of the irregular tissue in the right cranial abdomen.

**INTERPRETED BY**

Kathleen Sennello DVM,  
MS, Diplomate ACVIM  
(Small Animal Internal  
Medicine)

**IMAGING PERFORMED BY**

Crystal Hill

**HOSPITAL NAME**

Chippawa AH

**REFERRING VET**

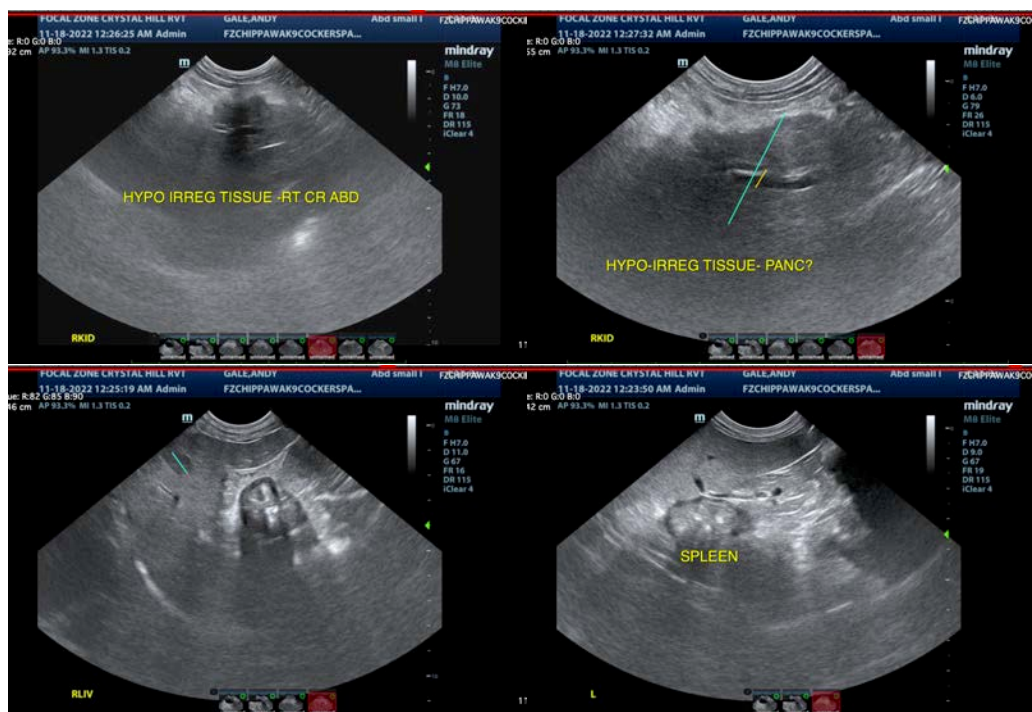
Dr. Dowell

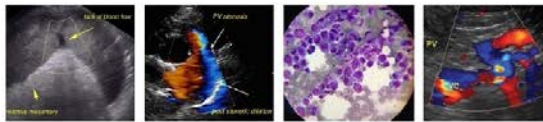
**INVOICE**

42835

**DATE**

11/17/22





**PATIENT**

Andy Gale

**SPECIES**

Canine

**BREED**

Cocker Spaniel

**SEX**

Neutered Male

**AGE**

11 Years

**WEIGHT**

14.7 kg

**INTERPRETED BY**

Kathleen Sennello DVM,  
MS, Diplomate ACVIM  
(Small Animal Internal  
Medicine)

**IMAGING  
PERFORMED BY**

Crystal Hill

**HOSPITAL NAME**

Chippawa AH

**REFERRING VET**

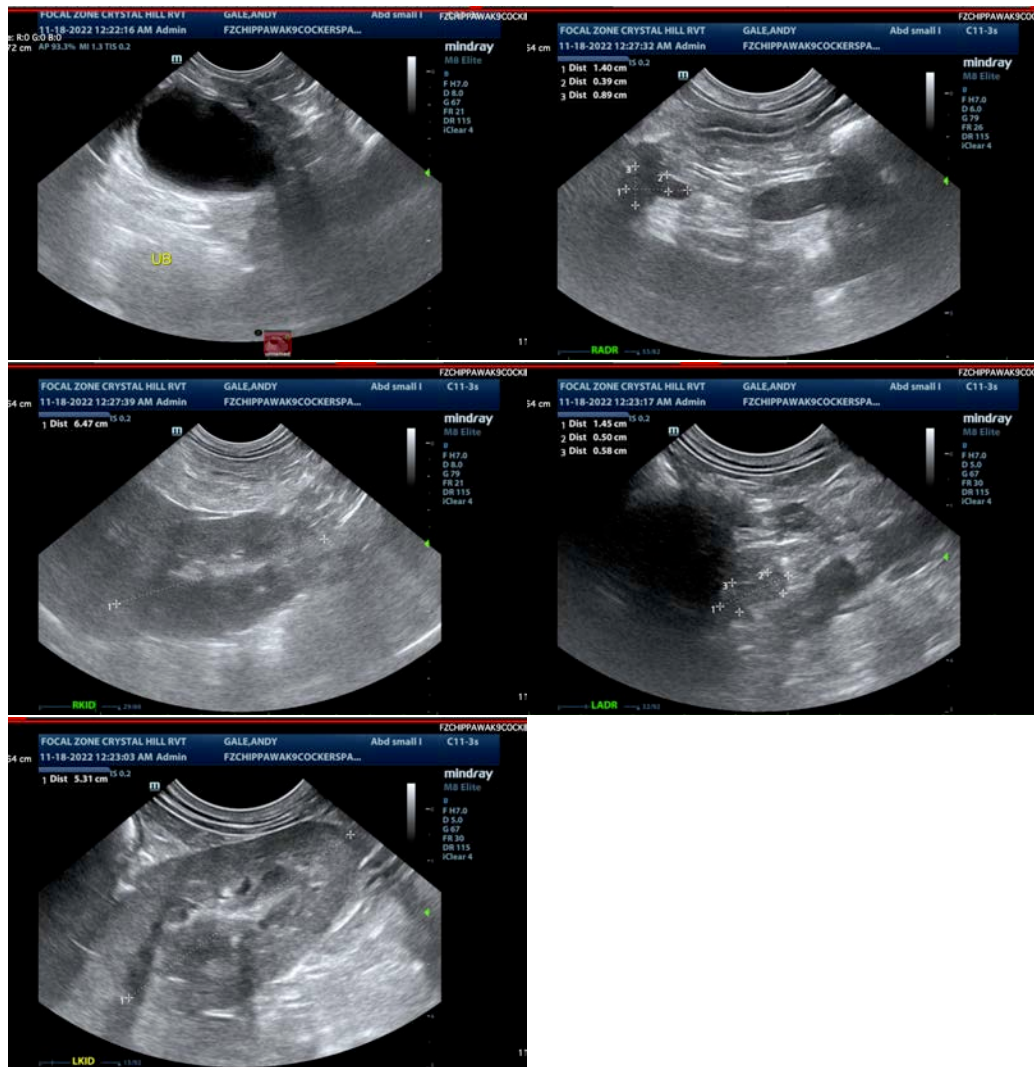
Dr. Dowell

**INVOICE**

42835

**DATE**

11/17/22



The information and recommendations provided are based on the images presented by the referring veterinarian/sonographer. No evaluation can be communicated regarding pathology that was not visible in the image/video clips provided.

Thank you for this referral. If the clinical or image interpretation does not parallel your findings or if I can be of any further assistance please contact me.

Kathleen Sennello DVM,MS, Diplomate ACVIM (Small animal Internal Medicine)

kathleen.sennello@sonopath.com