

IMAGING PERFORMED BY

IntraPet.com



**SonoPath**

Clinical Sonography & Telecytology

EDUCATIONAL TELECONSULTATION SERVICES™

1-800-838-4268 info@sonopath.com SonoPath.com

**DATE PRESENTING CLINICAL SIGNS**

11/15/22

Presented 11/11 with hemorrhagic vaginal discharge - O had noted it had been occurring over a few days and gotten heavier. P not as eager to eat and drink per O. P was spayed around 6 weeks ago and had a mammary mass removed at this time as well. The spay procedure was unremarkable. The mammary mass was sent for histopathology and found to be a benign mixed mammary tumor. Moderate hemorrhagic (red to brown) vaginal discharge with occasional clots appreciated on exam. BCS 4/5. Rest of physical exam largely WNL.

**PATIENT**

Molly Dennis

**SPECIES**

Canine

**BREED**

Golden Retriever

**SEX**

Spayed Female

**AGE**

12/8/13

**WEIGHT**

100 Pounds

**INTERPRETED BY**

Kathleen Sennello DVM,  
MS, Diplomate ACVIM  
(Small Animal Internal  
Medicine)

**IMAGING PERFORMED BY**

Rachel Brillhart RDMS

**HOSPITAL NAME**

Churchville Vet Clinic

**REFERRING VET**

Dr. Kauffman

**INVOICE**

42790

**ULTRASONOGRAPHIC EXAMINATION OF THE ABDOMEN**

**Urinary System**

The urinary bladder is moderately distended with anechoic urine. The Bladder wall, trigone, ureteral papillae and visible urethra (to a depth of 2cm) appear normal with no evidence of wall thickening, mucosal irregularities, masses or cystic calculi.

The left kidney has a normal shape and size (7.4 cm). Overall echogenicity is normal with adequate corticomedullary distinction and a typical 1:3 cortex:medulla ratio. There is no evidence of focal perinephric inflammation or effusion. There is no evidence of pyelectasia, nephroliths, infarcts or hydroureter. Renal vasculature is normal.

The right kidney has a normal shape and size (7.68 cm). Overall echogenicity is normal with adequate corticomedullary distinction and a typical 1:3 cortex:medulla ratio. There is no evidence of focal perinephric inflammation or effusion. There is no evidence of pyelectasia, nephroliths, infarcts or hydroureter. Renal vasculature is normal.

**Adrenal Glands**

The left adrenal gland is normal in size measuring 0.72 cm at the caudal pole. It is observed in its normal position cranial to the left renal artery. It is normal in appearance (uniformly hypoechoic) and shape with no evidence of a mass effect.

The right adrenal gland is normal in size measuring 0.73 cm at the caudal pole. It is observed in its normal position between the cranial aspect of the right kidney and the caudal vena cava. It is normal in appearance (uniformly hypoechoic) and shape with no evidence of a mass effect.

**Spleen**

The spleen is subjectively normal in size, echotexture is homogenous, and the splenic capsule is smooth with no irregularities. The blood flow through the hilus and splenic parenchyma appears normal. No focal parenchymal abnormalities are visualized.

### ***Liver***

The liver is subjectively normal in size, and echogenicity with smooth peripheral margins. The parenchyma is homogenous echotexture. The visible portions of the vasculature and biliary tract appear normal. No focal nodules or cystic lesions are observed.

The gallbladder lumen is moderately distended. The wall of the gall bladder is not thickened and has a smooth mucosal surface. Luminal contents are mild and primarily anechoic. The cystic and common bile ducts are normal/not visible.

### ***Gastrointestinal***

The stomach contains minimal luminal contents. It measures at a normal thickness of <0.7cm with some variability due to the presence of rugal folds. The distinction of the gastric wall layers is adequate and there is no impression of reduced peristaltic activity. No masses or focal lesions were observed.

The visualized areas of duodenum, jejunum and ileum have a relatively uniform diameter with minimal fluid distension. Wall thickness is normal. Bowel loops follow a curvilinear path with distinct wall layering maintaining the typical 1:3 muscularis:mucosa layer ratio. The duodenum measured as normal (between 0.3-0.5cm in wall thickness) and the jejunum measured as normal (between 0.2-0.47cm.) Visualized peristalsis appears appropriate. There were no focal lesions consistent with obstruction or a mass effect observed.

The ileocecal junction was visualized and exhibited normal intact wall layering and is subjectively of normal thickness. Sections of colon are visualized with formed fecal material and gas shadowing distally. There is no observed focal or generalized colon wall thickening or loss of layering.

### ***Pancreas***

The pancreas is normal and isoechoic to surrounding mesentery. There is no evidence of nodules or cystic lesions. There is no evidence of regional mesenteric inflammation or fluid.

### ***Free Abdomen***

There is a scant amount of free abdominal fluid in the caudal abdomen. The caudal abdominal/sublumbar lymph nodes appear prominent and mildly enlarged. A sublumbar lymph node is measured at 1.33 cm x 2.78 cm. The omentum is hyperechoic around the region of the uterine stump and the right ovary.

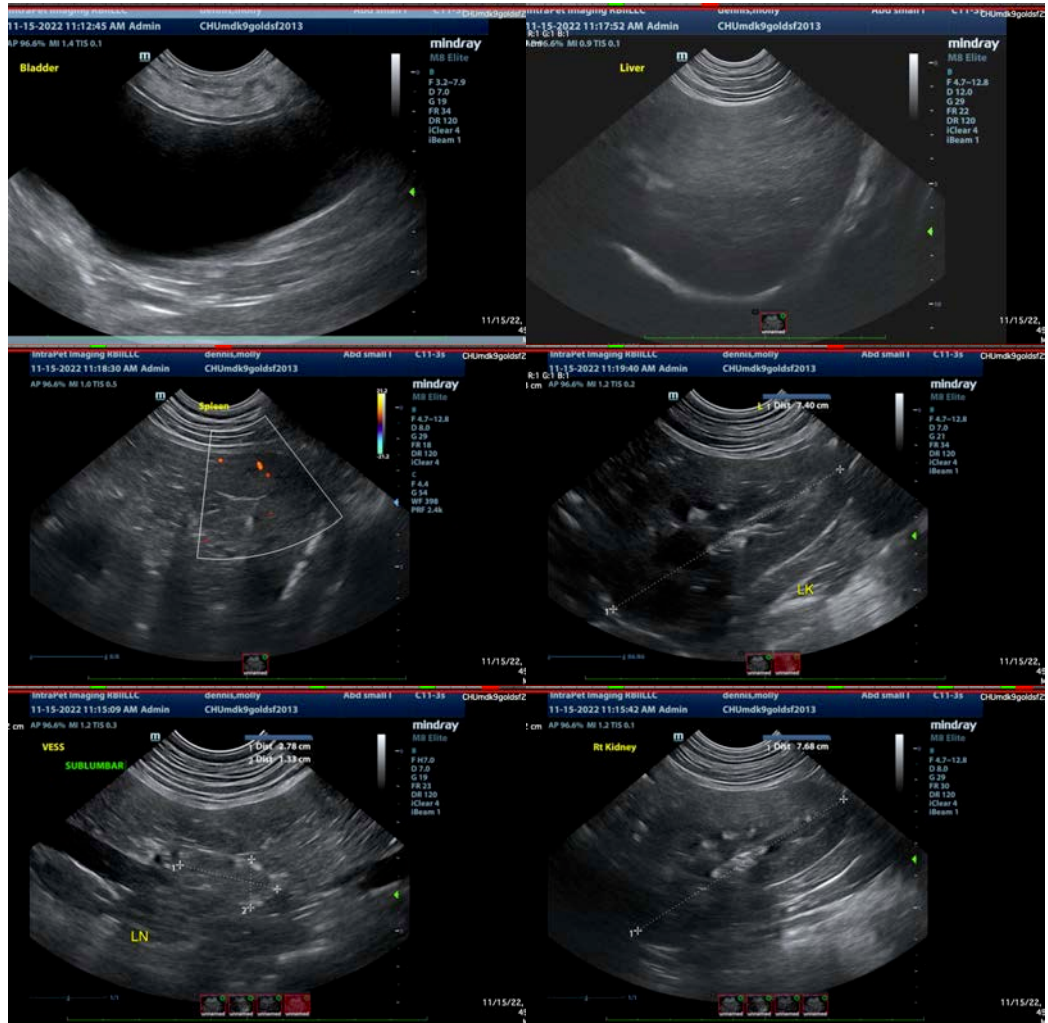
The area of the uterine stump is visualized, revealing a tubular structure dorsal to the urinary bladder that appears irregular, cystic/fluid dilated, with a large amount of surrounding inflammation and localized peritonitis. This area measures approximately 4.28 cm x 3.21 cm and extends cranial to the urinary bladder. This is most consistent with a stump pyometra/metritis. Additionally, there is an area of focal inflammation with nodular tissue in the region of the right ovary measuring 3.24 cm x 1.29 cm, possibly consistent with a retained ovarian +/- suture reaction.

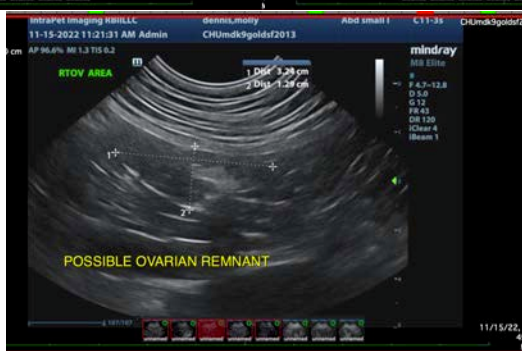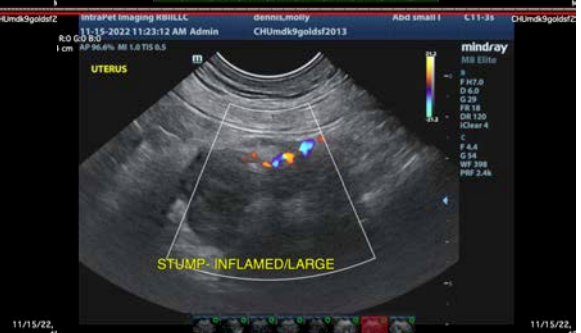
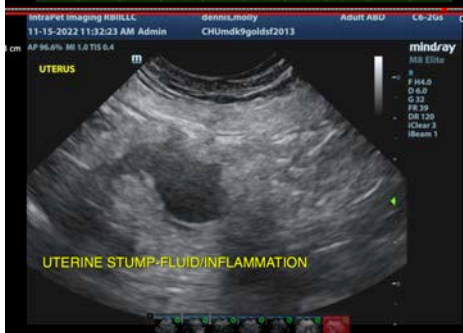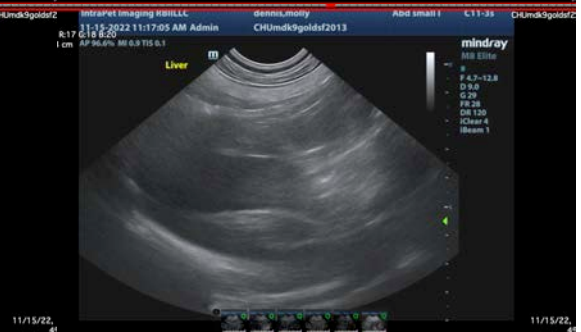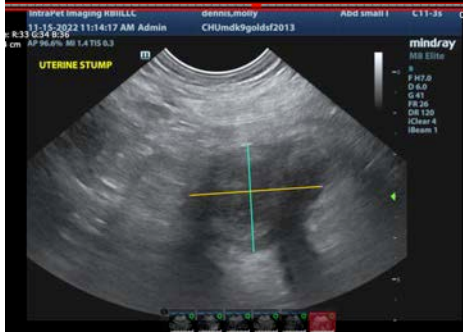
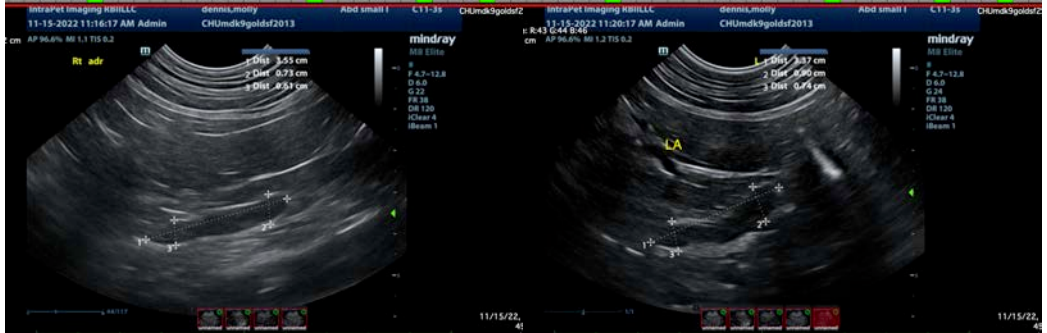
## **ULTRASONOGRAPHIC FINDINGS**

- Large amount of mixed inflammation and a small amount of fluid in the region of the uterine stump – Findings are most consistent with a stump pyometra and focal peritonitis.
- Focal area of mild inflammation in the region of the right ovary – This very likely could represent retained ovarian tissue +/- a small amount of suture reaction in the region of the right ovary.
- Prominent/enlarged sublumbar lymph node – This likely represents a reactive lymph node but continued monitoring is warranted.

## INTERPRETATION OF THE FINDINGS & FURTHER RECOMMENDATIONS

There is a large amount of inflammation in the region of the uterine stump, and there appears to be a tubular structure associated with some cystic tissue/fluid. Findings are concerning for a pyometra and focal peritonitis. Recommend surgical debridement of this area taking the uterine stump back to just before the cervix. There is a pocket of fluid in this area and aerobic and anaerobic cultures of this area should be obtained. Additionally, consider evaluation of the region of both ovaries (particularly the right ) for an ovarian remnant.





**The information and recommendations provided are based on the images presented by the referring veterinarian/sonographer. No evaluation can be communicated regarding pathology that was not visible in the image/video clips provided.**

Thank you for this referral. If the clinical or image interpretation does not parallel your findings or if I can be of any further assistance please contact me.

Kathleen Sennello DVM,MS, Diplomate ACVIM (Small animal Internal Medicine)  
kathleen.sennello@sonopath.com