



DATE PRESENTING CLINICAL SIGNS

11/14/25

Patient History: Evaluation and IV fluid therapy for worsening renal dysfunction with hyporexia and lethargy.

PATIENT

Randall Tucker

History of cardiac wall thickening; monitored by a cardiologist every 6 months. Grade 4/6 heart murmur Azotemia (CREA 9.8, BUN >130), Phosphotemia (>16.1), Hyperproteinemia (TP 9.9, GLOB 7.0), Proteinuria (Hx). Elevated NT-proBNP (>1500).

SPECIES

Feline

Current Medications: Pantoprazole @ 0.7 mg/kg IV once, Unasyn @ 30 mg/kg IV q8h, Enrofloxacin @ 4.89 mg/kg IV q24h, Maropitant @ 1 mg/kg IV q24h, Elura @ 2 mg/kg PO q24h PRN, Ondansetron @ 0.2 mg/kg IV q12h.

BREED

DSH

Labwork Results: TLabwork not attached, reported as: 11/12/25 pDVM Chem: elevated CREA (9.8), PHOS (>16.1), BUN (>130.0), TP (9.9), & GLOB (7.0). CBC: WNL/unremarkable. U/A: Sp Gravity = 1.019, pH = 6.0 PRO = 1+. PCV/TS:- 35%/11. NT-proBNP: >1500 pmol/L (ABNORMAL). Whole Cat Rads: AXR ==> fluid filled, and distended stomach, calcification of both renal pelvi w/irregular shaped right kidney, both kidneys small.

SEX

Neutered Male

TXR ==> WNL/unremarkable.

Date of Previous IntraPet Ultrasound: No previous.

Sedation: Not required to complete full diagnostic ultrasound.

Stat Report: DVM requested.

Imaging Performed by: Andi Parkinson, BS, RDMS.

AGE

11/13/15

ULTRASONOGRAPHIC EXAMINATION OF THE ABDOMEN

WEIGHT

4.5 kg

Urinary System

The urinary bladder is moderately distended with mild primarily suspended echogenic debris present. The Bladder wall, trigone, ureteral papillae and visible urethra (to a depth of 2cm) appear normal with no evidence of wall thickening, mucosal irregularities, masses or calculi. Echogenic debris of this type can be associated with small crystals, cellular debris and proteinaceous debris.

INTERPRETED BY

Kathleen Sennello DVM,
MS, Diplomate ACVIM
(Small Animal Internal
Medicine)

The left kidney is small (2.9 cm). The cortex is hyperechoic with severely decreased corticomedullary distinction and a typical 1:3 cortex:medulla ratio. Medullary mineralizations are noted. There is no evidence of focal perinephric inflammation or effusion. There is no evidence of pyelectasia, infarcts or hydroureter. Renal vasculature is normal.

HOSPITAL NAME

Mason Dixon Animal
Emergency Hospital

The right kidney is borderline small (3.7 cm). The cortex is hyperechoic with severely decreased corticomedullary distinction and a typical 1:3 cortex:medulla ratio. A small cortical cyst is noted measuring 0.36 cm. Occasional cortical mineralizations noted. There is no evidence of focal perinephric inflammation or effusion. There is no evidence of pyelectasia, infarcts or hydroureter. Renal vasculature is normal.

REFERRING VET

Dr. Petro

Adrenal Glands

The left adrenal gland is normal in size measuring 0.59 cm at the caudal pole. It is observed in its normal position cranial to the left renal artery. It is normal in appearance (uniformly hypoechoic) and shape with no evidence of a mass effect.

INVOICE

71786

The region of the right adrenal (between right cranial kidney and vena cava) is unremarkable, but the adrenal is not distinctly visualized. No evidence of a mass effect is visualized.

Spleen

The spleen is subjectively normal in size (0.74 cm), echotexture is homogenous, and the splenic capsule is smooth with no irregularities. The blood flow through the hilus and splenic parenchyma appears normal. No focal parenchymal abnormalities are visualized.

Liver

The liver is subjectively normal in size, and echogenicity with smooth peripheral margins. The parenchyma is homogenous echotexture. The visible portions of the vasculature and biliary tract appear normal. No focal nodules or cystic lesions are observed.

The gall bladder lumen is moderately distended. The wall of the gall bladder is not thickened and has a smooth mucosal surface. There is a moderate amount of non-organized echogenic debris. Some of the debris appears irregular and mildly mineralized. The cystic and common bile ducts are normal/not visible.

Gastrointestinal

The stomach contains a moderate amount of fluid and a large amount of gas. It measures at a normal thickness of <0.36cm with some variability due to the presence of rugal folds. The distinction of the gastric wall layers is adequate and there is no impression of reduced peristaltic activity. No masses or focal lesions were observed.

The visualized areas of duodenum, jejunum and ileum have a relatively uniform diameter with minimal to mild fluid/gas. Wall thickness is normal. Bowel loops follow a curvilinear path with distinct wall layering maintaining the typical 1:3 muscularis:mucosa layer ratio. Jejunum wall measures 0.31 cm. Visualized peristalsis appears appropriate. There were no focal lesions consistent with obstruction or a mass effect observed.

The ileocecal junction was visualized and exhibited normal intact wall layering and is subjectively of normal thickness. Sections of colon are visualized with non-formed fecal material and gas shadowing distally. There is no observed focal or generalized colon wall thickening or loss of layering.

Pancreas

The pancreas is normal and isoechoic to surrounding mesentery. There is no evidence of nodules or cystic lesions. There is no evidence of regional mesenteric inflammation or fluid.

Free Abdomen

Evaluation of the peritoneal cavity did not reveal any evidence of effusion, or subjective lymphadenomegaly. The Medial iliac nodes appear normal and there was no evidence of a caudal aortic thrombus at the bifurcation. The omentum is of normal uniform echogenicity.

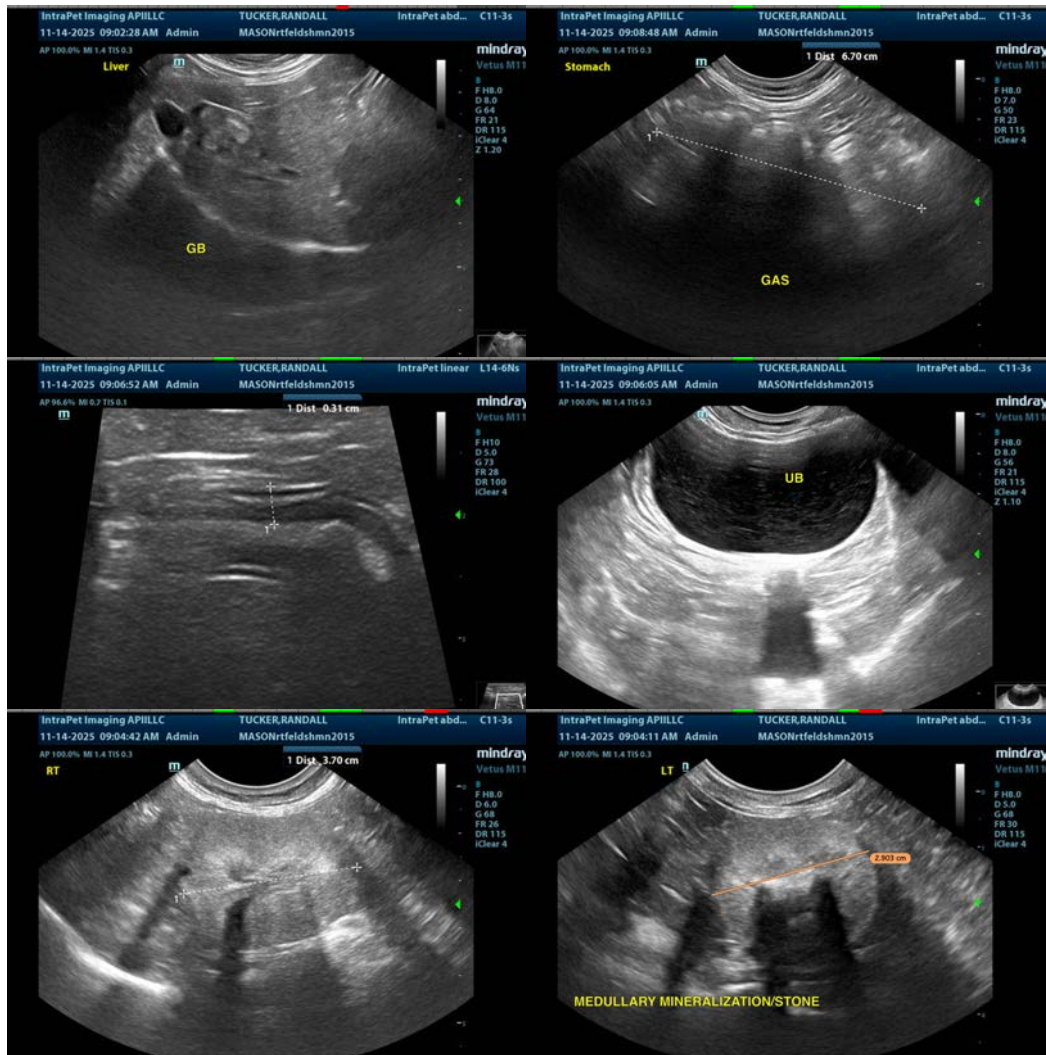
ULTRASONOGRAPHIC FINDINGS

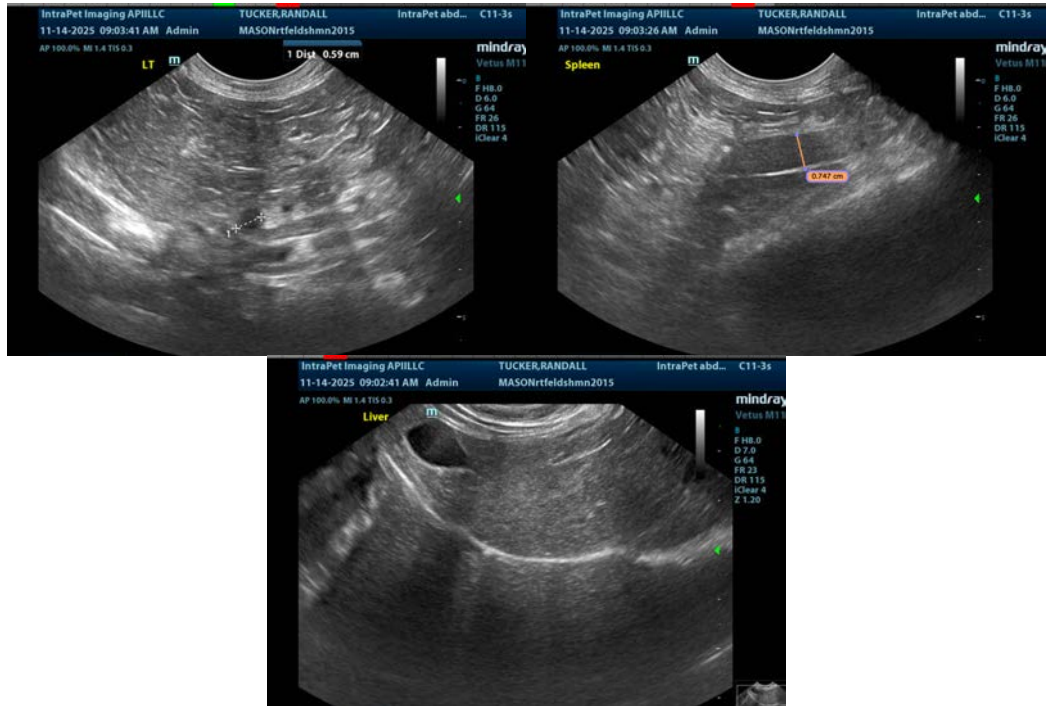
- Mild suspended echogenic debris in the urinary bladder – The echogenic debris in the bladder lumen could be consistent with cells, crystals, and/or mucus.
- Hyperechoic, borderline small kidneys with severely reduced corticomedullary distinction and mineralizations/small stones – Findings are most consistent with chronic renal disease.

- Moderate gallbladder debris with some mineralized debris – The significance of the aggregated gallbladder debris is unclear. This could represent an early mucocele, cholestasis, or may be secondary to fasting. Incidental gall bladder debris is less common in cats.
- Significantly fluid and gas distended stomach – Findings are suggestive of gastric ileus. an obstructive process is not clearly visualized.

INTERPRETATION OF THE FINDINGS & FURTHER RECOMMENDATIONS

Both kidneys appear abnormal with severely reduced corticomedullary distinction. They are hyperechoic and borderline small with some mineralizations but no evidence of an obstruction at this time. The appearance is most consistent with advanced chronic renal disease. An obvious cause for the elevation in globulin is not visualized. If not already done, a urine culture and blood pressure are recommended. Protein electrophoresis could be considered to further evaluate the elevation in globulin reported.





The information and recommendations provided are based on the images presented by the referring veterinarian/sonographer. No evaluation can be communicated regarding pathology that was not visible in the image/video clips provided.

Thank you for this referral. If the clinical or image interpretation does not parallel your findings or if I can be of any further assistance please contact me.

Kathleen Sennello DVM,MS, Diplomate ACVIM (Small animal Internal Medicine)
info@sonopath.com