


DATE PRESENTING CLINICAL SIGNS

11/14/25

Patient History: Juliette presented for a few days of decreased appetite as well as a seizure. She had low blood sugar as well as low blood pressure on presentation. She was given an IV fluid bolus as well as an injection of dextrose and then started on dopamine for her low blood pressure. She has a history of being diagnosed with atypical Addison's disease 4/2023 but has not been on any prednisone except for once a month the past 3 months b/c she has been on carprofen for OA. She also received librela 2 weeks ago. She has required dopamine and dextrose while receiving IVF and IV dexamethasone. POCUS showed an enlarged liver and spleen with scant free fluid by the liver; the architecture of the liver appears abnormal.

PATIENT

Juliette Gilbert

SPECIES

Canine

BREED

Chihuahua

SEX

Spayed Female

AGE

4/7/15

WEIGHT

4.39 kg

INTERPRETED BY

 Kathleen Sennello DVM,
 MS, Diplomate ACVIM
 (Small Animal Internal
 Medicine)

HOSPITAL NAME

 Mason Dixon Animal
 Emergency Hospital

REFERRING VET

Dr. Longbottom

INVOICE

71788

Current Medications: IH Maropitant Citrate 10 mg/mL Injectable | 0.96mg/kg, 4.2mg | IV | q24h | (IV use: Give over 1-2 minutes) | last dose 11/13/2025, 3:40A, OM Sucralfate Malate 500 mg/mL Oral Suspension (Compounded) | 56.9mg/kg, 250mg | PO | q12h | last dose 11/13/2025, 8:28P, IH Dexamethasone Sodium Phosphate 4 mg/mL Injectable | 0.1mg/kg, 0.44mg | IV | q12h | ask | last dose 11/13/2025, 3:43P
DISCONTINUED/COMPLETED: IH Dextrose 50 % Injectable: 500mL | 114mg/kg, 500mg | IV | Once | -For IV bolus: Dilute 1:2 with 0.9% NaCl and give over 5 minutes | last dose 11/13/2025, 2:17A, IH Pantoprazole Sodium 4 mg/mL Powder for Injection | 0.91mg/kg, 4mg | IV | Once | (IV use: Give slowly over 10-15 minutes) | last dose 11/13/2025, 3:00A., IH Dexamethasone Sodium Phosphate 4 mg/mL Injectable | 0.19mg/kg, 0.84mg | IV | Once | last dose 11/13/2025, 3:00A, IH Dextrose 50 % Injectable: 500mL | 513mg/kg, 2250mg | OTHER | Once | -For IV bolus: Dilute 1:2 with 0.9% NaCl and give over 5 minutes | last dose 11/13/2025, 6:22P
 IH Dopamine Hydrochloride 40 mg/mL Injectable | 2.73mg/kg, 12mg | OTHER | Once | last dose 11/13/2025, 5:11P.

Labwork Results: Labwork attached, reported as: note original ALB of 1.6 was an error - attached ALB of 3.6 is correct value.

Date of Previous IntraPet Ultrasound: No previous.

Sedation: Not required to complete full diagnostic ultrasound.

Stat Report: DVM requested.

Imaging Performed by: Andi Parkinson, BS, RDMS.

ULTRASONOGRAPHIC EXAMINATION OF THE ABDOMEN
Urinary System

The urinary bladder is moderately distended with anechoic urine. The Bladder wall, trigone, ureteral papillae and visible urethra (to a depth of 2cm) appear normal with no evidence of wall thickening, mucosal irregularities, masses or cystic calculi.

The left kidney has a normal shape and size (3.62 cm). Overall echogenicity is normal with adequate corticomedullary distinction and a typical 1:3 cortex:medulla ratio. There is no evidence of focal perinephric inflammation or effusion. There is no evidence of pyelectasia, nephroliths, infarcts or hydroureter. Renal vasculature is normal.

The right kidney has a normal shape and size (3.95 cm). Overall echogenicity is normal with adequate corticomedullary distinction and a typical 1:3 cortex:medulla ratio. There is no evidence of focal perinephric inflammation or effusion. There is no evidence of pyelectasia, nephroliths, infarcts or hydroureter. Renal vasculature is normal.

Adrenal Glands

The left adrenal gland is small and difficult to visualize, measuring 0.18 cm.

The right adrenal gland is small, measuring 0.26 cm. It is observed in its normal position between the cranial aspect of the right kidney and the caudal vena cava. It is normal in appearance (uniformly hypoechoic) and shape with no evidence of a mass effect.

Spleen

The spleen is subjectively normal in size (1.2 cm), echotexture is homogenous, and the splenic capsule is smooth with no irregularities. The blood flow through the hilus and splenic parenchyma appears normal. No focal parenchymal abnormalities are visualized.

Liver

The liver is large in size and irregular. The parenchyma is heterogenous in echotexture with subtle, indistinct focal mottling. The visible portions of the vasculature and biliary tract appear normal. There are some ill-defined hyper- and hypoechoic nodules visualized in the parenchyma. Additionally on some views (particularly the transverse view) there is a mid left-sided mass effect measuring 3.26 cm x 4.61 cm, most consistent with a rounded liver lobe, although a poorly defined mass effect cannot be ruled out.

The gall bladder appears contracted and small with some intraluminal mineralized material. The cystic and common bile ducts are normal/not visible.

Gastrointestinal

The stomach contains moderate shadowing ingesta and fluid. It measures at a normal thickness of <0.7cm with some variability due to the presence of rugal folds. The distinction of the gastric wall layers is adequate and there is no impression of reduced peristaltic activity. No masses or focal lesions were observed.

The visualized areas of duodenum, jejunum and ileum have a relatively uniform diameter with minimal fluid distension. Wall thickness is normal. Bowel loops follow a curvilinear path with distinct wall layering maintaining the typical 1:3 muscularis:mucosa layer ratio. Duodenum wall measures 0.26 cm. Jejunum wall measures 0.20 cm. Visualized peristalsis appears appropriate. There were no focal lesions consistent with obstruction or a mass effect observed.

Sections of colon are visualized with formed fecal material and gas shadowing distally. There is no observed focal or generalized colon wall thickening or loss of layering.

Pancreas

The pancreas is large and hypoechoic to surrounding mesentery. There is no evidence of nodules or cystic lesions. There is evidence of regional mesenteric inflammation. Consistent with moderate pancreatitis.

Free Abdomen

There is a moderate amount of free abdominal fluid. No lymphadenopathy. The omentum is diffusely hyperechoic, particularly around the pancreas.

ULTRASONOGRAPHIC FINDINGS

- Bilaterally small adrenal glands – Findings are consistent with the current diagnosis of hypoadrenocorticism.
- Large, prominent, hypoechoic pancreas with surrounding reactive mesentery – Findings are most consistent with mild/moderate pancreatitis.

- Large, irregular, heterogeneous liver with ill-defined nodules and a rounded liver lobe/mass effect – Findings are most consistent with a vacuolar hepatopathy, although other hepatopathies are possible. The nodules generally have the appearance most consistent with regenerative nodules. The rounded area of liver could represent a rounded liver lobe or very poorly defined adenoma, carcinoma, other.
- Small, contracted gallbladder with intraluminal mineralization/stones.
- Moderate volume free abdominal fluid – Recommend fluid analysis and cytology.

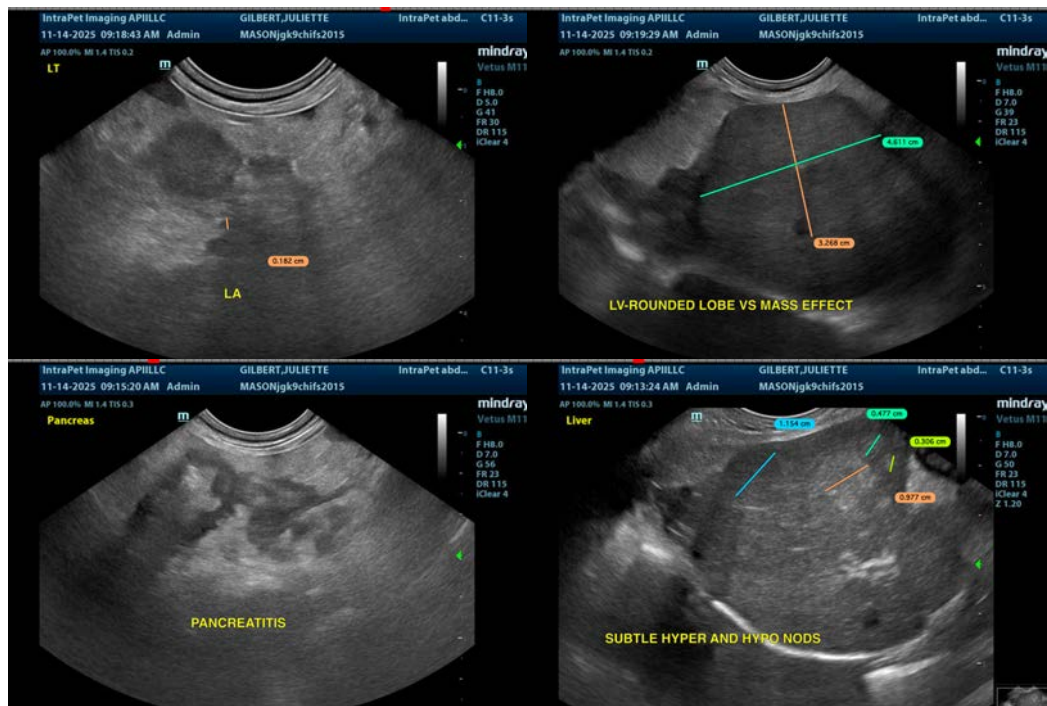
INTERPRETATION OF THE FINDINGS & FURTHER RECOMMENDATIONS

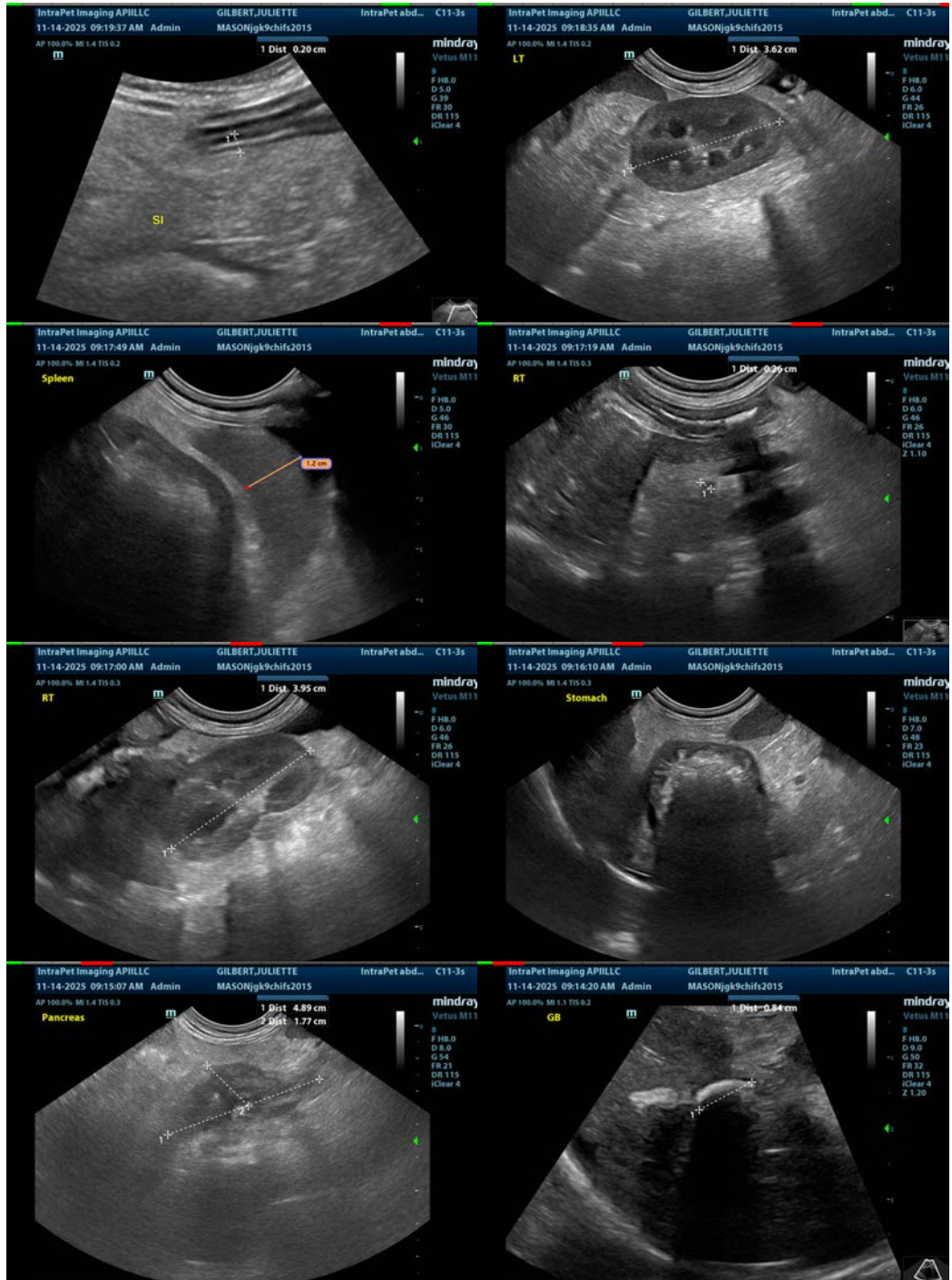
The pancreas is large and hypoechoic with surrounding reactive mesentery, most consistent with significant pancreatitis. Recommend aggressive therapy for pancreatitis.

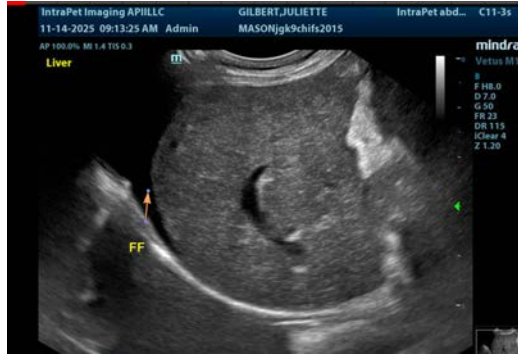A definitive source for the free fluid is not evident. It could be secondary to the pancreatitis. Recommend fluid analysis and cytology to further evaluate.

The liver is large, irregular, somewhat nodular and heterogeneous. On some views there is a poorly defined “bulge” in the liver lobe, which could be consistent with a poorly defined mass effect. Consider a fine needle aspirate of the liver and possibly a liver function test to rule out hepatic dysfunction as a cause for the hypoglycemia or free fluid present.

Recommend three view thoracic radiographs to evaluate for possible concurrent thoracic disease/involvement (disregard if this has already been done).







The information and recommendations provided are based on the images presented by the referring veterinarian/sonographer. No evaluation can be communicated regarding pathology that was not visible in the image/video clips provided.

Thank you for this referral. If the clinical or image interpretation does not parallel your findings or if I can be of any further assistance please contact me.

Kathleen Sennello DVM,MS, Diplomate ACVIM (Small animal Internal Medicine)
info@sonopath.com