

**DATE PRESENTING CLINICAL SIGNS**

11/14/25

Patient History: Recent urinary signs - straining, dribbling urine - BW unremarkable, UA - bacteria and WBC's -

PATIENT

Finley Maffett

Current Medications: Clavamox 250mg 7 days (refilled and continue 7 more today)

Labwork Results: Labwork not attached, reported as: CBC chem WNL, UA bacteria, increase WBC and rbc's

Date of Previous IntraPet Ultrasound: No previous.

Sedation: Declined.

Stat Report: STAT requested.

Imaging Performed by: Rachel Brillhart, RDMS.

SPECIES

Canine

BREED

Terrier x

SEX

Spayed Female

AGE

7/10/14

WEIGHT

43.1 lbs

INTERPRETED BY

Kathleen Sennello DVM,
MS, Diplomate ACVIM
(Small Animal Internal
Medicine)

HOSPITAL NAME

Hickory Veterinary
Hospital

REFERRING VET

Dr. Snyder

INVOICE

71790

ULTRASONOGRAPHIC EXAMINATION OF THE ABDOMEN**Urinary System**

The urinary bladder is moderately distended with anechoic urine. The Bladder wall appears of normal thickness with a smooth mucosal surface. In the dependent portion of the urinary bladder there are small mineralizations/stones, an example of which measures at 0.23 cm. The region of the trigone appears normal with no mass lesions observed. The urethra appears to progressively thicken, becoming severely thickened with a hypoechoic, irregular wall and intraluminal mineralization. The urethra measures 1.54 cm in thickness with wall thickness of 0.68 cm.

The left kidney has a normal shape and size (5.95 cm). Overall echogenicity is normal with adequate corticomedullary distinction and a typical 1:3 cortex:medulla ratio. There is no evidence of focal perinephric inflammation or effusion. There is no evidence of pyelectasia, nephroliths, infarcts or hydroureter. Renal vasculature is normal.

The right kidney is large (7.45 cm). There is hydronephrosis present with the renal pelvis measuring 1.32 cm in diameter. Additionally, there is significant hydroureter with the proximal ureter measuring 1.09 cm in diameter. This can be followed down to the level of the urinary bladder with inflammation surrounding the ureter. Distally the ureter appears to taper, measuring at 0.38 cm. In the area where it is lost to follow there is the suggestion of an isoechoic mass effect, concerning for possible neoplastic infiltration or irregular debris.

Adrenal Glands

The left adrenal gland is normal in size measuring 0.76 cm at the cranial pole and 0.81 cm at the caudal pole. It is observed in its normal position cranial to the left renal artery. It is normal in appearance (uniformly hypoechoic) and shape with no evidence of a mass effect.

The right adrenal gland is normal in size measuring 0.44 cm at the cranial pole and 0.55 cm at the caudal pole. It is observed in its normal position between the cranial aspect of the right kidney and the caudal vena cava. It is normal in appearance (uniformly hypoechoic) and shape with no evidence of a mass effect.

Spleen

The spleen is subjectively normal in size (2.33 cm), echotexture is homogenous, and the splenic capsule is smooth with no irregularities. The blood flow through the hilus and splenic parenchyma appears normal. No focal parenchymal abnormalities are visualized.

Liver

The liver is subjectively normal in size, and echogenicity with smooth peripheral margins. The parenchyma is homogenous echotexture. The visible portions of the vasculature and biliary tract appear normal. No focal nodules or cystic lesions are observed.

The gall bladder lumen is moderately distended. The wall of the gall bladder is not thickened and has a smooth mucosal surface. Luminal contents are mild and likely incidental at this time. The cystic and common bile ducts are normal/not visible.

Gastrointestinal

The stomach contains minimal luminal contents. It measures at a normal thickness of <0.7cm with some variability due to the presence of rugal folds. The distinction of the gastric wall layers is adequate and there is no impression of reduced peristaltic activity. No masses or focal lesions were observed.

The visualized areas of duodenum, jejunum and ileum have a relatively uniform diameter with minimal fluid distension. Wall thickness is normal. Bowel loops follow a curvilinear path with distinct wall layering maintaining the typical 1:3 muscularis:mucosa layer ratio. The duodenum measured as normal (between 0.3-0.5cm in wall thickness) and the jejunum measured as normal (between 0.2-0.47cm.) Visualized peristalsis appears appropriate. There were no focal lesions consistent with obstruction or a mass effect observed.

Sections of colon are visualized with formed fecal material and gas shadowing distally. There is no observed focal or generalized colon wall thickening or loss of layering.

Pancreas

The area of the pancreas is normal and isoechoic to surrounding mesentery. There is no evidence of nodules or cystic lesions. There is no evidence of regional mesenteric inflammation or fluid.

Free Abdomen

There is scant free fluid noted. There is a mild sublumbar lymphadenopathy. The omentum is hyperechoic and mottled around the right ureter and the urethra.

ULTRASONOGRAPHIC FINDINGS

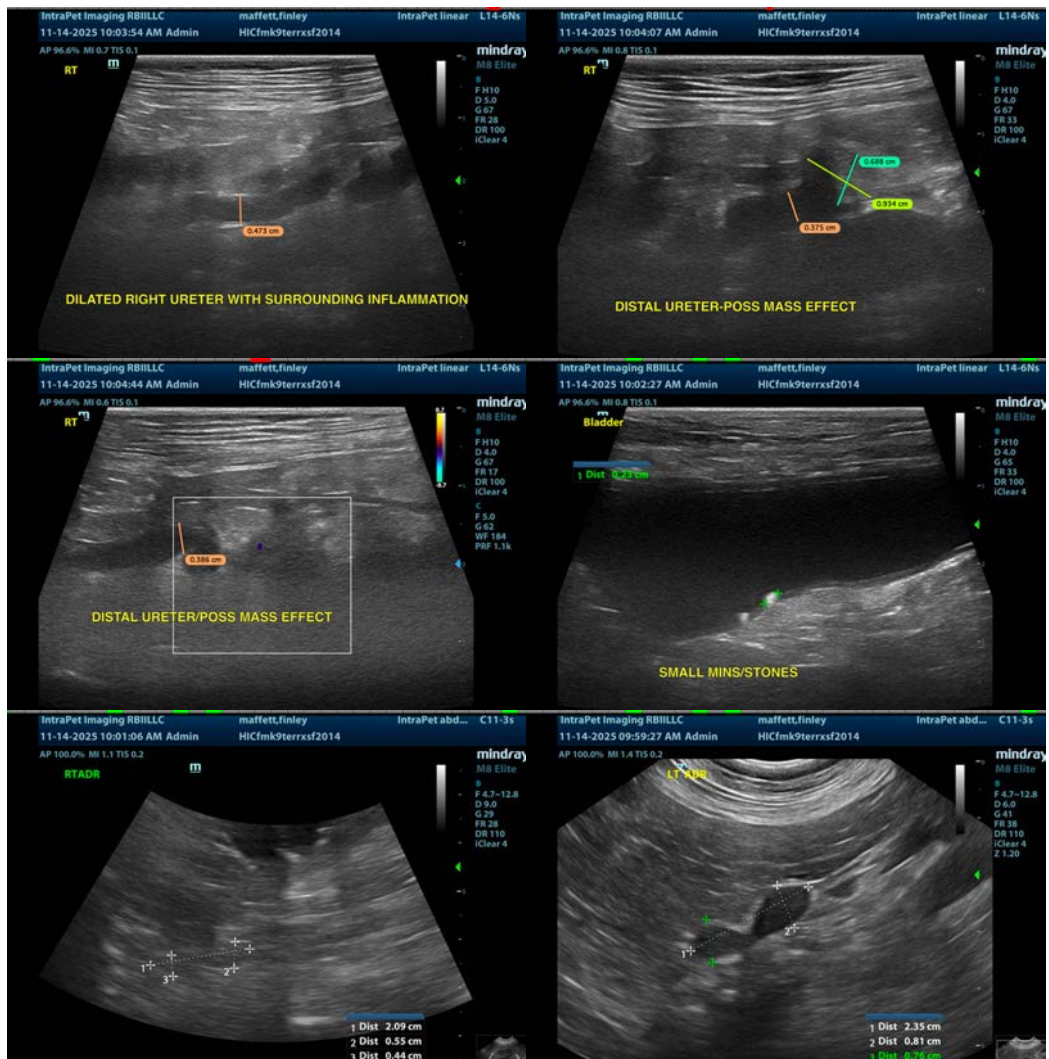
- Small dependent mineralizations visualized within the urinary bladder – Findings are most consistent with small calculi.
- Severely thickened hypoechoic urethral wall with mineralization – Findings are concerning for neoplastic infiltration at the level of the urethra. Severe granulomatous urethritis or similar cannot be definitively ruled out.
- Right-sided hydronephrosis and hydroureter – A distal ureteral obstruction is suspected, possibly secondary to a mass effect or intraluminal debris.

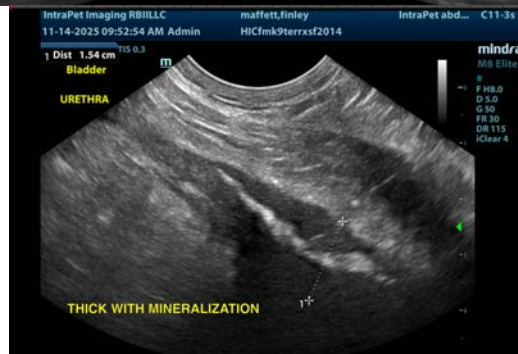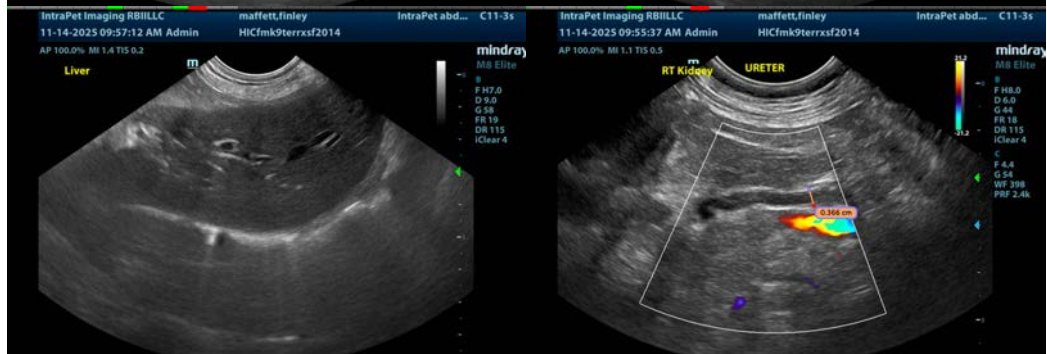
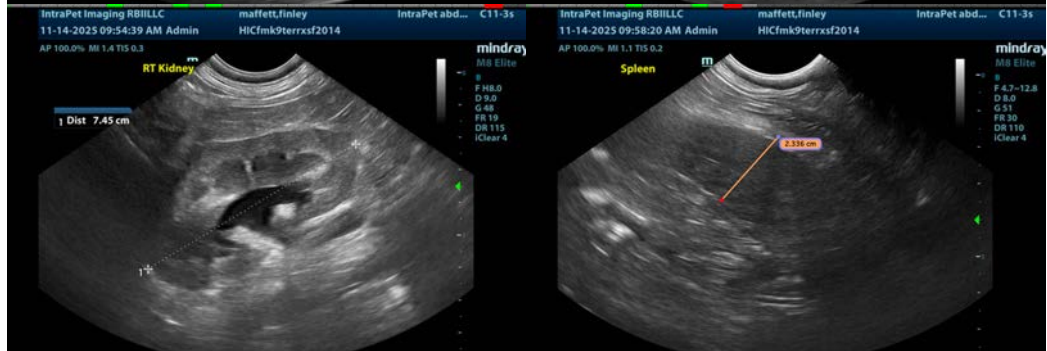
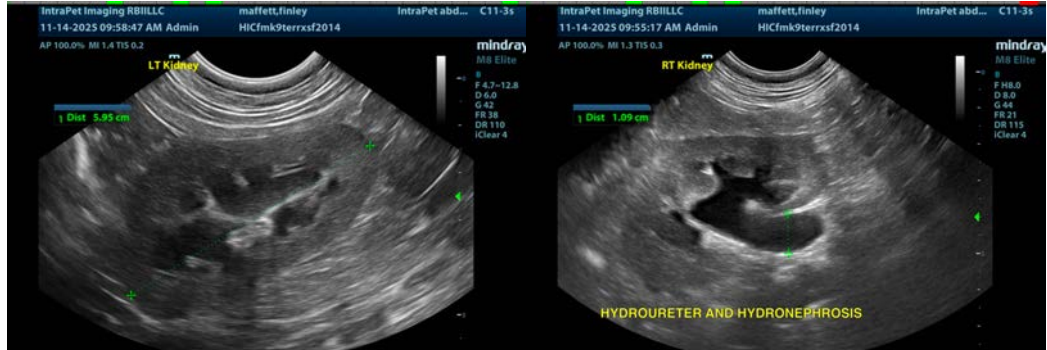
INTERPRETATION OF THE FINDINGS & FURTHER RECOMMENDATIONS

There are very small mineralizations visualized in the urinary bladder, but no definitive mass lesion within the urinary bladder. The urethra, however, appears severely thickened with a hypoechoic wall and some mineralization. This appearance is concerning for possible neoplastic infiltration of the urethra, although other differentials such as severe urethritis, granulomatous urethritis, etc. are possible though much less common.

Additionally, there is hydronephrosis and hydroureter involving the right kidney. There is the suspicion of neoplastic infiltration interfering at the level of the distal ureter, although debris or similar could also be a factor. Recommend evaluation of a free catch urine sample. If this is a cellular sample, recommend sending out for cytologic evaluation. If a diagnosis cannot be obtained this way, consider a catheterization (traumatic catheterization) where a sample is obtained from the distal urethra. Once a definitive diagnosis can be obtained, recommend consultation with a veterinary oncologist. I'm concerned that options may be limited, as bypassing the urethra is difficult. A contrast study or contrast CT scan could be considered to further evaluate the likely distal ureteral obstruction. While awaiting test results, you could consider starting Piroxicam and Misoprostol provided the patient is well hydrated and renal function is good.

Recommend three view thoracic radiographs to evaluate for possible concurrent thoracic disease/involvement (disregard if this has already been done).





The information and recommendations provided are based on the images presented by the referring veterinarian/sonographer. No evaluation can be communicated regarding pathology that was not visible in the image/video clips provided.

Thank you for this referral. If the clinical or image interpretation does not parallel your findings or if I can be of any further assistance please contact me.

Kathleen Sennello DVM,MS, Diplomate ACVIM (Small animal Internal Medicine)
info@sonopath.com