PATIENT

Louie Stathakis

SPECIES

Canine

BREED

Boston Terrier

SEX

MN

AGE

11 years

WEIGHT

23.3 lbs

INTERPRETED BY

Kathleen Sennello DVM, MS, Diplomate ACVIM (Small Animal Internal Medicine)

IMAGING PERFORMED BY

Pamela Harrigan, RDCS, Certified Veterinary Sonographer

HOSPITAL NAME

Norfolk County Veterinary Service

REFERRING VET

Dr. Amelia Ragon

INVOICE

10753

DATE

11/13/2025

PRESENTING CLINICAL SIGNS

Presented with 2-week history PU/PD, polyphagia, and weight loss. Also has paraparesis. Lepto vaccinated. Recent CBC/Chem/UA NSF. USG 1.024, inactive sediment, urine cultures negative.

ULTRASONOGRAPHIC EXAMINATION OF THE ABDOMEN

Urinary System

The urinary bladder is moderately distended with anechoic urine. The Bladder wall, trigone, ureteral papillae and visible urethra (to a depth of 2cm) appear normal with no evidence of wall thickening, mucosal irregularities, masses or cystic calculi.

The prostate is normal in size (0.73 cm) and shape for this neutered male dog. The parenchyma is homogenous and the external margins are smooth. The prostatic urethra appears normal with no evidence of irregularity, invasion, mass effect or calculi.

The left kidney has a normal shape and size (4.68 cm). Overall echogenicity is normal with adequate corticomedullary distinction and a typical 1:3 cortex:medulla ratio. There is no evidence of focal perinephric inflammation or effusion. There is no evidence of pyelectasia, nephroliths, infarcts or hydroureter. Renal vasculature is normal.

The right kidney has a normal shape and size (4.76 cm). Overall echogenicity is normal with adequate corticomedullary distinction and a typical 1:3 cortex:medulla ratio. There is no evidence of focal perinephric inflammation or effusion. There is no evidence of pyelectasia, nephroliths, infarcts or hydroureter. Renal vasculature is normal.

Adrenal Glands

The left adrenal gland is plump in size measuring 0.64 cm at the cranial pole and 0.7 cm at the caudal pole. It is observed in its normal position cranial to the left renal artery. It is normal in appearance (uniformly hypoechoic) and shape with no evidence of a mass effect.

The right adrenal gland is borderline plump in size, and irregular in shape, measuring 0.58 cm at the cranial pole and 0.74 cm at the caudal pole. It is observed in its normal position between the cranial aspect of the right kidney and the caudal vena cava. It is normal in appearance (uniformly hypoechoic) and shape with no evidence of a mass effect.

Spleen

The spleen is subjectively normal in size (1.29 cm) and the echotexture is homogenous. The splenic capsule is smooth with no visible irregularities. The blood flow through the hilus and splenic parenchyma appears normal.

Liver

The liver is subjectively normal in size, and echogenicity with smooth peripheral margins. The parenchyma is homogenous echotexture. The visible portions of the vasculature and biliary tract appear normal. No focal nodules or cystic lesions are observed.

The gall bladder lumen is moderately distended. The wall of the gall bladder is not thickened and has a smooth mucosal surface. Luminal contents are mild and likely incidental at this time. The cystic and common bile ducts are normal/not visible.

PATIENT
Louie Stathakis

SPECIES
Canine

BREED
Boston Terrier

SEX
MN

AGE
11 years

WEIGHT
23.3 lbs

INTERPRETED BY
Kathleen Sennello DVM, MS, Diplomate ACVIM (Small Animal Internal Medicine)

IMAGING PERFORMED BY
Pamela Harrigan, RDCS, Certified Veterinary Sonographer

HOSPITAL NAME
Norfolk County Veterinary Service

REFERRING VET
Dr. Amelia Ragon

INVOICE
10753

DATE
11/13/2025

Gastrointestinal

The stomach is moderately dilated with fluid and irregular shadowing material most consistent with normal ingesta and gas. It measures at a normal thickness of <0.7cm with some variability due to the presence of rugal folds. The distinction of the gastric wall layering is adequate and there is no impression of reduced peristaltic activity. There's focal large shadowing material visualized within the gastric lumen. Correlate with the feeding history and radiographs. The shadowing material will full evaluation of the stomach and some areas of the cranial abdomen.

The visualized areas of duodenum (0.61 cm), jejunum (0.32 cm) and ileum have a uniform diameter with minimal fluid distension. There's mild mucosal fogging and speckling visualized associated with the duodenum. Wall appears subjectively, mildly increased. Bowel loops follow a typical curvilinear path with distinct wall layering. Visualized peristalsis appears appropriate. There were no focal lesions consistent with obstruction or a mass effect observed

The ileocecal junction was visualized and exhibited normal intact wall layering and is subjectively of normal thickness. Sections of colon are visualized with formed fecal material and gas shadowing distally. There is no observed focal or generalized colon wall thickening or loss of layering.

Pancreas

The area of the pancreas is normal and isoechoic to surrounding mesentery. There is no evidence of nodules or cystic lesions. There is no evidence of regional mesenteric inflammation or fluid.

Free Abdomen

Evaluation of the peritoneal cavity did not reveal any evidence of effusion, or subjective lymphadenomegaly. The Medial iliac nodes appear normal and there was no evidence of a caudal aortic thrombus at the bifurcation. The omentum is of normal uniform echogenicity.

ULTRASONOGRAPHIC FINDINGS

- Borderline plump adrenals. Findings could be consistent with anatomic variation, or mild early hyperplasia.
- Large shadowing ingesta visualized within the gastric lumen. Correlate with the feeding history. If the patient was adequately fasted, consider the possibility of ingested foreign material or delayed gastric emptying. No evidence of an obstruction is noted.
- Thick duodenum with mild mucosal fogging and speckling. Bright mucosal speckling has been postulated to represent dilated lacteals or focal accumulations of mucus, cellular debris, etc.. in the mucosal crypts.

INTERPRETATION OF THE FINDINGS & FURTHER RECOMMENDATIONS

Both adrenals appear somewhat plump. The right adrenal is irregularly shaped. If symptoms consistent with Cushing's disease are present, you could consider adrenal function testing.

There's focal shadowing material visualized within the gastric lumen. If the patient was adequately fasted, consider the possibility of delayed gastric emptying or ingested foreign material.

The duodenum appears somewhat thickened with mild mucosal fogging and speckling. The significance of this is uncertain in the absence of underlying gastrointestinal symptoms. If underlying

PATIENT

Louie Stathakis

SPECIES

Canine

BREED

Boston Terrier

SEX

MN

AGE

11 years

WEIGHT

23.3 lbs

INTERPRETED BY

Kathleen Sennello DVM, MS, Diplomate ACVIM (Small Animal Internal Medicine)

IMAGING PERFORMED BY

Pamela Harrigan, RDCS, Certified Veterinary Sonographer

HOSPITAL NAME

Norfolk County Veterinary Service

REFERRING VET

Dr. Amelia Ragon

INVOICE

10753

DATE

11/13/2025

gastrointestinal disease is suspected you could consider a GI Panel to Texas A&M for a qualitative PLI/TLI, cobalamin, and folate for initial evaluation. If the paraparesis has been acute and onset, consider consultation with veterinary neurologist considering evaluation for a possible central lesion.

Consider three view thoracic radiographs to rule out concurrent thoracic disease/involvement.

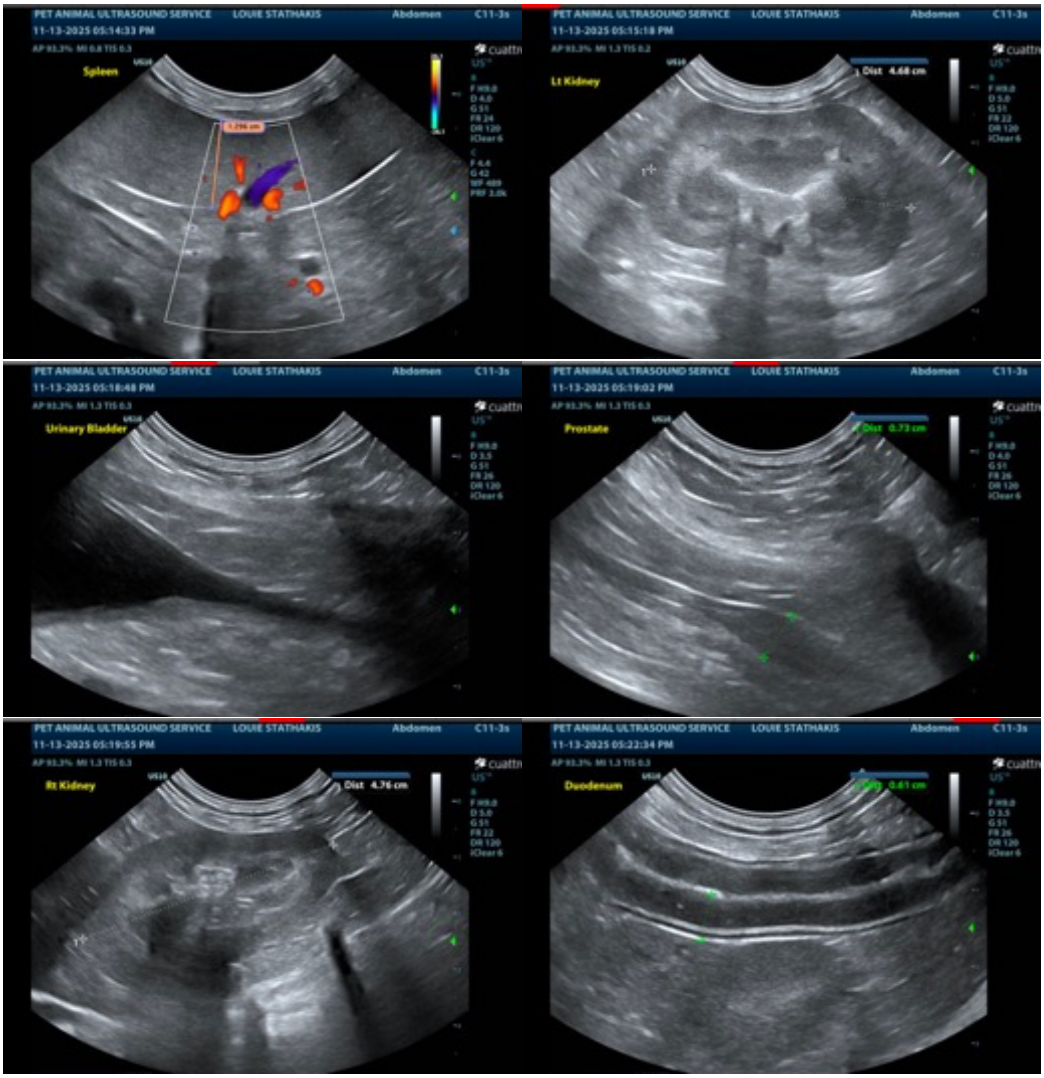

NAVIX DIAGNOSTIX ANIMAL SERVICES

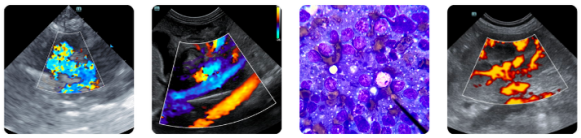

Clinical Sonography & Telecytology

Educational Teleconsultation Services™

SonoPath

FOSTERING THE ART OF VETERINARY MEDICINE™

SonoPath.com info@sonopath.com 1.800.838.4268

PATIENT

Louie Stathakis

SPECIES

Canine

BREED

Boston Terrier

SEX

MN

AGE

11 years

WEIGHT

23.3 lbs

INTERPRETED BY

Kathleen Sennello DVM, MS, Diplomate ACVIM (Small Animal Internal Medicine)

IMAGING PERFORMED BY

Pamela Harrigan, RDCS, Certified Veterinary Sonographer

HOSPITAL NAME

Norfolk County Veterinary Service

REFERRING VET

Dr. Amelia Ragon

INVOICE

10753

DATE

11/13/2025

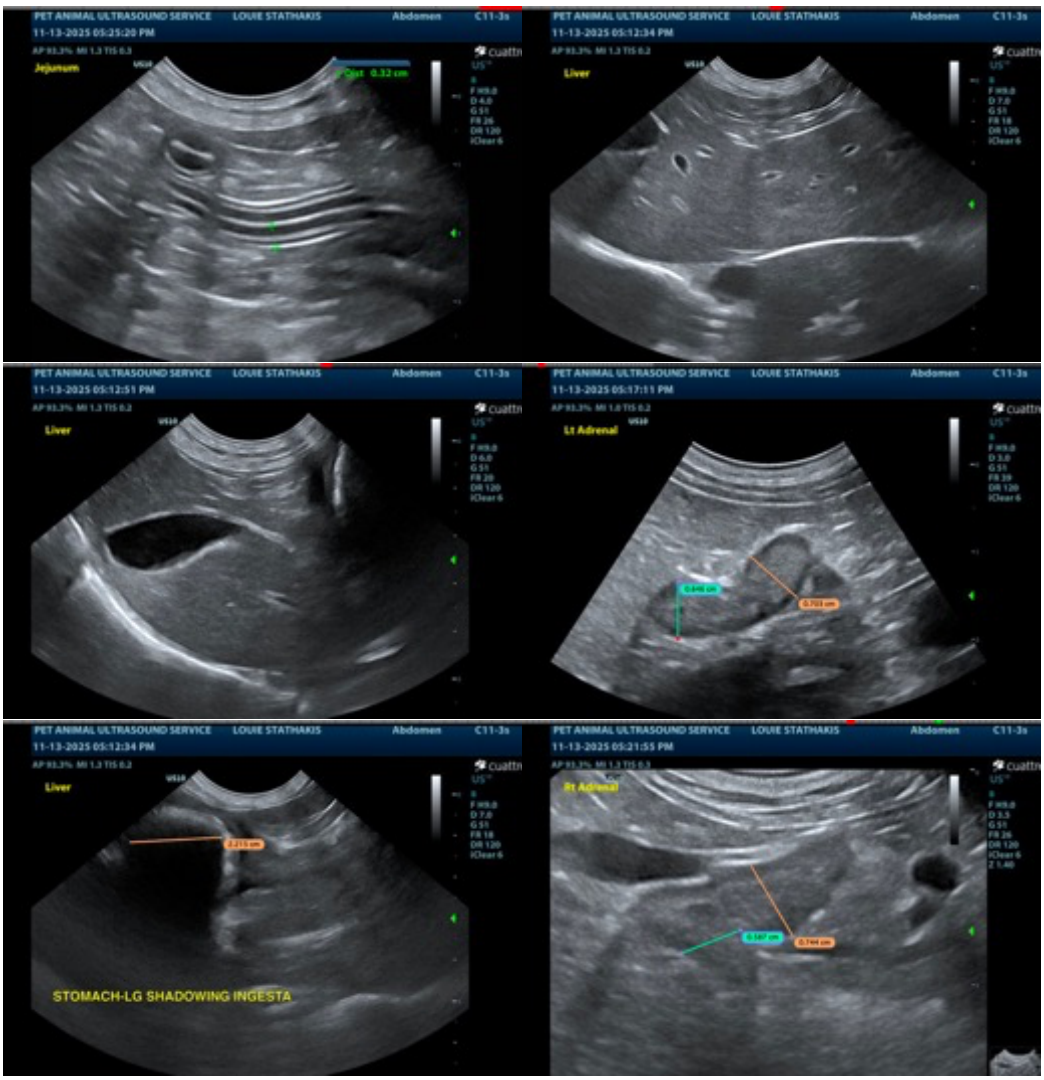

The information and recommendations provided are based on the images presented by the referring veterinarian/sonographer. No evaluation can be communicated regarding pathology that was not visible in the image/video clips provided.

Thank you for this referral. If the clinical or image interpretation does not parallel your findings or if I can be of any further assistance please contact me.

Kathleen Sennello DVM,MS, Diplomate ACVIM (Small animal Internal Medicine)

info@sonopath.com