



## PATIENT

Kairos de Soto

## SPECIES

Canine

## BREED

Lab x

## SEX

Spayed Female

## AGE

6 Years 10 Months

## WEIGHT

58.6 lbs

## INTERPRETED BY

Kathleen Sennello DVM,  
MS, Diplomate ACVIM  
(Small Animal Internal  
Medicine)

## IMAGING PERFORMED BY

Dr. Sarah Green

## HOSPITAL NAME

Healing Spirit Animal  
Wellness

## REFERRING VET

Dr. Sarah Green

## INVOICE

71747

## DATE

11/12/25

## PRESENTING CLINICAL SIGNS

History of pica. Enterotomies performed due to foreign body obstruction 6/10/25 (peach pit) and 7/16/25 (foam ball), recent history of excessive stretching. Kairos has been eating well is not overtly painful on palpation. No radiographic evidence of mechanical obstruction.

Abnormal PE/Chem/CBC/UA Results: No abnormal findings

## ULTRASONOGRAPHIC EXAMINATION OF THE ABDOMEN

### Urinary System

The urinary bladder is moderately distended with anechoic urine. The Bladder wall, trigone, ureteral papillae and visible urethra (to a depth of 2cm) appear normal with no evidence of wall thickening, mucosal irregularities, masses or cystic calculi.

The left kidney has a normal shape and size (6.52 cm). Overall echogenicity is normal with adequate corticomedullary distinction and a typical 1:3 cortex:medulla ratio. There is no evidence of focal perinephric inflammation or effusion. There is no evidence of pyelectasia, nephroliths, infarcts or hydroureter. Renal vasculature is normal.

The right kidney has a normal shape and size (5.93 cm). Overall echogenicity is normal with adequate corticomedullary distinction and a typical 1:3 cortex:medulla ratio. There is no evidence of focal perinephric inflammation or effusion. There is no evidence of pyelectasia, nephroliths, infarcts or hydroureter. Renal vasculature is normal.

### Adrenal Glands

The region of left adrenal (Cranial to left renal artery) is unremarkable but the adrenal is not distinctly visualized. No evidence of a mass effect is visualized.

The region of the right adrenal (between right cranial kidney and vena cava) is unremarkable, but the adrenal is not distinctly visualized. No evidence of a mass effect is visualized.

### Spleen

The spleen is subjectively normal in size (2.73 cm), echotexture is homogenous, and the splenic capsule is smooth with no irregularities. The blood flow through the hilus and splenic parenchyma appears normal. No focal parenchymal abnormalities are visualized.

### Liver

The liver is subjectively normal in size, and echogenicity with smooth peripheral margins. The parenchyma is homogenous echotexture. The visible portions of the vasculature and biliary tract appear normal. No focal nodules or cystic lesions are observed.

The gall bladder lumen is moderately distended. The wall of the gall bladder is not thickened and has a smooth mucosal surface. Luminal contents are mild and likely incidental at this time. The cystic and common bile ducts are normal/not visible.



**PATIENT**

Kairos de Soto

**SPECIES**

Canine

**BREED**

Lab x

**SEX**

Spayed Female

**AGE**

6 Years 10 Months

**WEIGHT**

58.6 lbs

**INTERPRETED BY**

Kathleen Sennello DVM,  
MS, Diplomate ACVIM  
(Small Animal Internal  
Medicine)

**IMAGING PERFORMED BY**

Dr. Sarah Green

**HOSPITAL NAME**

Healing Spirit Animal  
Wellness

**REFERRING VET**

Dr. Sarah Green

**INVOICE**

71747

**DATE**

11/12/25

**Gastrointestinal**

The stomach contains minimal luminal contents. It measures at a normal thickness of <0.7cm with some variability due to the presence of rugal folds. The distinction of the gastric wall layers is adequate and there is no impression of reduced peristaltic activity. No masses or focal lesions were observed.

The visualized areas of duodenum, jejunum and ileum have a relatively uniform diameter with minimal fluid distension. Wall thickness is normal. Bowel loops follow a curvilinear path with distinct wall layering maintaining the typical 1:3 muscularis:mucosa layer ratio. Duodenum wall measures 0.51 cm. Jejunum wall measures 0.34 cm. Visualized peristalsis appears appropriate. There were no focal lesions consistent with obstruction or a mass effect observed.

Sections of colon are visualized with formed fecal material and gas shadowing distally. There is no observed focal or generalized colon wall thickening or loss of layering.

**Pancreas**

The pancreas is normal and isoechoic to surrounding mesentery. There is no evidence of nodules or cystic lesions. There is no evidence of regional mesenteric inflammation or fluid.

**Free Abdomen**

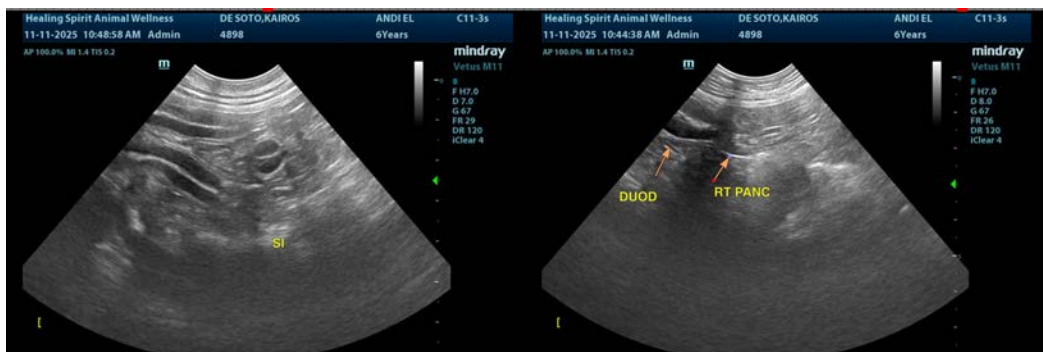Evaluation of the peritoneal cavity did not reveal any evidence of effusion, or subjective lymphadenomegaly. The Medial iliac nodes appear normal and there was no evidence of a caudal aortic thrombus at the bifurcation. The omentum is of normal uniform echogenicity.

**ULTRASONOGRAPHIC FINDINGS**

- No significant ultrasonographic lesions visualized.

**INTERPRETATION OF THE FINDINGS & FURTHER RECOMMENDATIONS**

No focal lesions are visualized on today's exam to explain the PICA reported. It is uncertain if there are currently other gastrointestinal symptoms or if biopsies have been taken at previous surgeries. There is no evidence of significant inflammation or adhesions, although not all adhesions can be readily visualized. If this is a significant concern, you could consider a contrast CT scan or laparoscopic evaluation or similar. If symptoms are progressive, you could consider repeat imaging in the future, looking for the development of new lesions.





## PATIENT

Kairos de Soto

## SPECIES

Canine

## BREED

Lab x

## SEX

Spayed Female

## AGE

6 Years 10 Months

## WEIGHT

58.6 lbs

## INTERPRETED BY

Kathleen Sennello DVM,  
MS, Diplomate ACVIM  
(Small Animal Internal  
Medicine)

## IMAGING PERFORMED BY

Dr. Sarah Green

## HOSPITAL NAME

Healing Spirit Animal  
Wellness

## REFERRING VET

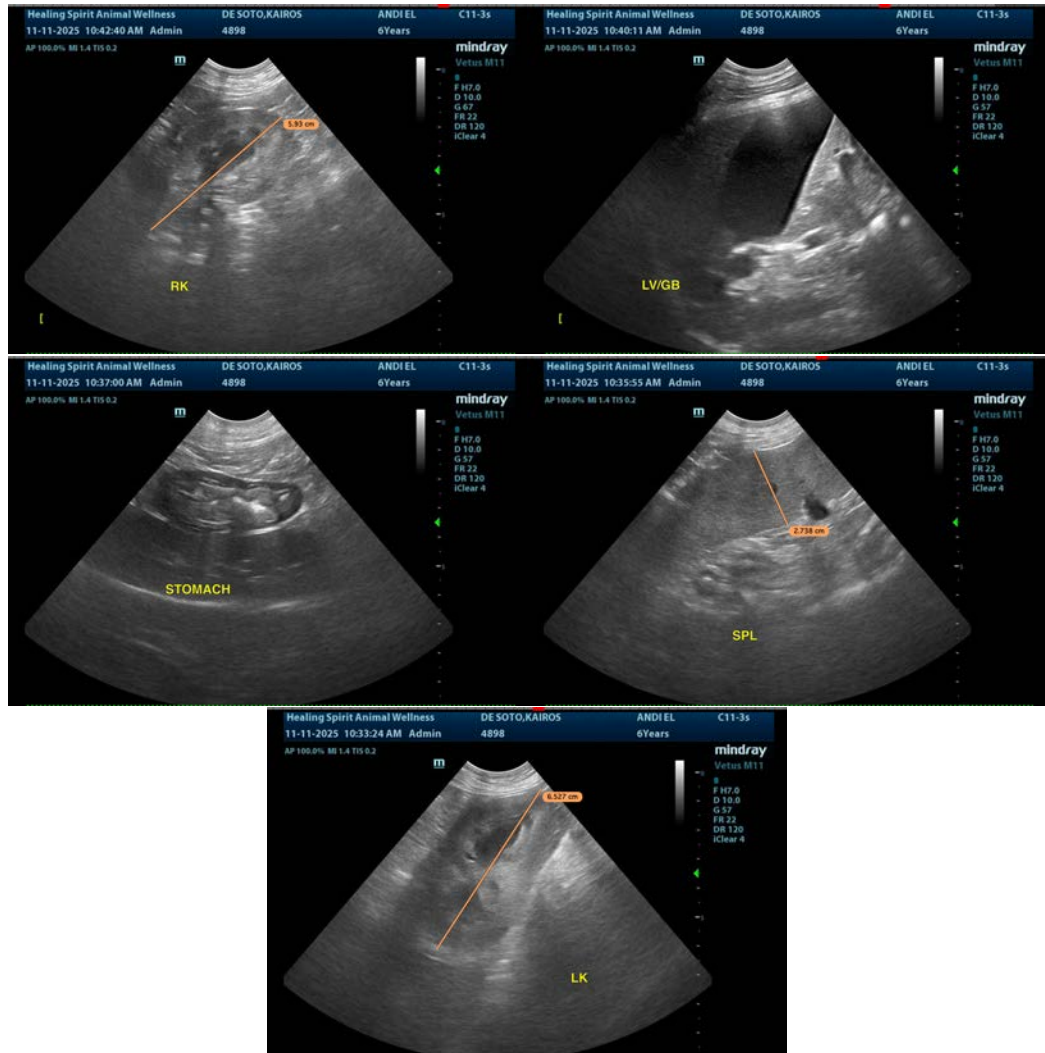
Dr. Sarah Green

## INVOICE

71747

## DATE

11/12/25



The information and recommendations provided are based on the images presented by the referring veterinarian/sonographer. No evaluation can be communicated regarding pathology that was not visible in the image/video clips provided.

Thank you for this referral. If the clinical or image interpretation does not parallel your findings or if I can be of any further assistance please contact me.

Kathleen Sennello DVM,MS, Diplomate ACVIM (Small animal Internal Medicine)

info@sonopath.com