



PATIENT

Sophia Haenschen

SPECIES

Feline

BREED

DSH

SEX

Spayed Female

AGE

12.5 Years

WEIGHT

8.9 Pounds

INTERPRETED BY

Kathleen Sennello DVM,
MS, Diplomate ACVIM
(Small Animal Internal
Medicine)

**IMAGING
PERFORMED BY**

Kelly Vazquez

HOSPITAL NAME

Westwood Regional

REFERRING VET

Dr. Hartwick

INVOICE

42687

DATE

11/10/22

PRESENTING CLINICAL SIGNS

2 weeks ago - vomited daily x 5 days, progressive decline in appetite now. Not eating or drinking. Last stool passed was 1 week ago. Lethargic, weight loss, dehydrated. Radiographs show nodular to ground glass or inflammatory pattern. Cranial and ventral abdomen; loss of detail and possible bunching of small intestines.

Abnormal PE/Chem/CBC/UA Results: CBC: WNL. Chem: WNL.

ULTRASONOGRAPHIC EXAMINATION OF THE ABDOMEN

Urinary System

The urinary bladder is moderately distended with mildly echogenic urine. The Bladder wall, trigone, ureteral papillae and visible urethra (to a depth of 2cm) appear normal with no evidence of wall thickening, mucosal irregularities, masses or cystic calculi.

The left kidney has a normal shape and size (3.23 cm). Overall echogenicity is normal with adequate corticomedullary distinction and a typical 1:3 cortex:medulla ratio. There is no evidence of focal perinephric inflammation or effusion. There is no evidence of pyelectasia, nephroliths, infarcts or hydroureter. Renal vasculature is normal.

The right kidney has a normal shape and size (3.53 cm). Overall echogenicity is normal with adequate corticomedullary distinction and a typical 1:3 cortex:medulla ratio. There is no evidence of focal perinephric inflammation or effusion. There is no evidence of pyelectasia, nephroliths, infarcts or hydroureter. Renal vasculature is normal.

Adrenal Glands

The left adrenal gland is normal in size measuring 0.26 cm at the caudal pole. It is observed in its normal position cranial to the left renal artery. It is normal in appearance (uniformly hypoechoic) and shape with no evidence of a mass effect.

The region of the right adrenal (between right cranial kidney and vena cava) is unremarkable, but the adrenal is not distinctly visualized. No evidence of a mass effect.

Spleen

The spleen is subjectively normal in size, echotexture is homogenous, and the splenic capsule is smooth with no irregularities. The spleen measures 0.63 cm in width at the level of the hilus. The blood flow through the hilus and splenic parenchyma appears normal. No focal parenchymal abnormalities are visualized.

Liver

The liver is subjectively normal in size, and echogenicity with smooth peripheral margins. The parenchyma is homogenous echotexture. The visible portions of the vasculature and biliary tract appear normal. No focal nodules or cystic lesions are observed.

The gallbladder lumen is moderately distended. The wall of the gall bladder is not thickened and has a smooth mucosal surface. Luminal contents are mild and primarily anechoic. The cystic duct appears tortuous and dilated, measuring 0.46 cm proximally and 0.27 cm slightly more distally. No obvious obstruction is noted, but the suspected pancreatic mass may be causing a partial obstruction.



PATIENT

Sophia Haenschen

SPECIES

Feline

BREED

DSH

SEX

Spayed Female

AGE

12.5 Years

WEIGHT

8.9 Pounds

INTERPRETED BY

Kathleen Sennello DVM,
MS, Diplomate ACVIM
(Small Animal Internal
Medicine)

**IMAGING
PERFORMED BY**

Kelly Vazquez

HOSPITAL NAME

Westwood Regional

REFERRING VET

Dr. Hartwick

INVOICE

42687

DATE

11/10/22

Gastrointestinal

The stomach contains moderate fluid. It measures at a normal thickness of <0.36cm with some variability due to the presence of rugal folds. The distinction of the gastric wall layers is adequate and there is no impression of reduced peristaltic activity. No masses or focal lesions were observed.

The visualized areas of duodenum, jejunum and ileum have a relatively uniform diameter with minimal fluid distension. Wall thickness is normal. Bowel loops follow a curvilinear path with distinct wall layering maintaining the typical 1:3 muscularis:mucosa layer ratio. The duodenum measured as normal (between 0.13-0.38cm in wall thickness) and the jejunum measured as normal (between 0.15-0.36cm.) Visualized peristalsis appears appropriate. There were no focal lesions consistent with obstruction or a mass effect observed.

The ileocecal junction was visualized and exhibited normal intact wall layering and is subjectively of normal thickness. Sections of colon are visualized with formed fecal material and gas shadowing distally. There is no observed focal or generalized colon wall thickening or loss of layering.

Pancreas

The pancreas is large and hypoechoic to surrounding mesentery. There is a large, hypoechoic, severely inflamed mass effect measuring 2.36 cm x 2.42 cm in the right cranial abdomen, adjacent to the duodenum, which is most consistent with a pancreatic mass in the region of the right limb of the pancreas. There is evidence of severe regional mesenteric inflammation and free fluid, most consistent with a mass effect and moderate to severe pancreatitis. Consistent with moderate to severe pancreatitis.

Free Abdomen

There is a small to moderate amount of free abdominal fluid. No lymphadenopathy is noted. The omentum is severely hyperechoic in the region of the cranial abdominal mass effect and the pancreas.

PRIMARY FINDINGS

- Large, hypoechoic, severely inflamed pancreas with a focal mass effect in the right cranial abdomen, most consistent with a pancreatic mass lesion – Primary differentials include carcinoma, round cell neoplasia, adenoma, abscess, other. Additionally, I cannot rule out the possibility that this is an atypical hepatic mass, much less likely right adrenal mass, etc.
- Dilated/tortuous bile duct – Dilation of the common bile duct could be consistent with a functional obstruction (i.e. primary hepatic disease resulting in hepatocellular swelling) or with an extrahepatic bile duct obstruction (ie. choledocholith, bile duct tumor, pancreatic disease, other).
- Fluid distention of the stomach – This could be due to gastric ileus secondary to the pancreatic inflammation.
- Small to moderate amount of free abdominal fluid and hyperechoic mesentery – Findings are most consistent with peritonitis (sterile versus bacterial). Recommend sampling.

SECONDARY FINDINGS

- Mildly echogenic debris in the urinary bladder – The echogenic debris in the bladder lumen could be consistent with cells, crystals, and/or mucus.



PATIENT

Sophia Haenschen

SPECIES

Feline

BREED

DSH

SEX

Spayed Female

AGE

12.5 Years

WEIGHT

8.9 Pounds

INTERPRETED BY

Kathleen Sennello DVM,
MS, Diplomate ACVIM
(Small Animal Internal
Medicine)

**IMAGING
PERFORMED BY**

Kelly Vazquez

HOSPITAL NAME

Westwood Regional

REFERRING VET

Dr. Hartwick

INVOICE

42687

DATE

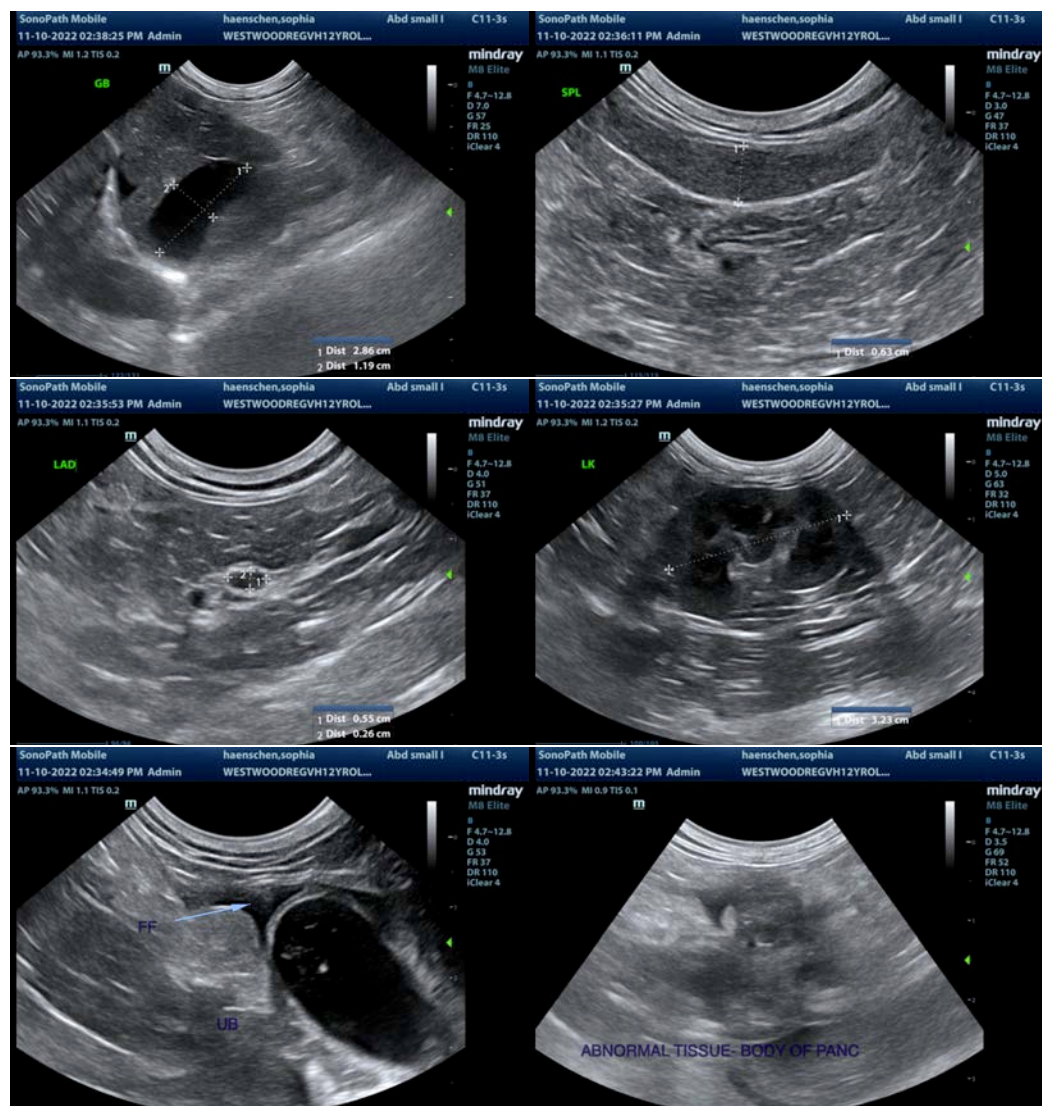
11/10/22

INTERPRETATION OF THE FINDINGS & FURTHER RECOMMENDATIONS

There is a large hypoechoic inflamed mass effect in the right cranial abdomen, which is most consistent with a pancreatic mass lesion (or abscess), although a hepatic mass or less likely an adrenal mass lesion are possibilities. Recommend a fine needle aspirate of this mass with cytology +/- culture. There is a large amount of generalized pancreatic inflammation observed. The location of this could be causing a partial biliary obstruction and causing regional inflammation and gastric ileus.

Recommend three view thoracic radiographs to evaluate for possible concurrent thoracic disease/involvement.

If a cytologic diagnosis cannot be obtained, then consider obtaining surgical biopsies. Recommend referral to a board-certified veterinary surgeon, as a significant resection may be necessary.





PATIENT

Sophia Haenschen

SPECIES

Feline

BREED

DSH

SEX

Spayed Female

AGE

12.5 Years

WEIGHT

8.9 Pounds

INTERPRETED BY

Kathleen Sennello DVM,
MS, Diplomate ACVIM
(Small Animal Internal
Medicine)

**IMAGING
PERFORMED BY**

Kelly Vazquez

HOSPITAL NAME

Westwood Regional

REFERRING VET

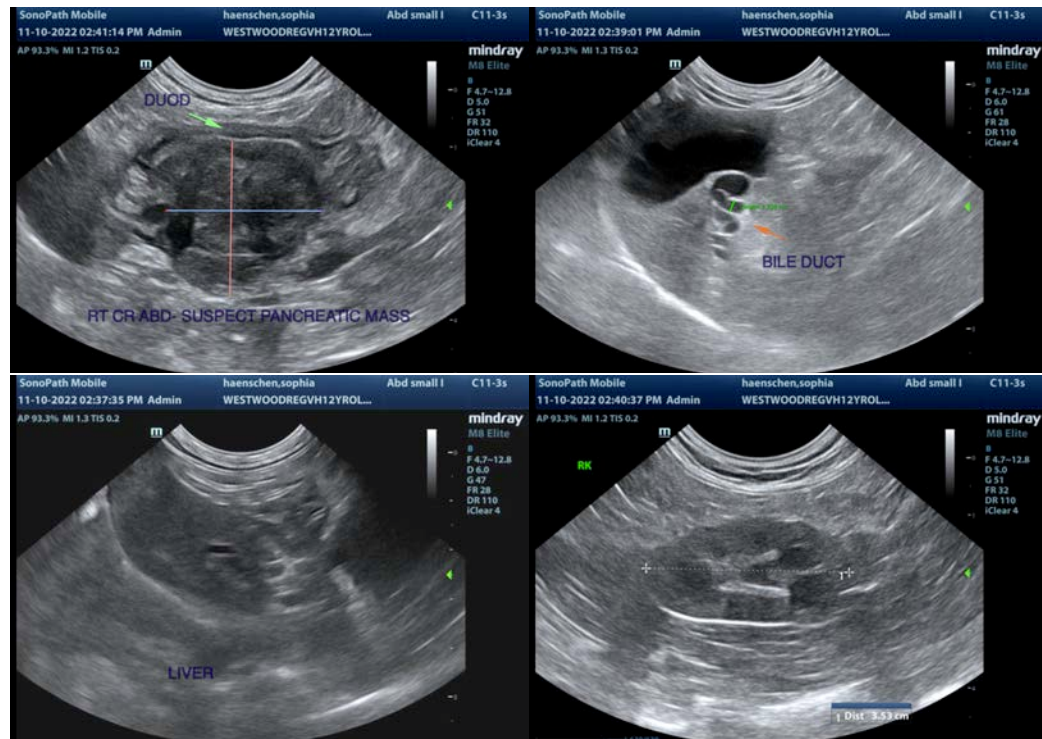
Dr. Hartwick

INVOICE

42687

DATE

11/10/22



The information and recommendations provided are based on the images presented by the referring veterinarian/sonographer. No evaluation can be communicated regarding pathology that was not visible in the image/video clips provided.

Thank you for this referral. If the clinical or image interpretation does not parallel your findings or if I can be of any further assistance please contact me.

Kathleen Sennello DVM,MS, Diplomate ACVIM (Small animal Internal Medicine)

kathleen.sennello@sonopath.com