

**DATE**

10/8/21

PRESENTING CLINICAL SIGNS

Urinating outside of box. On/off for 2 years. Treated with antibiotics and anti-inflammatory. Pre rx lab baseline prior to initiating behavior drugs revealed abnormalities. Also weight loss 1.2lbs since July, 2021.

PATIENT

Juan Walsh

Current Medications: Amlodipine 2.5mg 1/4 tab SID

Lab Results: PCV 22% Globulin 5.4 Albumin 2.3 BUN 72

SPECIES

Feline

Date of Previous IntraPet Ultrasound: no previous

Sedation: not needed

Stat Report: not requested

BREED

Domestic Shorthair

ULTRASONOGRAPHIC EXAMINATION OF THE ABDOMEN**SEX**

Neutered male

Urinary System

The urinary bladder is moderately distended with anechoic urine. The Bladder wall, trigone, ureteral papillae and visible urethra (to a depth of 2cm) appear normal with no evidence of wall thickening, mucosal irregularities, masses or cystic calculi.

AGE

2016

The left kidney has a normal shape and size (4.31 cm). Overall echogenicity is slightly hyperechoic with poor corticomedullary distinction and a typical 1:3 cortex:medulla ratio. There is no evidence of perinephric inflammation or effusion. Pyelectasia was noted and measured 0.11 cm. There is no evidence of nephroliths, infarcts or hydroureter. Renal vasculature is normal.

WEIGHT

9.8 lbs

The right kidney has a normal shape and size (3.92 cm). Overall echogenicity is slightly hyperechoic with poor corticomedullary distinction and a typical 1:3 cortex:medulla ratio. There is no evidence of perinephric inflammation or effusion. Pyelectasia was noted and measured 0.17 cm. There is no evidence of nephroliths, infarcts or hydroureter. Renal vasculature is normal.

INTERPRETED BY

Kathleen Sennello
DVM, MS, Diplomate
ACVIM (Small Animal
Internal Medicine)

Adrenal Glands

The left adrenal gland is normal in size measuring 0.5 cm at the caudal pole. It is observed in its normal position cranial to the left renal artery. It is normal in appearance (uniformly hypoechoic) and shape with no evidence of a mass effect.

HOSPITAL NAME

Bel Air VH

The region of the right adrenal (between right cranial kidney and vena cava) is unremarkable, but the adrenal is not distinctly visualized. No evidence of a mass effect.

REFERRING VET

Dr. Schmidt

Spleen

The spleen is subjectively normal in size, echotexture is homogenous, and the splenic capsule is smooth with no irregularities. The blood flow through the hilus and splenic parenchyma appears normal. No focal parenchymal abnormalities are visualized.

INVOICE

92285

Liver

The liver is subjectively normal in size, and echogenicity with smooth peripheral margins. The parenchyma is heterogenous in echotexture with subtle, indistinct focal mottling. The visible portions of the vasculature and biliary tract appear normal. No focal nodules or cystic lesions are observed. The gallbladder lumen is moderately distended. The wall of the gallbladder is not thickened and has a smooth mucosal surface. Luminal contents are primarily anechoic. The cystic and common bile ducts are normal/not visible.

Gastrointestinal

The stomach contains minimal luminal contents. It measures at a normal thickness of <0.36cm with some variability due to the presence of rugal folds. The distinction of the gastric wall layers is adequate and there is no impression of reduced peristaltic activity. No masses or focal lesions were observed.

The visualized areas of duodenum, jejunum and ileum have a uniform diameter with minimal fluid distension. Wall thickness is normal to slightly increased. Bowel loops follow a typical curvilinear path with distinct wall layering, but some areas display a prominent muscularis layer which does not display the typical 1:3 muscularis:mucosa layer ratio. The duodenum measured 0.27 cm and jejunum measured 0.21 cm. Visualized peristalsis appears appropriate. There were no focal lesions consistent with obstruction or a mass effect observed.

The ileocecal junction was visualized and exhibited normal intact wall layering and is subjectively of normal thickness. Sections of colon are visualized with formed fecal material and gas shadowing distally. There is no observed focal or generalized colon wall thickening or loss of layering.

Pancreas

The pancreas is prominent and hypoechoic as compared to the surrounding isoechoic mesentery. There is no evidence of nodules or cystic lesions. There is no evidence of regional mesenteric inflammation or fluid.

Free Abdomen

Evaluation of the peritoneal cavity did not reveal any evidence of effusion, or subjective lymphadenomegaly. The Medial iliac nodes appear normal and there was no evidence of a caudal aortic thrombus at the bifurcation. The omentum is of normal uniform echogenicity.

ULTRASONOGRAPHIC FINDINGS

PRIMARY FINDINGS:

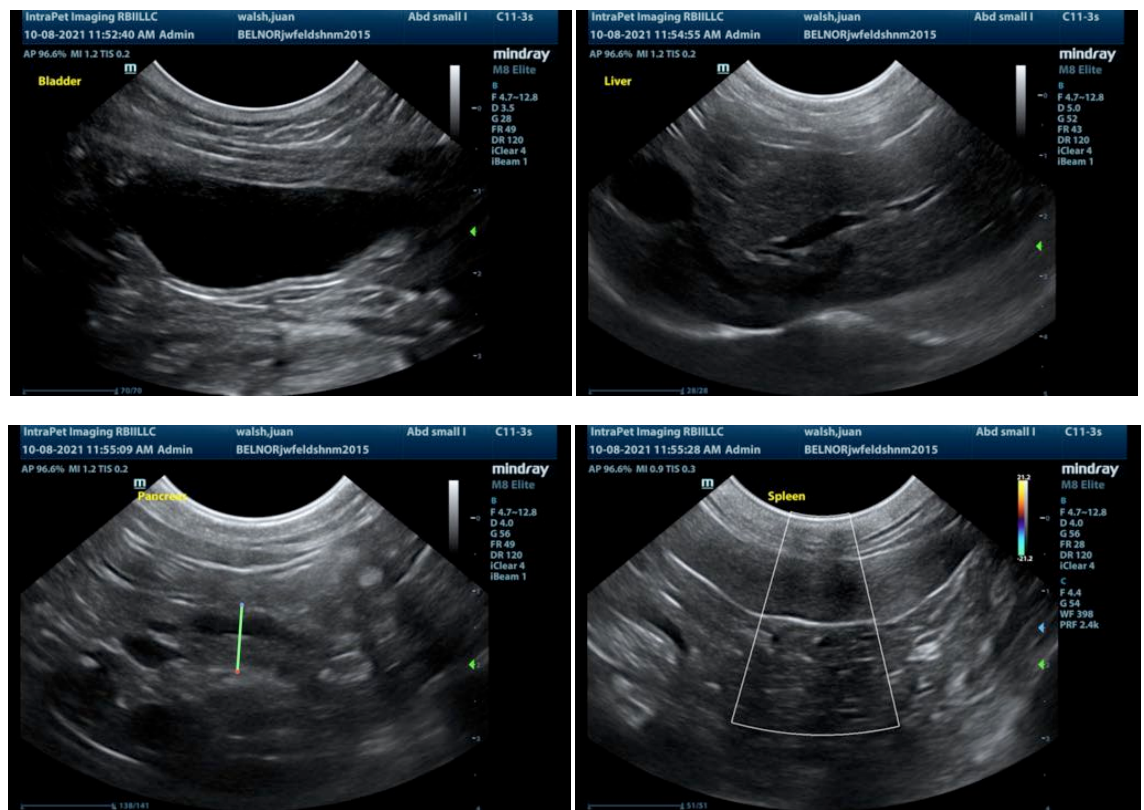
- Decreased corticomedullary distinction in both kidneys with mild pyelectasia. Mild loss of corticomedullary distinction in both kidneys could be consistent with chronic degenerative disease or interstitial nephrosis. Pyelectasia of the kidneys could be consistent with pyelonephritis, chronic renal disease, secondary to PU/PD or fluid therapy (if applicable), other.
- Prominent hypoechoic pancreas. The pancreatic changes are most consistent with age-related parenchymal remodeling, potentially secondary to a prior inflammatory episode, early fibrosis or chronic pancreatitis.
- Heterogenous liver. The diffuse hepatic changes are non-specific and could be consistent with vacuolar hepatopathy, nodular hyperplasia, inflammatory/immune-mediated disease, fibrosis, extramedullary hematopoiesis, toxic hepatopathy (e.g., copper), infiltrative neoplasia (less likely) or other hepatopathy. If the liver values are not elevated on blood work this may be an incidental finding.
- Prominent muscularis layer to the small intestine. The small intestinal wall changes are most consistent with an inflammatory process (i.e., inflammatory bowel disease) with a low possibility of emerging lymphoma.

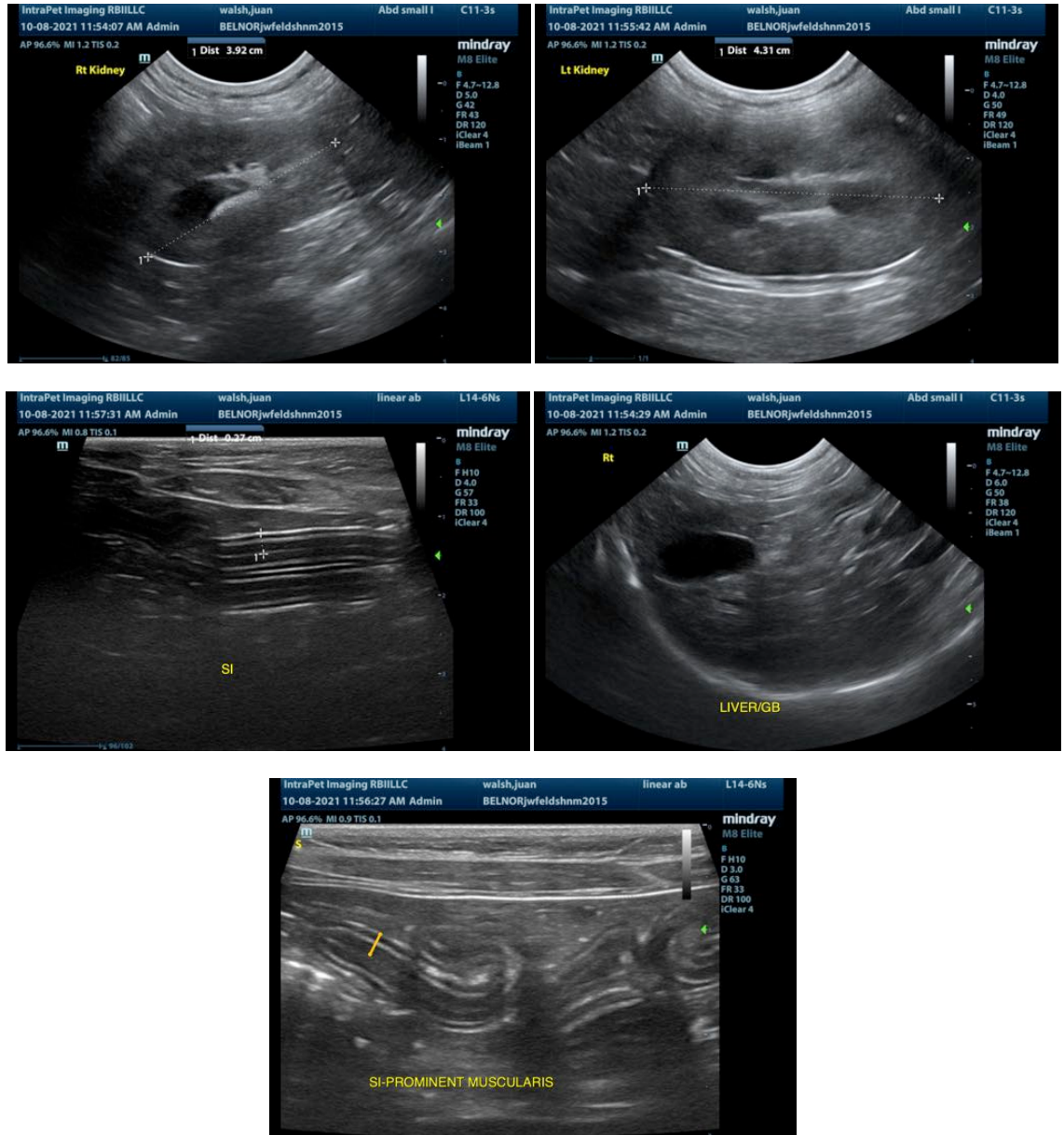
INTERPRETATION OF THE FINDINGS & FURTHER RECOMMENDATIONS

The renal changes observed are consistent with early kidney disease although the history provided reports mildly concentrated urine so other differentials must be considered. I recommend urinalysis and culture to look for evidence of pyelonephritis due to the mild pyelectasia reported. I recommend blood pressure evaluation and thyroid evaluation. Additionally consider an ACTH stimulation test due to the eosinophilia and hypoglycemia reported. An ACTH stimulation test is recommended to check for Addison's disease.

Additionally, I recommend urine protein to creatinine ratio to try to determine if the proteinuria reported is significant.

The proteinuria would have to be very significant to be responsible for the systemic hypoalbuminemia reported. Consider other causes such as liver disease. I recommend a liver function test to further evaluate for this and/or a protein losing enteropathy. There were some mild bowel changes observed so this is a possibility. Consider a GI panel with a quantitative fPLI to further evaluate for pancreatic disease and a B12 folate to look for evidence of small intestinal disease. If small intestinal protein loss is suspected GI biopsies may be indicated. I recommend three view thoracic radiographs.





The information and recommendations provided are based on the images presented by the referring veterinarian. No evaluation can be communicated regarding pathology that was not visible in the image/video clips provided.

Thank you for this referral. If the clinical or image interpretation does not parallel your findings or if I can be of any further assistance please contact me.

Kathleen Sennello DVM,MS, Diplomate ACVIM (Small animal Internal Medicine)

kathleen.sennello@sonopath.com