

IMAGING PERFORMED BY

IntraPet.com



**SonoPath**

Clinical Sonography & Telecytology

EDUCATIONAL TELECONSULTATION SERVICES™

1-800-838-4268 info@sonopath.com SonoPath.com

**DATE PRESENTING CLINICAL SIGNS**

10/7/22

To RDVM on the 26th. Bloodwork done on the visit and all WNL. Owner dropped off a urine sample. At ER 5 weeks ago for wheezing and treated for pneumonia. Fine this am, went outside for walk at the park and did not want to walk. Got the urine sample, and took to the RDVM. Whimpered when owner lifted up on his abdomen then did not want to get up or move at home. Not wanting to eat his dinner. Owner gave milk and he drank about 1/2 a bottle.

**PATIENT**

Wyatt Ruth

**SPECIES**

Canine

**BREED**

German Shepherd X

**SEX**

Neutered Male

**AGE**

10/1/12

**WEIGHT**

92 Pounds

**INTERPRETED BY**

Kathleen Sennello DVM,  
MS, Diplomate ACVIM  
(Small Animal Internal  
Medicine)

**IMAGING PERFORMED BY**

Rachel Brillhart RDMS

**HOSPITAL NAME**

Animal Emergency  
Hospital

**REFERRING VET**

Dr. Ruby

**INVOICE**

41919

Current Medications: Cerenia, Buprenorphine.

Lab Results: See attached.

Radiographs: Loss of detail in the cranial abdomen. Mass noted in the area of the spleen.

Date of Previous IntraPet Ultrasound: No previous.

Sedation: Not required to complete full diagnostic ultrasound.

Stat Report: Not requested.

**ULTRASONOGRAPHIC EXAMINATION OF THE ABDOMEN**

**Urinary System**

The urinary bladder is moderately distended with anechoic urine. The Bladder wall, trigone, ureteral papillae and visible urethra (to a depth of 2cm) appear normal with no evidence of wall thickening, mucosal irregularities, masses or cystic calculi.

The visualized areas of prostate and surrounding tissue appear normal. Unfortunately, the prostate is not fully visualized likely due to its intrapelvic location. Correlate with rectal exam findings.

The left kidney has a normal shape and size (7.36 cm). Overall echogenicity is normal with adequate corticomedullary distinction and a typical 1:3 cortex:medulla ratio. There is no evidence of focal perinephric inflammation or effusion. There is no evidence of pyelectasia, nephroliths, infarcts or hydroureter. Renal vasculature is normal.

The right kidney has a normal shape and size (7.51 cm). Overall echogenicity is normal with adequate corticomedullary distinction and a typical 1:3 cortex:medulla ratio. There is no evidence of focal perinephric inflammation or effusion. There is no evidence of pyelectasia, nephroliths, infarcts or hydroureter. Renal vasculature is normal.

**Adrenal Glands**

The left adrenal gland is normal in size measuring 0.68 cm at the caudal pole. It is observed in its normal position cranial to the left renal artery. It is normal in appearance (uniformly hypoechoic) and shape with no evidence of a mass effect.

The right adrenal gland is normal in size measuring 0.70 cm at the caudal pole. It is observed in its normal position between the cranial aspect of the right kidney and the caudal vena cava. It is normal in appearance (uniformly hypoechoic) and shape with no evidence of a mass effect.

**Spleen**

The spleen is large. The spleen echotexture is heterogenous and mottled, the splenic capsule is smooth with no irregularities. The blood flow through the hilus and splenic parenchyma appears normal. There is a large, irregular, hypoechoic mass effect arising from the spleen, measuring approximately 11.45 cm x 11.11 cm, which is likely a combination of mass effect and clot. There is free fluid surrounding this plane.

### **Liver**

The liver is subjectively normal in size, and echogenicity with smooth peripheral margins. The parenchyma is mildly heterogeneous in echotexture with subtle, indistinct focal mottling. The visible portions of the vasculature and biliary tract appear normal. No focal nodules or cystic lesions are observed.

The gallbladder lumen is moderately distended. The wall of the gall bladder is not thickened and has a smooth mucosal surface. Luminal contents are mild and primarily anechoic. The cystic and common bile ducts are normal/not visible.

### **Gastrointestinal**

The stomach contains minimal luminal contents. It measures at a normal thickness of <0.7cm with some variability due to the presence of rugal folds. The distinction of the gastric wall layers is adequate and there is no impression of reduced peristaltic activity. No masses or focal lesions were observed.

The visualized areas of duodenum, jejunum and ileum have a relatively uniform diameter with minimal fluid distension. Wall thickness is normal. Bowel loops follow a curvilinear path with distinct wall layering maintaining the typical 1:3 muscularis:mucosa layer ratio. The duodenum measured as normal (between 0.3-0.5cm in wall thickness) and the jejunum measured as normal (between 0.2-0.47cm.) Visualized peristalsis appears appropriate. There were no focal lesions consistent with obstruction or a mass effect observed.

The ileocecal junction was visualized and exhibited normal intact wall layering and is subjectively of normal thickness. Sections of colon are visualized with formed fecal material and gas shadowing distally. There is no observed focal or generalized colon wall thickening or loss of layering.

### **Pancreas**

The pancreas is normal and isoechoic to surrounding mesentery. There is no evidence of nodules or cystic lesions. There is no evidence of regional mesenteric inflammation or fluid.

### **Free Abdomen**

There is a moderate amount of free abdominal fluid (likely represents hemorrhage). No lymphadenopathy is noted. The omentum is of normal echogenicity.

### **Other**

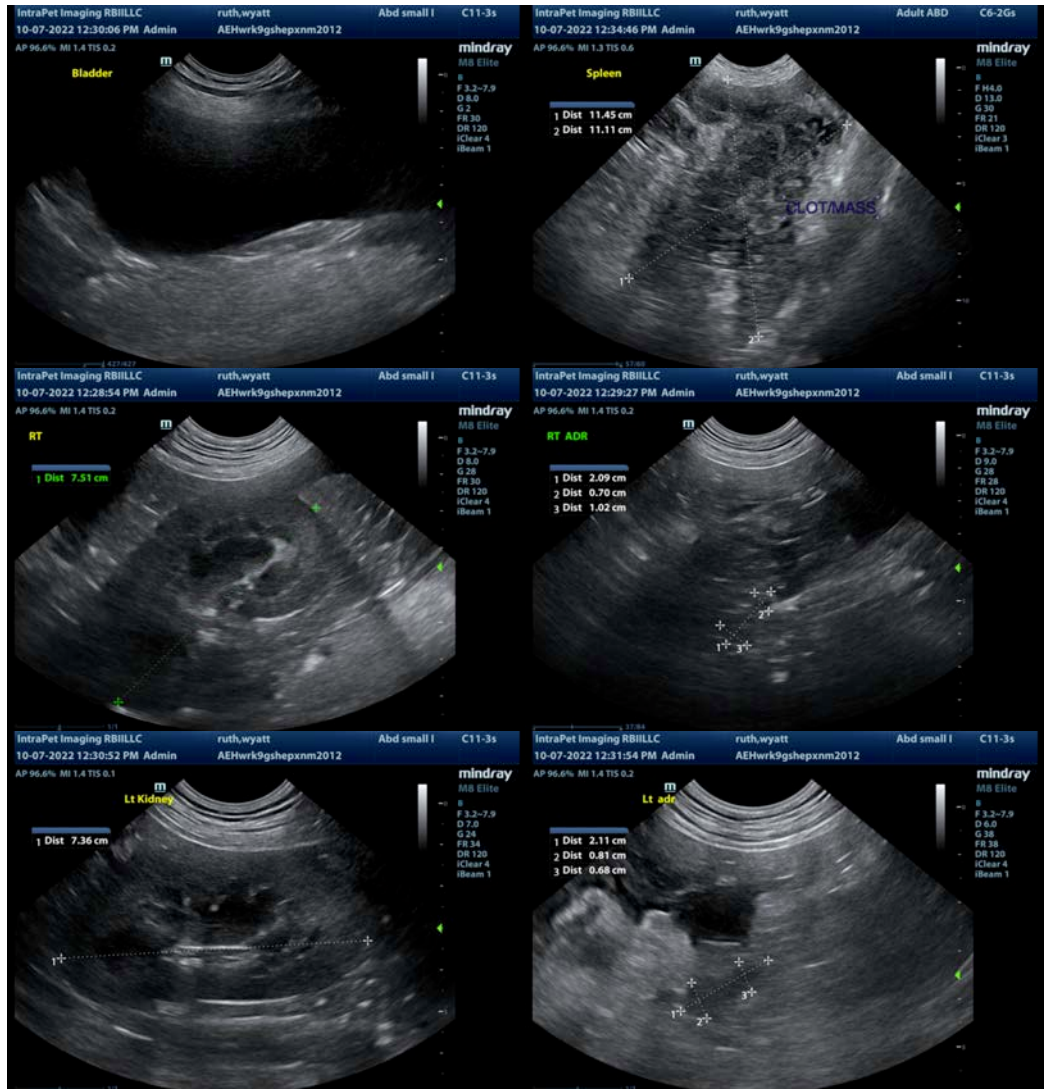
A brief view of the heart was submitted. No significant pericardial effusion was seen.

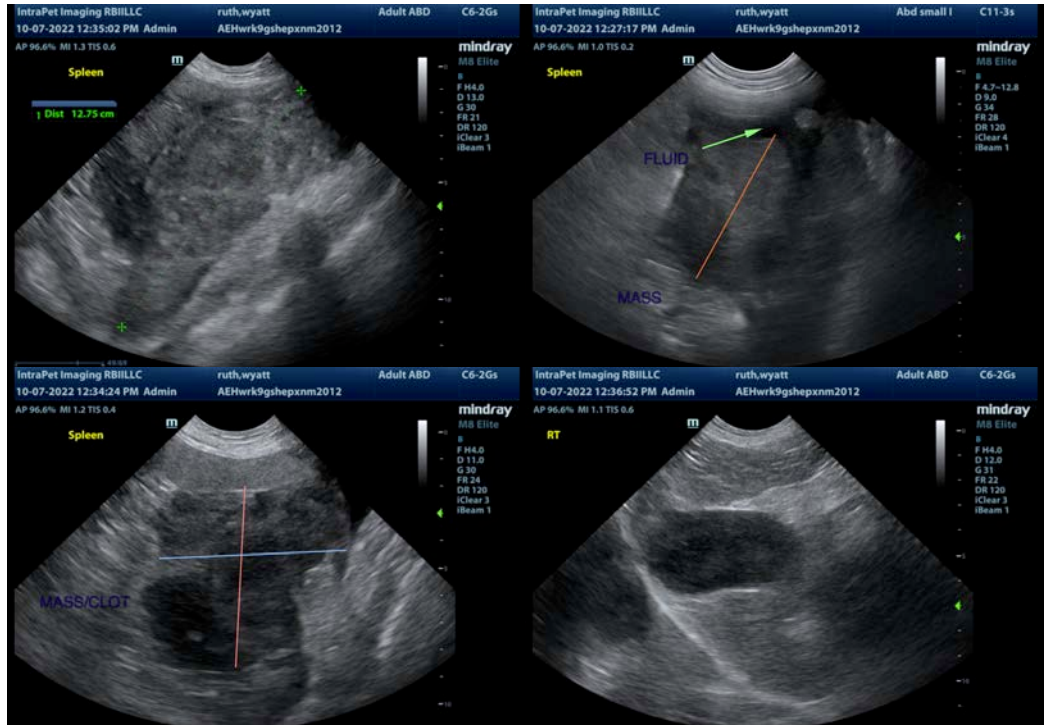
## **ULTRASONOGRAPHIC FINDINGS**

- Large, irregular, hypoechoic, cavitated splenic mass effect with surrounding free fluid and clot – A large, heterogeneous mass with cavitations is present within the splenic parenchyma. The mass distorts the splenic capsule. Differentials for the mass include neoplasia (e.g., hemangiosarcoma, hemangioma), hematoma, abscess, other. A neoplastic process is favored. This mass is suspected to have ruptured already.
- Mildly heterogeneous liver – The diffuse hepatic changes are non-specific and could be consistent with vacuolar hepatopathy, nodular hyperplasia, inflammatory/immune-mediated disease, fibrosis, extramedullary hematopoiesis, toxic hepatopathy (e.g., copper), infiltrative neoplasia (less likely) or other hepatopathy. This could represent age related remodeling.
- Small to moderate amount of free abdominal fluid – Recommend sampling. This is most consistent with a hemoabdomen.

## INTERPRETATION OF THE FINDINGS & FURTHER RECOMMENDATIONS

There is a large irregular mass effect associated with the spleen surrounded by hypoechoic tissue and free fluid, most consistent with a ruptured splenic mass. Recommend surgery for both diagnostic and therapeutic purposes. The liver appears slightly heterogeneous, but no focal lesions are visualized. Recommend biopsy at the time of surgery. Recommend 3-view thoracic radiographs prior to surgery.





The information and recommendations provided are based on the images presented by the referring veterinarian/sonographer. No evaluation can be communicated regarding pathology that was not visible in the image/video clips provided.

Thank you for this referral. If the clinical or image interpretation does not parallel your findings or if I can be of any further assistance please contact me.

Kathleen Sennello DVM,MS, Diplomate ACVIM (Small animal Internal Medicine)  
kathleen.sennello@sonopath.com