

**DATE**

10/7/21

**PRESENTING CLINICAL SIGNS**

History: Chronic skin/allergy issues. Potbellied/craniorganomegally. Gradual weight loss. Chronic soft stool  
Current Medications: Enrofloxacin flavor tab 136mg, Vetprofen tablets 100mg  
Lab Results: Attached.  
Radiographs: N/A  
Date of Previous IntraPet Ultrasound: No previous.  
Sedation: Not needed.  
Stat Report: Not requested.

**PATIENT**

Summer Pelletier

**SPECIES**

Canine

**BREED**

Goldendoodle

**SEX**

Spayed Female

**AGE**

2010

**WEIGHT**

63.2 lbs

**INTERPRETED BY**

Kathleen Sennello  
DVM, MS, Diplomate  
ACVIM (Small Animal  
Internal Medicine)

**HOSPITAL NAME**

Bayside Animal  
Medical Center

**REFERRING VET**

Dr. Buchanan

**INVOICE**

92243

**ULTRASONOGRAPHIC EXAMINATION OF THE ABDOMEN****Urinary System**

The urinary bladder is moderately distended with anechoic urine. The Bladder wall, trigone, ureteral papillae and visible urethra (to a depth of 2cm) appear normal with no evidence of wall thickening, mucosal irregularities or masses. In some views there are small specks of hyperechoic debris that is most consistent with small, sandy debris. Correlate findings with abdominal radiographs to rule out small stones.

The left kidney has a normal shape and size (6.12 cm). Overall echogenicity is normal with adequate corticomedullary distinction and a typical 1:3 cortex:medulla ratio. There is no evidence of perinephric inflammation or effusion. There is no evidence of pyelectasia, nephroliths, infarcts or hydroureter. Renal vasculature is normal.

The right kidney has a normal shape and size (5.44 cm). Overall echogenicity is normal with adequate corticomedullary distinction and a typical 1:3 cortex:medulla ratio. There is no evidence of perinephric inflammation or effusion. Small, non-obstructive nephroliths were noted. There is no evidence of pyelectasia, infarcts or hydroureter. Renal vasculature is normal.

**Adrenal Glands**

The left adrenal gland is normal in size measuring 0.82 cm at the caudal pole It is observed in its normal position cranial to the left renal artery. It is normal in appearance (uniformly hypoechoic) and shape with no evidence of a mass effect.

The right adrenal gland is normal in size measuring 0.6 cm at the caudal pole It is observed in its normal position between the cranial aspect of the right kidney and the caudal vena cava. It is normal in appearance (uniformly hypoechoic) and shape with no evidence of a mass effect.

**Spleen**

The spleen is subjectively normal in size, echotexture is homogenous, and the splenic capsule is smooth with no irregularities. The blood flow through the hilus and splenic parenchyma appears normal. No focal parenchymal abnormalities are visualized.

**Liver**

The liver is subjectively normal in size, and echogenicity with smooth peripheral margins. The parenchyma is heterogenous in echotexture with subtle, indistinct focal mottling. The visible portions of the vasculature and biliary tract appear normal. The irregular hepatic parenchyma sometimes creates ill-defined, hypoechoic nodules measuring from 0.3-0.98 cm. The gallbladder lumen is moderately distended. The wall of the gallbladder is not thickened and has a smooth mucosal surface. There is a moderate amount of non-organized echogenic debris. The cystic and common bile ducts are normal/not visible.

### ***Gastrointestinal***

The stomach contains minimal luminal contents. It measures at a normal thickness of <0.7cm with some variability due to the presence of rugal folds. The distinction of the gastric wall layers is adequate and there is no impression of reduced peristaltic activity. No masses or focal lesions were observed.

The visualized areas of duodenum, jejunum and ileum have a relatively uniform diameter with minimal fluid distension. Wall thickness is normal. Bowel loops follow a curvilinear path with distinct wall layering maintaining the typical 1:3 muscularis:mucosa layer ratio. The duodenum measured as normal and the jejunum measured as normal (0.25 cm, 0.32 cm). Visualized peristalsis appears appropriate. There were no focal lesions consistent with obstruction or a mass effect observed.

The ileocecal junction was visualized and exhibited normal intact wall layering and is subjectively of normal thickness. Sections of colon are visualized with formed fecal material possible small bits of foreign material and gas shadowing distally. There is no observed focal or generalized colon wall thickening or loss of layering.

### ***Pancreas***

The pancreas is normal and isoechoic to surrounding mesentery. There is no evidence of nodules or cystic lesions. There is no evidence of regional mesenteric inflammation or fluid.

### ***Free Abdomen***

Evaluation of the peritoneal cavity did not reveal any evidence of effusion. There is a mildly prominent sublumbar lymph node visualized at 0.61 cm. There was no evidence of a caudal aortic thrombus at the bifurcation. The omentum is of normal uniform echogenicity.

## **ULTRASONOGRAPHIC FINDINGS**

### **PRIMARY FINDINGS:**

- Heterogenous liver with ill-defined, hypoechoic nodules. The diffuse hepatic changes are non-specific and could be consistent with vacuolar hepatopathy, nodular hyperplasia, inflammatory/immune-mediated disease, fibrosis, extramedullary hematopoiesis, toxic hepatopathy (e.g., copper), infiltrative neoplasia (less likely) or other hepatopathy.

### **SECONDARY FINDINGS:**

- Small amount of hyperechoic debris in the urinary bladder. These findings could be consistent with sandy debris or small stones. I recommend urinalysis and culture. Correlate with radiographs.
- Moderate gallbladder sludge. The significance of the aggregated gallbladder debris is unclear. This could represent an early mucocele, cholestasis, or may be secondary to fasting.
- Prominent, but not enlarged sublumbar lymph node. The prominent abdominal lymph nodes are most consistent with reactive lymphadenitis or lymphoid hyperplasia. Neoplastic infiltration is considered less likely.

## **INTERPRETATION OF THE FINDINGS & FURTHER RECOMMENDATIONS**

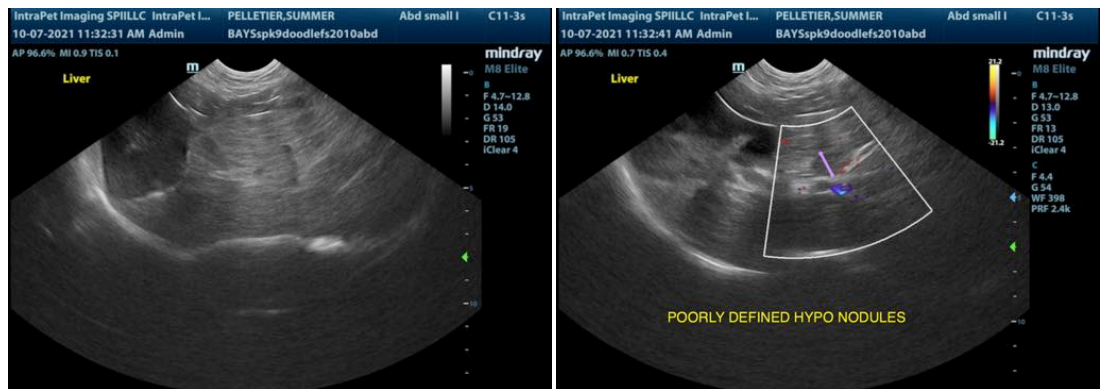
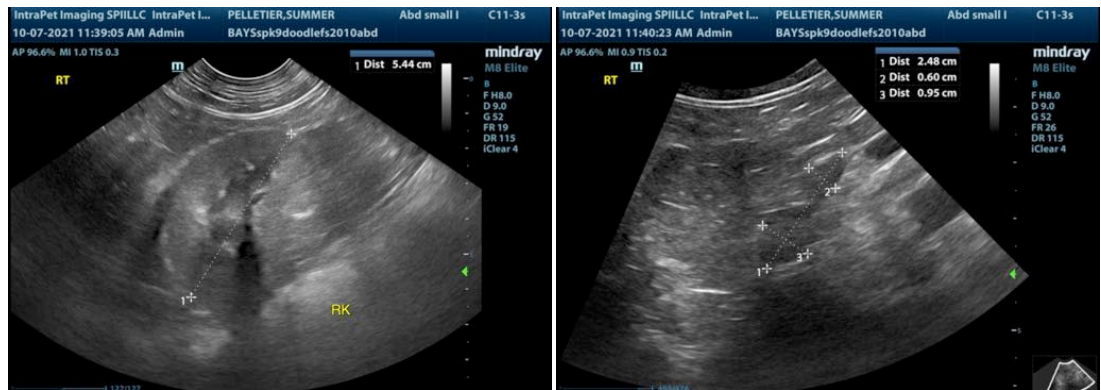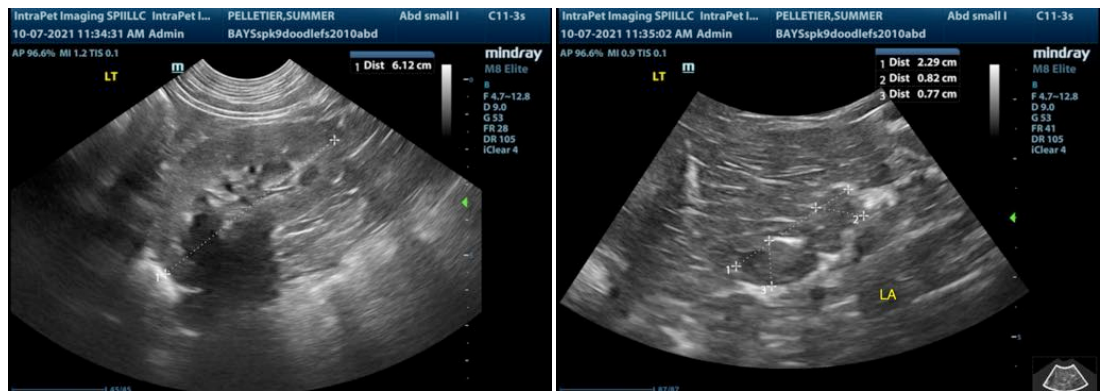
The findings on today's scan were relatively mild and non-specific. Correlate the liver findings with lab work. If there is no evidence of liver enzyme elevations this may be an age related change, but should continue to be monitored. A FNA of the liver can be considered.

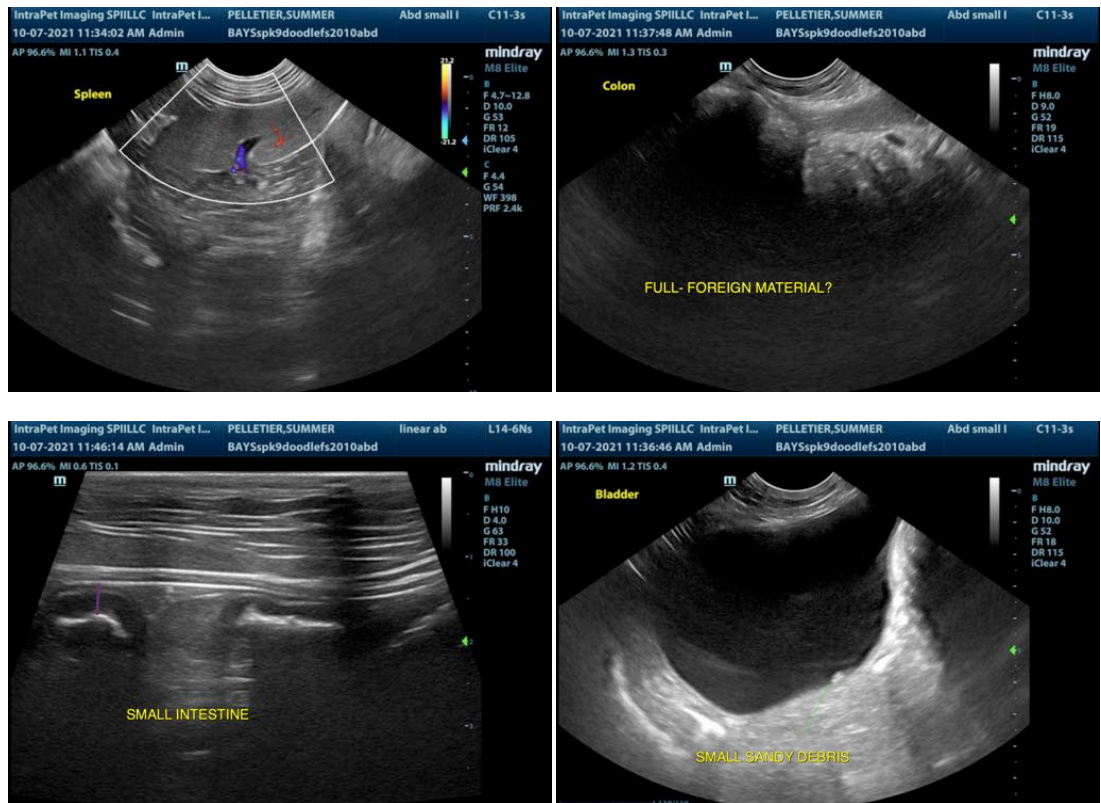
Based on the history of diarrhea and weight loss, absence of any major focal lesions and relatively normal lab work, GI disease seems most likely. There are many causes for diarrhea that cannot be definitively diagnosed

by ultrasound alone. Consider such differentials as GI parasitism, dietary indiscretion, bacterial dysbiosis, food allergy, IBD and less likely intestinal neoplasia.

In older patients with more chronic symptoms, I would most strongly consider food allergy, IBD, and intestinal neoplasia.

- Recommend diet trial with a novel protein/hydrolyzed prescription diet
- Recommend GI panel (PLI, TLI, cobalamin and folate) to further evaluate for pancreatic/small intestinal disease.
- Recommend a probiotic
- If symptoms are progressing consider obtaining GI biopsies





The information and recommendations provided are based on the images presented by the referring veterinarian. No evaluation can be communicated regarding pathology that was not visible in the image/video clips provided.

Thank you for this referral. If the clinical or image interpretation does not parallel your findings or if I can be of any further assistance please contact me.

Kathleen Sennello DVM,MS, Diplomate ACVIM (Small animal Internal Medicine)  
 kathleen.sennello@sonopath.com