



PATIENT

Nymeria Covert

SPECIES

Canine

BREED

Pit Bull

SEX

Spayed Female

AGE

5 Years

WEIGHT

26 kg

INTERPRETED BY

Kathleen Sennello DVM,
MS, Diplomate ACVIM
(Small Animal Internal
Medicine)

**IMAGING
PERFORMED BY**

Erin Wicks

HOSPITAL NAME

Shores VEC

REFERRING VET

Dr. Lupole

INVOICE

26146

DATE

10/7/21

PRESENTING CLINICAL SIGNS

Presented at our hospital 10/02/21 for limping and not eating. P has been limping for a couple weeks, and was given cerenia and carprofen at RDVM Thursday. P ate well that night and Friday, but did not eat well Saturday (yesterday). Last night, P was restless and whimpered all night. Today, RDVM stopped carprofen, but blood work would have to wait until Monday to go out. Per O, rads at RDVM showed normal stool in the bowels, but not much movement, and was Lyme neg. Pet was hospitalized here for several days dx with Addison's disease, is doing fairly well at home now but was in for a recheck with ascites, rec AUS.

Abnormal PE/Chem/CBC/UA Results: Blood work 10/02/21 – BUN 101.5, Creat 4.1, Phos 8.7, Ca 12.7, TP 7.9, Glob 5, Glu 51, ALT 156, pH 7.208, Na 131, K 6.6, Ca 1.53, BUN 92, Creat 4.28, Lym 5.96
Renal panel 10/06/21 – Ca 7.8, TP 5.1, Alb 2.3; EPOC – Na 138, Cl 105, Glu 142, HCT 32

ULTRASONOGRAPHIC EXAMINATION OF THE ABDOMEN

Urinary System

The urinary bladder is moderately distended with anechoic urine. The Bladder wall, trigone, ureteral papillae and visible urethra (to a depth of 2cm) appear normal with no evidence of wall thickening, mucosal irregularities, masses or cystic calculi.

The left kidney has a normal shape and size (6.15 cm). Overall echogenicity is normal with adequate corticomedullary distinction and a typical 1:3 cortex:medulla ratio. There is no evidence of perinephric inflammation or effusion. There is no evidence of pyelectasia, nephroliths, infarcts or hydroureter. Renal vasculature is normal.

The right kidney has a normal shape and size (6.97 cm). Overall echogenicity is normal with adequate corticomedullary distinction and a typical 1:3 cortex:medulla ratio. There is no evidence of perinephric inflammation or effusion. There is no evidence of pyelectasia, nephroliths, infarcts or hydroureter. Renal vasculature is normal.

Adrenal Glands

The region of left adrenal (Cranial to left renal artery) is unremarkable but the adrenal is not distinctly visualized. No evidence of a mass effect.

The region of the right adrenal (between right cranial kidney and vena cava) is unremarkable, but the adrenal is not distinctly visualized. No evidence of a mass effect.

Spleen

The spleen is subjectively normal in size, echotexture is homogenous, and the splenic capsule is smooth with no irregularities. The blood flow through the hilus and splenic parenchyma appears normal. No focal parenchymal abnormalities are visualized.

Liver

The liver is large in size, and normal in echogenicity with smooth peripheral margins. The parenchyma is heterogenous in echotexture with subtle, indistinct focal mottling. The visible portions of the vasculature and biliary tract appear normal. No focal nodules or cystic lesions are observed.

The gallbladder lumen is moderately distended. The wall of the gall bladder is not thickened and has a smooth mucosal surface. Luminal contents are primarily anechoic. The cystic and common bile ducts are normal/not visible.



PATIENT

Gastrointestinal

Nymeria Covert

The stomach contains minimal luminal contents. It measures at a normal thickness of <0.7cm with some variability due to the presence of rugal folds. The distinction of the gastric wall layers is adequate and there is no impression of reduced peristaltic activity. No masses or focal lesions were observed.

SPECIES

Canine

The visualized areas of duodenum, jejunum and ileum have a relatively uniform diameter with minimal fluid distension. Wall thickness is normal. Bowel loops follow a curvilinear path with distinct wall layering maintaining the typical 1:3 muscularis:mucosa layer ratio. The duodenum measured as normal (between 0.3-0.5cm in wall thickness) and the jejunum measured as normal (between 0.2-0.47cm.)

BREED

Pit Bull

Visualized peristalsis appears appropriate. There were no focal lesions consistent with obstruction or a mass effect observed.

SEX

Spayed Female

The ileocecal junction was visualized and exhibited normal intact wall layering and is subjectively of normal thickness. Sections of colon are visualized with formed fecal material and gas shadowing distally. There is no observed focal or generalized colon wall thickening or loss of layering.

Pancreas

AGE

5 Years

The pancreas is normal and isoechoic to surrounding mesentery. There is no evidence of nodules or cystic lesions. There is no evidence of regional mesenteric inflammation or fluid.

Free Abdomen

WEIGHT

26 kg

There is a large volume of anechoic free fluid. No mesenteric lymphadenopathy. The omentum appears generally hyperechoic and irregular, almost nodular in some areas.

ULTRASONOGRAPHIC FINDINGS

- Large volume anechoic free fluid
- Irregular, almost nodular omentum
- Large, heterogeneous liver

INTERPRETED BY

Kathleen Sennello DVM,
MS, Diplomate ACVIM
(Small Animal Internal
Medicine)

INTERPRETATION OF THE FINDINGS & FURTHER RECOMMENDATIONS

IMAGING PERFORMED BY

Erin Wicks

There is a large volume of free fluid present. Recommend sampling and fluid analysis cytology to get a better understanding of the nature of the effusion. A focal large mass effect was not observed, but there is a lot of irregular omentum, which could represent carcinomatosis or just general inflammatory tissue. Reported albumin is not low enough to likely be the cause of the effusion, but it is unclear how current that is. Consider if urine production is adequate. Recommend 3-view thoracic radiographs to look for effusion there, evidence of pericardial effusion or heart disease, etc.

HOSPITAL NAME

Shores VEC

The liver does appear somewhat heterogeneous and large. Severe vascular congestion is not noted, but this can be subjective. Findings could be consistent with infiltrative disease or congestion. If a cause for the effusion is not readily apparent based on fluid analysis and thoracic imaging, consider a CT scan of the thorax and abdomen to further evaluate for vascular occlusion, small masses, etc.

REFERRING VET

Dr. Lupole

INVOICE

26146

DATE

10/7/21



PATIENT

Nymeria Covert

SPECIES

Canine

BREED

Pit Bull

SEX

Spayed Female

AGE

5 Years

WEIGHT

26 kg

INTERPRETED BY

Kathleen Sennello DVM,
MS, Diplomate ACVIM
(Small Animal Internal
Medicine)

**IMAGING
PERFORMED BY**

Erin Wicks

HOSPITAL NAME

Shores VEC

REFERRING VET

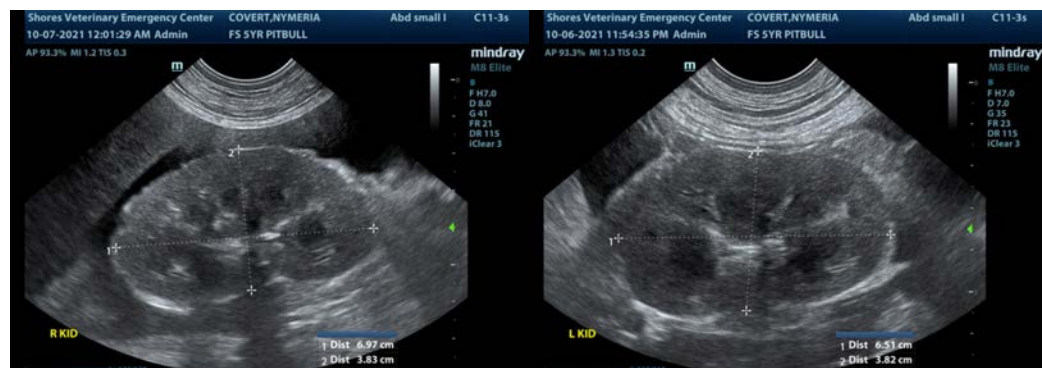
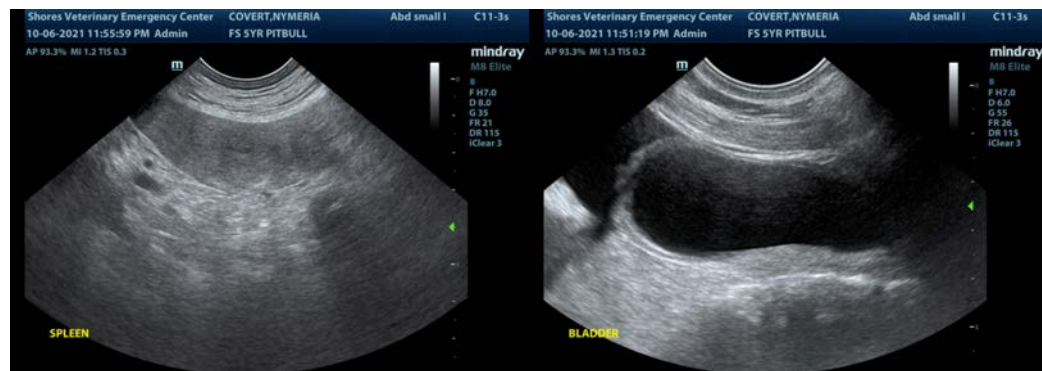
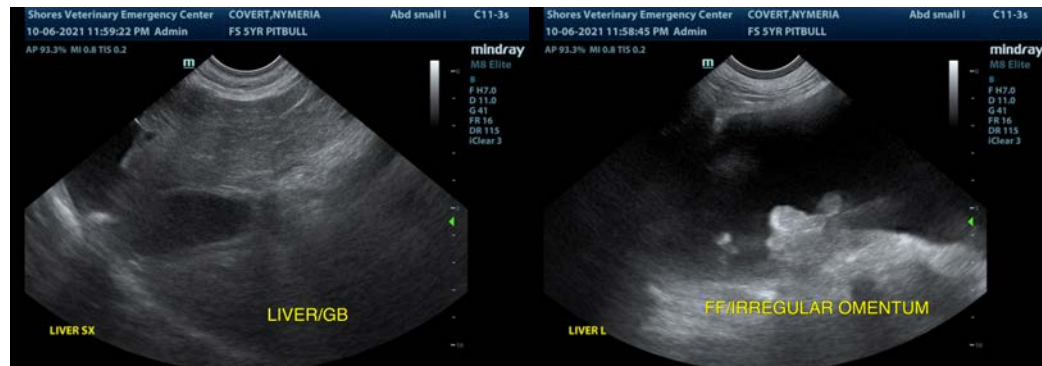Dr. Lupole

INVOICE

26146

DATE

10/7/21



The information and recommendations provided are based on the images presented by the referring veterinarian. No evaluation can be communicated regarding pathology that was not visible in the image/video clips provided.

Thank you for this referral. If the clinical or image interpretation does not parallel your findings or if I can be of any further assistance please contact me.

Kathleen Sennello DVM,MS, Diplomate ACVIM (Small animal Internal Medicine)
kathleen.sennello@sonopath.com