

**DATE**

10/7/21

PRESENTING CLINICAL SIGNS

History: Weight loss, acute vomiting and diarrhea, anorexia.

Current Medications: Mirtazapine 3.5mg given yesterday

Lab Results: Attached.

PATIENT

Radiographs: Dilated colon, gas filled SI

Date of Previous IntraPet Ultrasound: No previous.

Sedation: IM Buprenex/Midazolam. Still biting cat gloves- dysphoric.

Stat Report: Not requested.

Mr Biggles Lopez

SPECIES

Feline

ULTRASONOGRAPHIC EXAMINATION OF THE ABDOMEN**Urinary System**

The urinary bladder is moderately distended with echogenic urine. The Bladder wall, trigone, ureteral papillae and visible urethra (to a depth of 2cm) appear normal with no evidence of wall thickening, mucosal irregularities, masses or cystic calculi.

BREED

Domestic Shorthair

The left kidney has a normal shape and size (3.69 cm). Overall echogenicity is slightly hyperechoic with poor corticomedullary distinction and a typical 1:3 cortex:medulla ratio. There is no evidence of perinephric inflammation or effusion. There is no evidence of pyelectasia, nephroliths, infarcts or hydroureter. Renal vasculature is normal.

SEX

Neutered male

The right kidney has a normal shape and size (3.87 cm). Overall echogenicity is slightly hyperechoic with poor corticomedullary distinction and a typical 1:3 cortex:medulla ratio. There is no evidence of perinephric inflammation or effusion. There is no evidence of pyelectasia, nephroliths, infarcts or hydroureter. Renal vasculature is normal.

AGE

2009

WEIGHT

6.6 lbs

Adrenal Glands

The left adrenal gland is normal in size. It is observed in its normal position cranial to the left renal artery. It is normal in appearance (uniformly hypoechoic) and shape with no evidence of a mass effect.

The right adrenal gland is normal in size measuring 0.44 cm at the caudal pole. It is observed in its normal position between the cranial aspect of the right kidney and the caudal vena cava. It is normal in appearance (uniformly hypoechoic) and shape with no evidence of a mass effect.

INTERPRETED BY

Kathleen Sennello
DVM, MS, Diplomate
ACVIM (Small Animal
Internal Medicine)

HOSPITAL NAME

Bayside AMC

Spleen

The spleen is subjectively normal in size, echotexture is homogenous, and the splenic capsule is smooth with no irregularities. The blood flow through the hilus and splenic parenchyma appears normal. No focal parenchymal abnormalities are visualized.

REFERRING VET

Dr. Bray

Liver

The liver is subjectively normal in size, and echogenicity with smooth peripheral margins. The parenchyma is homogenous echotexture. The visible portions of the vasculature and biliary tract appear normal. There is a small, 0.44 cm hyperechoic nodule visualized. The gallbladder lumen is moderately distended. The wall of the gallbladder is not thickened and has a smooth mucosal surface. Luminal contents are primarily anechoic. The cystic and common bile ducts are normal/not visible.

INVOICE

92241

Gastrointestinal

The stomach contains minimal luminal contents. It measures at a normal thickness of <0.36cm with some variability due to the presence of rugal folds. The distinction of the gastric wall layers is adequate and there is no impression of reduced peristaltic activity. No masses or focal lesions were observed.

The visualized areas of duodenum, jejunum and ileum have a uniform diameter with minimal fluid distension. Wall thickness is normal to slightly increased. Bowel loops follow a typical curvilinear path with distinct wall layering, but some areas display a prominent muscularis layer which does not display the typical 1:3 muscularis:mucosa layer ratio. The jejunum measured 0.18 cm. Visualized peristalsis appears appropriate. There were no focal lesions consistent with obstruction or a mass effect observed.

The ileocecal junction was visualized and exhibited normal intact wall layering and is subjectively of normal thickness. Sections of colon are visualized with formed fecal material and gas shadowing distally. There is no observed focal or generalized colon wall thickening or loss of layering.

Pancreas

The pancreas is prominent and hypoechoic as compared to the surrounding isoechoic mesentery. There is no evidence of nodules or cystic lesions. There is no evidence of regional mesenteric inflammation or fluid.

Free Abdomen

Evaluation of the peritoneal cavity did not reveal any evidence of effusion. There is a mild mesenteric lymphadenomegaly present particularly at the root of the mesentery where lymph nodes are measured 0.25 cm, 0.34 cm, 0.46 cm and 0.33 cm. There was no evidence of a caudal aortic thrombus at the bifurcation. The omentum is of normal uniform echogenicity.

ULTRASONOGRAPHIC FINDINGS

PRIMARY FINDINGS:

- Prominent muscularis layer of the small intestine. The small intestinal wall changes are most consistent with an inflammatory process (i.e., inflammatory bowel disease) with a low possibility of emerging lymphoma.
- Mild mesenteric lymphadenopathy. The prominent abdominal lymph nodes are most consistent with reactive lymphadenitis or lymphoid hyperplasia. Neoplastic infiltration is considered less likely.
- Decreased corticomedullary distinction of both kidneys. Mild loss of corticomedullary distinction in both kidneys could be consistent with chronic degenerative disease or interstitial nephrosis.

SECONDARY FINDINGS:

- Echogenic debris in the urinary bladder. The echogenic debris in the bladder lumen could be consistent with cells, crystals, and/or mucus. Recommend urinalysis and culture.
- Small liver nodule visualized. Hyperechoic liver nodules tend to be less likely neoplastic, but this is not definitive. I recommend to continue monitoring.

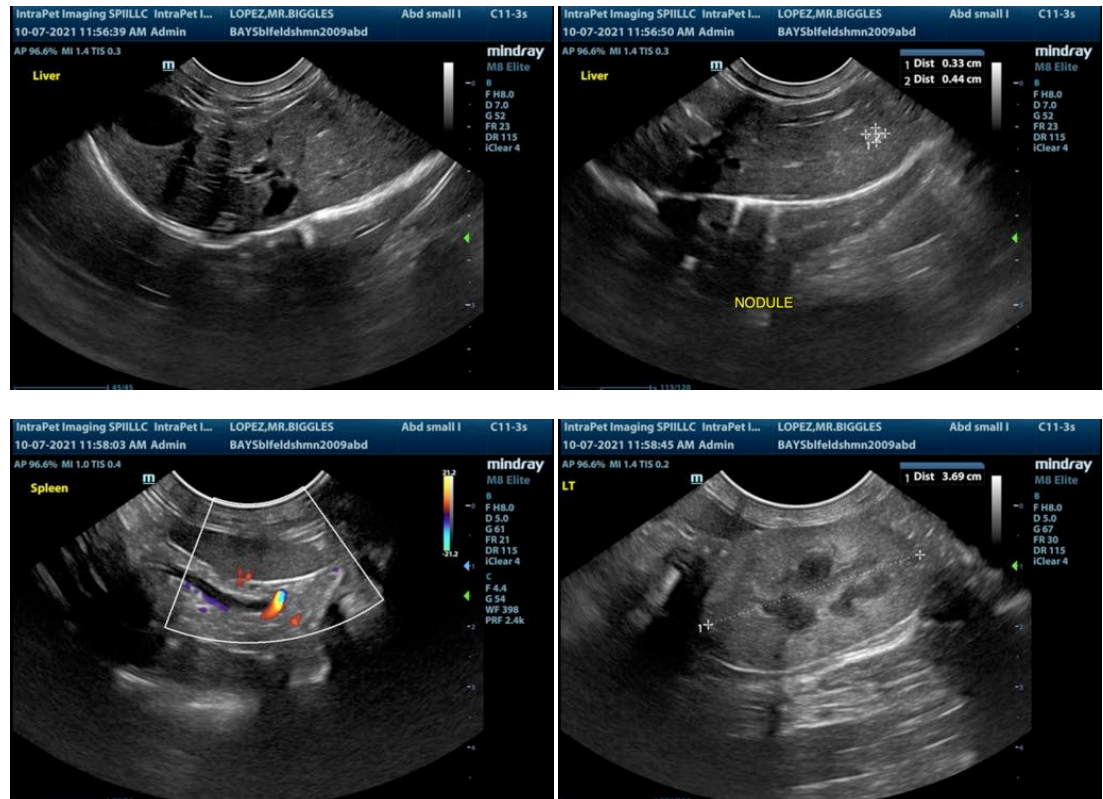
INTERPRETATION OF THE FINDINGS & FURTHER RECOMMENDATIONS

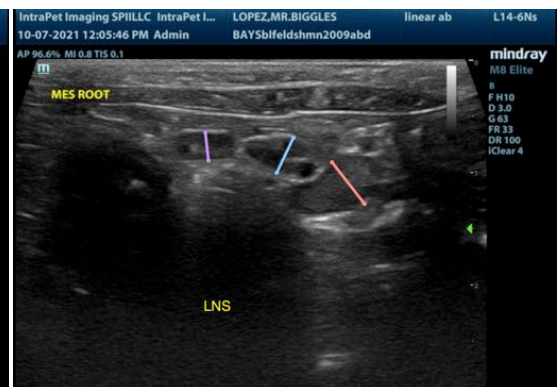
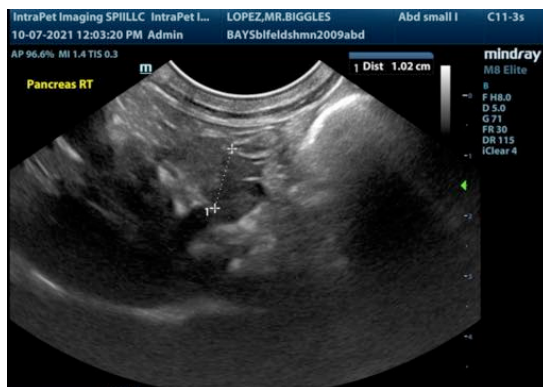
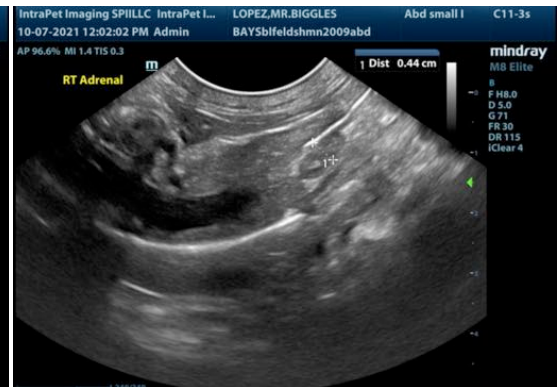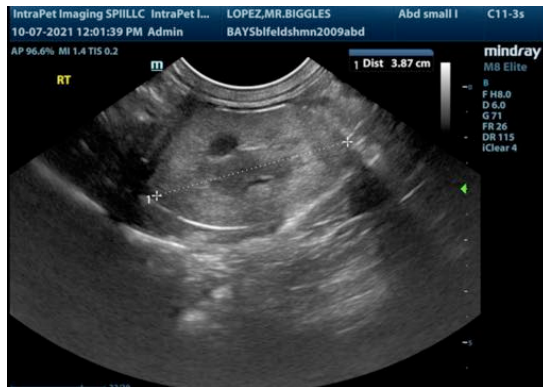
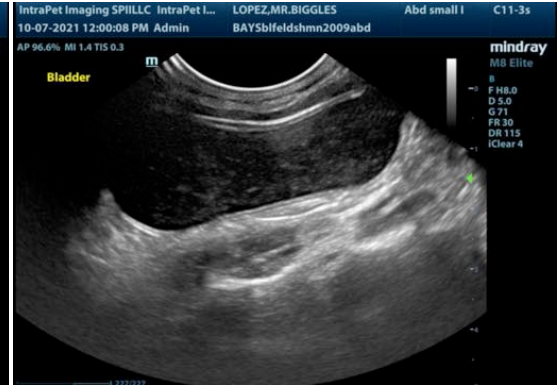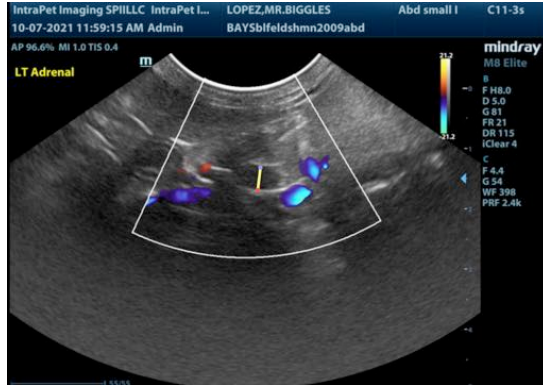The ultrasound changes observed were relatively mild, but there is a lymphadenopathy present and the muscularis layer to small intestine is prominent. This can be a normal finding in older cats, but in conjunction

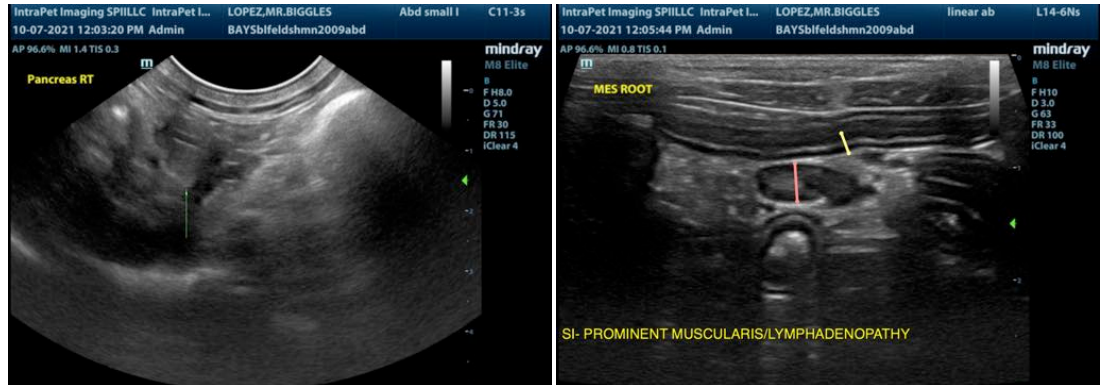
with the current GI signs I suspect an underlying enteropathy. No focal lesions were observed in the gastrointestinal tract. If metabolic causes for vomiting and diarrhea have been ruled out normal lab work, normal T4, etc, and consider primary GI causes such as GI parasitism, dietary indiscretion, dysbiosis, food allergy, IBD and less likely intestinal neoplasia.

In older patients with more chronic symptoms, I would most strongly consider food allergy, IBD, and intestinal neoplasia.

- Recommend diet trial with a novel protein/hydrolyzed prescription diet
- Recommend GI panel for evaluation of PLI, TLI, cobalamin and folate to evaluate for evidence of pancreatic and small intestinal disease.
- Recommend a probiotic
- If symptoms are progressing consider obtaining GI biopsies







The information and recommendations provided are based on the images presented by the referring veterinarian. No evaluation can be communicated regarding pathology that was not visible in the image/video clips provided.

Thank you for this referral. If the clinical or image interpretation does not parallel your findings or if I can be of any further assistance please contact me.

Kathleen Sennello DVM,MS, Diplomate ACVIM (Small animal Internal Medicine)
kathleen.sennello@sonopath.com