



**PATIENT**

Lilo Wright

**PRESENTING CLINICAL SIGNS**

chronic cystitis, urinating blood. On baytril and onsiior  
Abnormal PE/Chem/CBC/UA Results: 9/13/21 UA: bacteria, blood. post convenia culture showed no growth, then started baytril. USPG 1.050

**SPECIES**

Feline

**ULTRASONOGRAPHIC EXAMINATION OF THE ABDOMEN**

**Urinary System**

**BREED**

DSH

The urinary bladder is moderately distended with primarily suspended echogenic debris present. The Bladder wall, trigone, and ureteral papillae appear normal with no evidence of wall thickening, mucosal irregularities, masses or cystic calculi. Approximately 2.0 cm deep within the proximal urethra, just before the pelvic shadow, there is a 0.25 cm hyperechoic structure with a weak shadow. This is most consistent with mineralized debris and a possible urethral stone. A grouping of sandy debris is possible as well.

**SEX**

Spayed Female

The left kidney has a normal shape and size (4.1 cm). Overall echogenicity is normal with adequate corticomedullary distinction and a typical 1:3 cortex:medulla ratio. There is no evidence of perinephric inflammation or effusion. There is no evidence of pyelectasia, nephroliths, infarcts or hydroureter. Renal vasculature is normal.

**AGE**

3.5 Years

The right kidney has a normal shape and size (4.44 cm). Overall echogenicity is normal with adequate corticomedullary distinction and a typical 1:3 cortex:medulla ratio. There is no evidence of perinephric inflammation or effusion. There is no evidence of pyelectasia, nephroliths, infarcts or hydroureter. Renal vasculature is normal.

**WEIGHT**

12.3 Pounds

**Adrenal Glands**

**INTERPRETED BY**

Kathleen Sennello DVM,  
MS, Diplomate ACVIM  
(Small Animal Internal  
Medicine)

The left adrenal gland is normal in size measuring 0.30 cm at the caudal pole. It is observed in its normal position cranial to the left renal artery. It is normal in appearance (uniformly hypoechoic) and shape with no evidence of a mass effect.

**IMAGING**

**PERFORMED BY**

Diane McFadden

The right adrenal gland is normal in size measuring 0.38 cm at the caudal pole. It is observed in its normal position between the cranial aspect of the right kidney and the caudal vena cava. It is normal in appearance (uniformly hypoechoic) and shape with no evidence of a mass effect.

**HOSPITAL NAME**

Wantage Vet Hospital

**Spleen**

The spleen is subjectively normal in size, echotexture is homogenous, and the splenic capsule is smooth with no irregularities. The blood flow through the hilus and splenic parenchyma appears normal. No focal parenchymal abnormalities are visualized.

**Liver**

**REFERRING VET**

Dr. Bullock

The liver is subjectively normal in size, and echogenicity with smooth peripheral margins. The parenchyma is homogenous echotexture. The visible portions of the vasculature and biliary tract appear normal. No focal nodules or cystic lesions are observed.

**INVOICE**

26143

The gallbladder lumen is moderately distended. The wall of the gall bladder is not thickened and has a smooth mucosal surface. Luminal contents are primarily anechoic. The cystic and common bile ducts are normal/not visible.

**DATE**

10/7/21



**PATIENT**

Lilo Wright

**Gastrointestinal**

The stomach contains minimal luminal contents. It measures at a normal thickness of <0.36cm with some variability due to the presence of rugal folds. The distinction of the gastric wall layers is adequate and there is no impression of reduced peristaltic activity. No masses or focal lesions were observed.

**SPECIES**

Feline

The visualized areas of duodenum, jejunum and ileum have a relatively uniform diameter with minimal fluid distension. Wall thickness is normal. Bowel loops follow a curvilinear path with distinct wall layering maintaining the typical 1:3 muscularis:mucosa layer ratio. The duodenum measured as normal (between 0.13-0.38cm in wall thickness) and the jejunum measured as normal (between 0.15-0.36cm.) Visualized peristalsis appears appropriate. There were no focal lesions consistent with obstruction or a mass effect observed.

**BREED**

DSH

**SEX**

Spayed Female

The ileocecal junction was visualized and exhibited normal intact wall layering and is subjectively of normal thickness. Sections of colon are visualized with formed fecal material and gas shadowing distally. There is no observed focal or generalized colon wall thickening or loss of layering.

**Pancreas**

**AGE**

3.5 Years

The pancreas is normal and isoechoic to surrounding mesentery. There is no evidence of nodules or cystic lesions. There is no evidence of regional mesenteric inflammation or fluid.

**Free Abdomen**

**WEIGHT**

12.3 Pounds

Evaluation of the peritoneal cavity did not reveal any evidence of effusion, or subjective lymphadenomegaly. The Medial iliac nodes appear normal and there was no evidence of a caudal aortic thrombus at the bifurcation. The omentum is of normal uniform echogenicity.

**ULTRASONOGRAPHIC FINDINGS**

- Hyperechoic, lightly shadowing structure within the intrapelvic urethra – This is suspicious for a urethral stone

**INTERPRETATION OF THE FINDINGS & FURTHER RECOMMENDATIONS**

There is a small hyperechoic structure within the urethra. This is most likely a small stone or a small pile of sandy debris. Occasionally, non-mineralized debris can appear somewhat hyperechoic. The best option would be to consider sedation and catheterization, and possible retropulsion of the stone back into the urinary bladder. Prior to this, consider radiographs with detail to try to visualize that area. Additionally, you might be able to palpate it on rectal exam. Consider ultrasound evaluation or radiographs to see if the stone is able to be retropulsed back up into the urinary bladder. If a catheter passes with no problem, and the stone doesn't move, this could mean it is embedded in the urethra, or that it was just a pile of sandy debris and not anything significant enough to go to surgery for. Recommend urinalysis and culture.

**INTERPRETED BY**

Kathleen Sennello DVM,  
MS, Diplomate ACVIM  
(Small Animal Internal  
Medicine)

**IMAGING PERFORMED BY**

Diane McFadden

**HOSPITAL NAME**

Wantage Vet Hospital

**REFERRING VET**

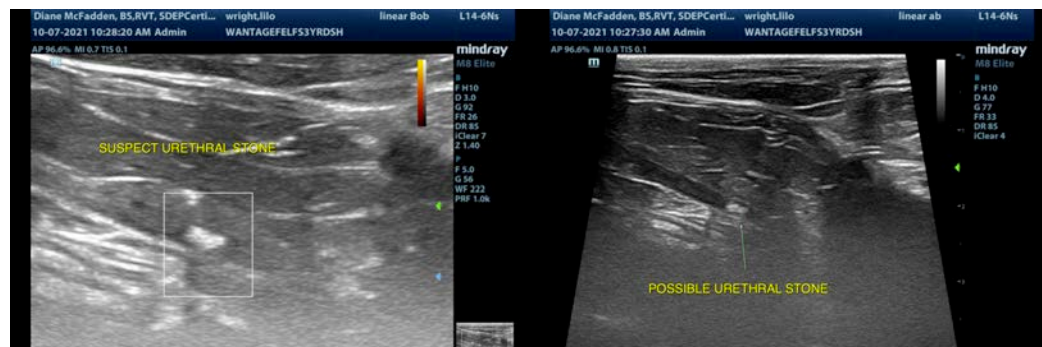
Dr. Bullock

**INVOICE**

26143

**DATE**

10/7/21





**PATIENT**

Lilo Wright

**SPECIES**

Feline

**BREED**

DSH

**SEX**

Spayed Female

**AGE**

3.5 Years

**WEIGHT**

12.3 Pounds

**INTERPRETED BY**

Kathleen Sennello DVM,  
MS, Diplomate ACVIM  
(Small Animal Internal  
Medicine)

**IMAGING  
PERFORMED BY**

Diane McFadden

**HOSPITAL NAME**

Wantage Vet Hospital

**REFERRING VET**

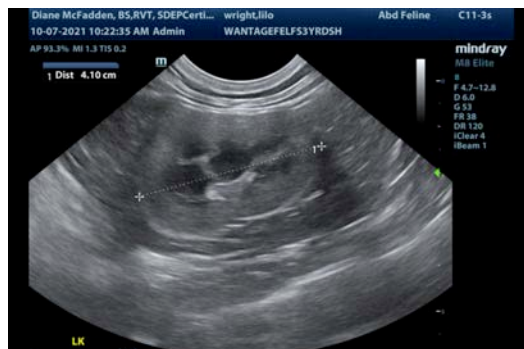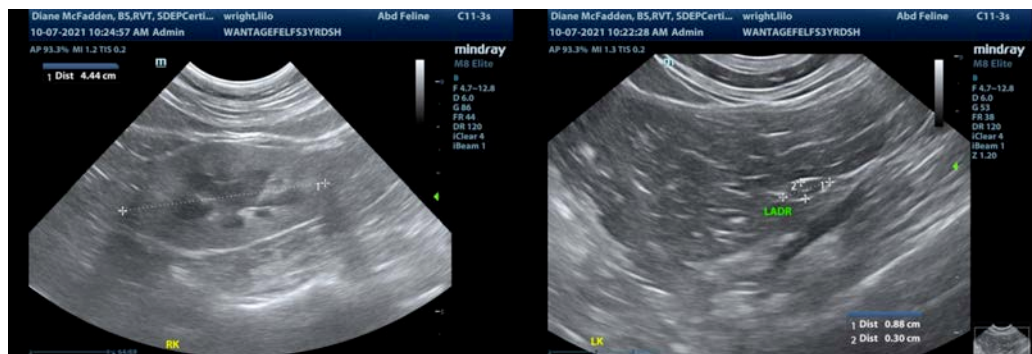
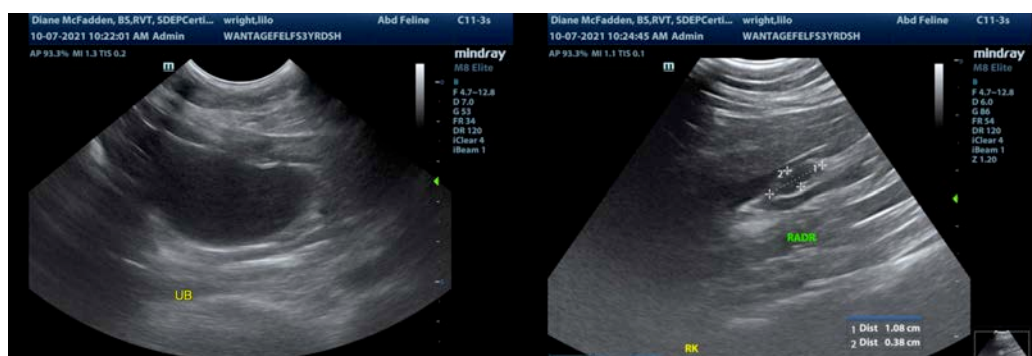
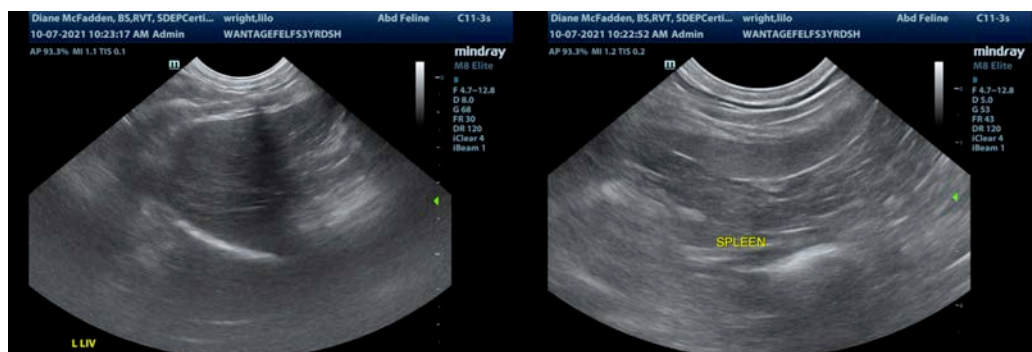
Dr. Bullock

**INVOICE**

26143

**DATE**

10/7/21





**PATIENT**

Lilo Wright

The information and recommendations provided are based on the images presented by the referring veterinarian. No evaluation can be communicated regarding pathology that was not visible in the image/video clips provided.

**SPECIES**

Feline

Thank you for this referral. If the clinical or image interpretation does not parallel your findings or if I can be of any further assistance please contact me.

**BREED**

DSH

Kathleen Sennello DVM,MS, Diplomate ACVIM (Small animal Internal Medicine)  
kathleen.sennello@sonopath.com

**SEX**

Spayed Female

**AGE**

3.5 Years

**WEIGHT**

12.3 Pounds

**INTERPRETED BY**

Kathleen Sennello DVM,  
MS, Diplomate ACVIM  
(Small Animal Internal  
Medicine)

**IMAGING  
PERFORMED BY**

Diane McFadden

**HOSPITAL NAME**

Wantage Vet Hospital

**REFERRING VET**

Dr. Bullock

**INVOICE**

26143

**DATE**

10/7/21